

AN ANATOMICAL STUDY ON HILAR VARIATIONS AND MORPHOMETRIC DIMENSIONS OF HUMAN KIDNEYS

Dr. Deepa Devadas¹, Dr. Urmila Sinha², Dr. G N Trivedi³

¹Tutor, Department of Anatomy, Andaman and Nicobar Islands Institute of Medical Sciences, India.

²Assistant Professor, Department of Anatomy, Andaman and Nicobar Islands Institute of Medical Sciences, India

³Professor, Department of Anatomy, Andaman and Nicobar Islands Institute of Medical Sciences, India.

Article Info: Received 18 August 2019; Accepted 16 September. 2019

DOI: <https://doi.org/10.32553/ijmbs.v3i9.543>

Corresponding author: Dr. Urmila Sinha

Conflict of interest: No conflict of interest.

Abstract

Variations in renal hilar arrangement patterns and morphometric dimensions are clinically relevant in this age of advancing modern medicine and minimally invasive surgery. The purpose of the present study is to record variations in renal hilar arrangement patterns and assess renal dimensions of length, width and thickness respectively. Hilar regions of fifty isolated embalmed kidneys were carefully dissected and variations observed were photographed and documented. Renal dimensions were measured with digital calipers and values obtained were tabulated and analysed. Normal anteroposterior hilar arrangement pattern was observed in 72% cases. Anterior and posterior divisions of renal artery were observed in 24% cases with anterior division being the most anteriorly placed structure in 14% cases. The renal pelvis was situated between the divisions of the renal artery in 8% cases. Prehilar segmental branches anterior to renal vein were observed in 4% cases. Other variations seen included extrahilar branches (4%), superior polar artery arising from anterior division of renal artery, prehilar tributaries of renal vein and an additional renal artery in 1 case each. The mean renal length was 9.35 \pm 0.98 cm for right and 9.25 \pm 1.25 cm for left kidneys, mean renal width 4.93 \pm 0.65 cm for right and 4.95 \pm 0.5 cm for left kidneys and mean renal thickness 3.77 \pm 0.7 cm for right and 3.86 \pm 0.53 cm for left kidneys respectively. No statistically significant difference was observed in the mean values between right and left sides. The clinical implications of these findings have been discussed. The findings of this study may enhance the existing literature and contribute additional information for improving treatment outcomes during clinical and surgical interventions.

Keywords: Variation, Hilum, Kidneys, Morphometry, Arrangement pattern, dimensions

Introduction:

In this current era of rapidly advancing modern medicine, an in-depth anatomical understanding of the human body is an essential prerequisite for successfully performing medical, radiological and surgical procedures. The kidneys are paired retroperitoneal organs situated in the posterior abdominal wall, on either side of the vertebral column. In addition to excretion, they also play a role in red cell formation as well as calcium and mineral metabolism through the release of erythropoietin and renin respectively. In each kidney, a deep vertical fissure in the medial border opens anteromedially as the hilum, which is bounded by anterior and posterior lips and contains the renal vessels and nerves, and the renal pelvis.¹ The relative positions of

the main hilar structures are the renal vein (anterior), the renal artery (intermediate) and the pelvis of the kidney (posterior).¹

Anatomical knowledge of the distribution of renal hilar structures is of crucial importance for urological surgical procedures in which hilar vessel clamping is necessary, either temporally or definitively, such as in conventional and laparoscopic nephrectomy, anastrophic nephrolithotomy and renal transplantation, as well as in interventions in which a pyelic incision is needed for the removal of calculi, such as conventional and laparoscopic pyelolithotomy.² With increasing incidence of small incidentally diagnosed renal tumours, laparoscopic partial nephrectomy (LPN) has emerged as an attractive minimally invasive treatment option³ with

shorter ischemia times, a lower complication rate, and equivalent long-term oncologic and renal functional outcomes, yet with decreased patient morbidity.⁴ During LPN, clamping of individual structures at the hilum is preferred rather than en-bloc clamping.⁵ Recent studies have demonstrated the need for careful hilar dissection with appropriate techniques of clamping renal vessels to prevent surgical complications and reduce post operative morbidity.^{6,7} A precise knowledge of normal as well as variant anatomical arrangement patterns at the renal hilum is vital for the achievement of successful surgical outcomes with reduced complications and better patient recovery.

Morphometric changes in kidney dimensions may be associated with atherosclerotic renal disease, arterial hypertension, atherosclerotic renovascular disease or diabetes mellitus.⁸ Furthermore, according to certain studies, it is possible to use renal size to predict the renal function in healthy individuals or patients with chronic kidney disease.⁹ In this regard, the present study also attempts to determine anatomical dimensions of length, width and thickness of the kidneys which may provide added insight into currently available literature.

MATERIALS AND METHODS

The present observational study was done in the Department of Anatomy at Andaman & Nicobar Islands Institute of Medical Sciences from 2018-2019. A total of 50 isolated (26 right and 24 left) embalmed cadaveric kidneys were obtained. Morphologically abnormal kidneys were excluded from this study. The prehilum and hilar regions of the kidneys were studied after careful dissection. The anteroposterior arrangement of hilar structures was studied 0.5 cm from the anterior lip of the hilum. Variations encountered in hilar anatomy were photographed and documented. The kidneys were also morphometrically assessed for maximum length, width and thickness using digital calipers and values obtained were recorded. The renal dimensions were compared with respect to right and left kidneys by applying Independent t test with p value set at <0.05 in SPSS software version 21 for statistical analysis.

RESULTS

We observed the classically described hilar anteroposterior arrangement of renal vein, renal artery and pelvis in 72% (36/50) cases. Variant arrangement patterns of the hilar structures were

recorded in 28% (14/50) cases. The various hilar arrangement patterns observed in the present study are depicted in table 1. The renal artery divided into anterior and posterior divisions in 24% cases, with the anterior division being the most anteriorly placed structure in 14% (7/50) cases [Fig.2]. In 8% (4 cases), the renal pelvis was found to lie between the divisions of the renal artery with the renal vein being the anterior most structure at the hilum [Fig 3]. In 1 case, prehilum division of the renal vein into 2 anterior and 2 posterior tributaries were observed [Fig 4]. In addition to the above mentioned arrangement patterns, we observed multiple prehilum segmental branches of renal artery running anterior to the renal vein with crowding of the renal hilum in 4% (2) cases [Fig 5]. A total of 3 extrahilar branches [Fig 2 & 6], including an extrahilar superior polar branch of renal artery were observed in 4% (2) cases. The superior polar artery arise from the anterior division of renal artery [Fig 6]. The remaining extrahilar branches arise from the renal artery [Fig 2] as well as from its anterior division [Fig 6]. A single additional renal artery was found in 1 case, arising from the abdominal aorta and supplying the right kidney just below the hilum [Fig 6].

The length of the right kidneys ranged from 7.5 to 12 cm and those of the left kidneys from 6.5 to 13 cm. The mean renal length measured 9.35 +/- 0.98 cm for right and 9.25 +/- 1.25 cm for left kidneys. Similarly, the width of right kidneys varied from 4 to 6.8 cm, with mean renal width being 4.93 +/- 0.65 cm. The width of left kidneys ranged from 4.2 to 6.5 cm and the mean renal width was 4.95 +/- 0.5 cm. Mean renal thickness was 3.77 +/- 0.7 cm for right and 3.86 +/- 0.53 cm for left kidneys respectively. Renal Thickness varied from 2 to 5 cm for right and 3 to 5 cm for left kidneys respectively. No statistically significant difference was observed in the mean values between right and left sides.

Table 1: Showing arrangement patterns of structures in renal hilum with percentage incidence

HILAR ARRANGEMENT PATTERN	Percentage Incidence (n=50)
RV-RA-PL	72(36/50)
AD-RV-PD-PL	14(7/50)
RV-AD-PL-PD	8(4/50)
AT-AD-PL-PD-PT	2(1/50)




Figure 1: showing AD-RV-PD-PL anteroposterior arrangement at renal hilum with extrahilar branch arising from renal artery

RA: Renal artery; RV: Renal vein; PL: Renal pelvis; AD: Anterior division; PD: Posterior division; EHB: Extrahilar branch

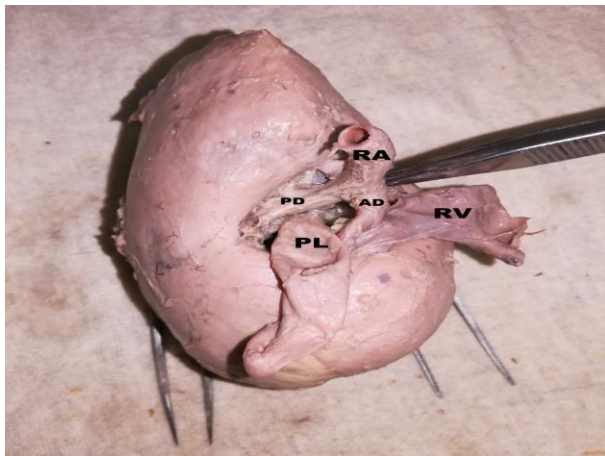


Figure 2: showing RV-AD-PL-P Danteroposterior arrangement at renal hilum

RA: Renal artery; RV: Renal vein; PL: Renal pelvis; AD: Anterior division of renal artery; PD: Posterior division of renal artery

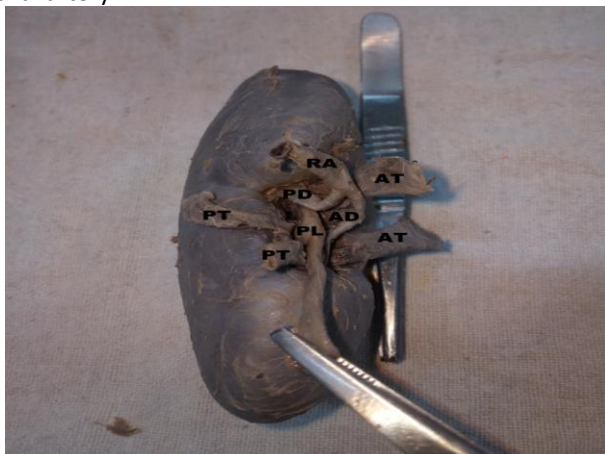

Figure 3: showing AT-AD-PL-PD-PT anteroposterior arrangement at renal hilum

RA: Renal artery; AD: Anterior division of renal artery; PD: Posterior division of renal artery; AT: Anterior tributaries of renal vein; PT: Posterior tributaries of renal vein; PL: Renal pelvis

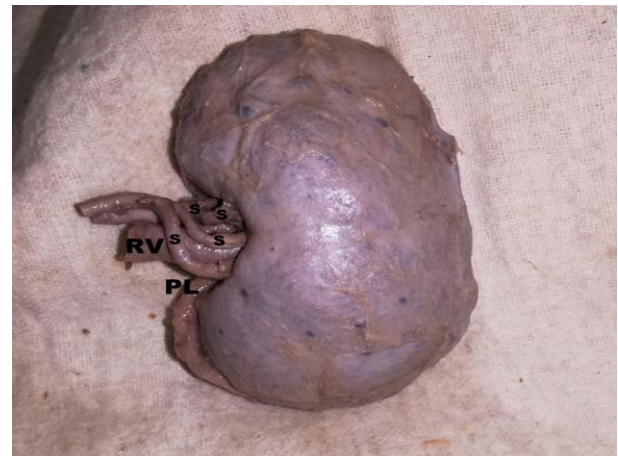

Figure 4: showing multiple segmental arteries with crowding at renal hilum

RV: Renal vein; PL: Renal pelvis; S: Segmental branches of renal artery

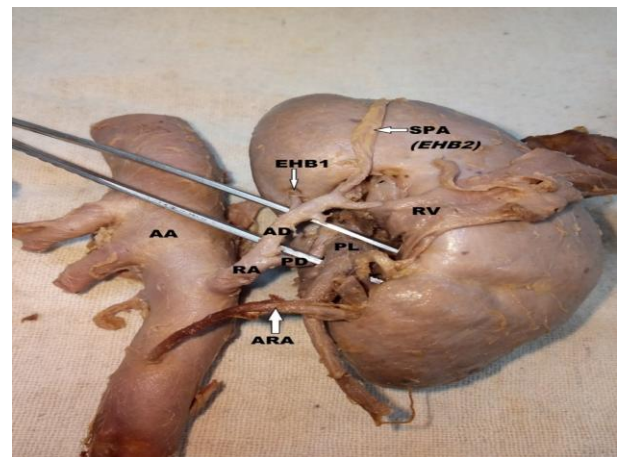


Figure 5: showing presence of extrahilar branches and superior polar artery with additional renal artery

RV: Renal Vein; RA: Renal artery; AD: Anterior division of renal artery; PD: Posterior division of renal artery; PL: Renal pelvis; AA: Abdominal aorta; EHB: Extrahilar branches; SPA: Superior polar artery; ARA: Additional renal artery

DISCUSSION

In this work, we have attempted to morphometrically assess renal dimensions and study different variations that may be encountered in the topographic arrangement of structures at the renal hilum, in consideration of its clinical and surgical importance. In our study, the conventional textbook described anteroposterior arrangement of renal vein-artery-pelvis at the hilum was observed in 72% cases.

This is comparable with the findings of Joao² et al who observed this arrangement in 83% cases. In contrast, Trivedi et al¹⁰ observed that hilar anteroposterior arrangement was not according to normal textbook description in majority (73%) cases,

similar to Kumar et al¹¹ who also reports a relatively lesser incidence of normal arrangement pattern at 45.8% respectively. A comparison of our findings with those of previous studies has been summarised in table 7.

Table 7: comparison of hilar arrangement patterns of present study with previous studies.

Hilar arrangement pattern	Trivedi et al ¹⁰	Kumar et al ¹¹	Jadhav et al ¹²	Divya et al ¹³	Present study
RV-RA-PL	19%	45.8%	22.8%	32%	72%
AD-RV-PD-PL	23%	2.1%	5.26%	14%	14%
RV-AD-PL-PD	20%	8.3%	7.89%	12%	8%
AT-AD-PL-PD-PT	-	2.1%	-	-	2%

Prehilar segmental branches of the renal artery have been described by various authors^{2,11,14,15} in the past and were observed in 4% cases of the present study. Segmental branches of the renal artery crowding the hilum may pose challenges during surgical hilar dissection as individual segmental arterial clamping though anatomically possible, is difficult to perform because of the high individual morphological variability.¹⁴ Presence of multiple prehilar segmental branches increases risk of hemorrhage during renal transplantation, segmental ischemia and postoperative hypertension due to loss of parenchyma.¹⁵ Trivedi¹⁰ et al and Kumar¹¹ et al observed that variant arrangement of renal venous patterns at the hilum are more frequently left sided which might be due to the embryological formation of left renal vein from multiple anastomotic channels. This coincides with our study where we observed prehilar division of the renal vein into two anterior and two posterior tributaries in a left kidney. It has been suggested that anomalous arrangement of vessels in the renal hilum may occur due to rotational defects of the kidney¹⁶ and may be associated with ureteropelvic obstruction.¹⁷

Extrahilar superior polar branches of renal artery have been observed in 14.3% cases by Sampaio,¹⁸ who used the term extrahilar to describe branches of renal artery with an extra-hilar penetration. In the present study, similar extrahilar branches were observed in 4% cases with an extrahilar superior polar artery arising from the anterior division of the renal artery. The superior polar artery has been found to arise from main renal artery in 5.4% cases by Budhiraja¹⁹ and in 17.2 % cases on the right side and 13.5 % cases on the left side by Saldarriaga²⁰. Rao²¹ et al in their study have considered extrahilar branching of renal

arteries to be a normal pattern where the arteries divide to go to the respective segments. Similar observations have been made by Budhiraja¹⁵ et al who observed prehilar multiple segmental branches in 11.66% cases. The branching pattern also depends on the form of the hilum with extrahilar branching often associated with a large hilum.¹⁴

Additional renal arteries have been assigned a wide range of nomenclature such as supernumerary, aberrant, accessory, supplementary or multiple renal arteries by various authors.²² As no definitive criteria has been established to name additional vessels entering the kidney and considering the varying schools of thought among different authors, we have used the term additional renal artery to describe our finding. Such additional renal arteries are common in 20-30% of individuals and may arise from the aorta, the main renal artery or other nearby arterial sources.^{23,24} Available literature indicates that additional renal arteries are found in 9.76% of cadavers.^{25,26,27} According to Graves,²⁸ accessory arteries are in fact normal segmental arteries whose origin is more proximal than usual. He explains that the aberrant renal artery is often the artery to the lower segment following an unusual course after taking origin from the aorta. Our finding of a single right sided accessory renal artery supplying the kidney just below the hilum falls in line with this description. Rizzari²⁹ states that individuals having kidneys with additional arteries have an increased incidence of hypertension. Accessory arteries supplying lower pole of kidneys may cause pelviureteric obstruction and hydronephrosis.²⁸

Transplantation of kidneys that have only one renal artery is technically easier than when there is more than one renal artery with reduced rates of post

surgical complications and kidney loss.²⁷The occurrence of accessory renal arteries may be explained by the persistence of embryonic vessels arising from the common iliac arteries or aorta, which are formed during the ascent of kidneys.³⁰ Accessory renal arteries may also be formed due to the failure of degeneration of caudal mesonephric arteries during kidney development.²⁶

Renal dimensions can be useful indicators to study progression of renal disease as well as for evaluation of healthy donors in transplantation. Our morphometric findings on renal dimensions are comparable with those of More et al³¹, Murlimanju et al³² and slightly variable with those of other studies.³³ Murlimanju³² observed statistically significant differences between width and thickness of right and left kidneys which was however not seen in our study. Large kidney length is related to higher risk of cardiovascular events and mortality and may serve as a clinical marker to identify patients with increased cardiovascular risk.³⁴ There is significant correlation between kidney function and size in patients with chronic kidney disease.³⁵

This study concludes that variations in hilar structural patterns and renal dimensions hold considerable clinical significance and need to be carefully identified for better treatment outcomes. The findings of this study may contribute to reinforce present literature and add to existing knowledge and research in this area.

REFERENCES

1. Standring S. Gray's Anatomy. *The Anatomical Basis of Clinical Practice*. Elsevier Churchill Livingstone, New York. 41st edition; pg 1237-1240.
2. Pereira-Correia JA, Valentim LS, Castro KF et al. Analysis of renal hilum extraparenchymal structures in Brazilian adult human cadavers. *Eur J Anat*. 2009; 13(3): 145-153.
3. Desai MM, Gill IS. Laparoscopic partial nephrectomy for tumour: current status at the Cleveland Clinic. *BJU Int*. 2005; 95(2):41-45.
4. Heuer R, Gill IS, Guazzoni G. A critical analysis of the actual role of minimally invasive surgery and active surveillance for kidney cancer. *Eur Urol*. 2010 ;57 (2):223-232.
5. Rapp DE, Orvieto MA, Gerber GS et al. En bloc stapling of renal hilum during laparoscopic nephrectomy and nephroureterectomy. *Urology*. 2004; 64(4):655-659.
6. Lijin Zhang ,Bin Wu , Zhenlei Zha et al. Comparison of selective and main renal artery clamping in partial nephrectomy of renal cell cancer. A PRISMA-compliant systematic review and meta-analysis. *Medicine* 2018; 97(34): e11856.
7. Desai MM, De Castro Abreu AL, Leslie S et al. Robotic partial nephrectomy with superselective versus main artery clamping: a retrospective comparison. *Eur Urol*. 2014 ;66(4):713-719.
8. Glodny B, Unterholzner V, Taferner B et al. Normal kidney size and its influencing factors - a 64-slice MDCT study of 1.040 asymptomatic patients. *B.M.C. Urol*. 2009; 9:19.
9. Wu-Xing Zhang, Zhi-Min Zhang, Bing-Sheng Cao, Wei Zhou. Sonographic measurement of renal size in patients undergoing chronic hemodialysis: Correlation with residual renal function. *Exp Ther Med*. 2014; 7(5): 1259-1264.
10. Trivedi S, Athavale S, Kotgiriwar S. Normal and variant anatomy of renal hilar structures and its clinical significance. *International journal of Morphology*. 2011;29(4): 1379-1383.
11. Kumar N, Guru A, P Aithal A et al. Evaluation of the Variant Anatomical Disposition of the Renal Hilar Structures in South Indian Adult Human Cadavers and Its Clinical Implications. *Journal of Clinical and Diagnostic Research*. 2013; 7(8): 1543-1546.
12. Jadhav S, Zambare B. Anatomical study of arrangement of renal hilar structures in Indian Adult human cadavers. *Natl J Integr Res Med*. 2015;6(3):49-53.
13. Divya .C, Ashwini.N.S, Swaroop Raj.B.V, Venkateshu. K.V. STUDY OF ARRANGEMENT OF RENAL HILAR STRUCTURES IN HUMAN CADAVERS. *Int J Anat Res* 2018;6(1.2):4890-4896. DOI: 10.16965/ijar.2017.500
14. Daescu E, Zahoi DE, Motoc A. Morphological variability of the renal artery branching pattern: a brief review and an anatomical study. *Rom J Morphol Embryol*. 2012; 53(2):287-291
15. Budhiraja V, Rakhi Rastogi R, Asthana AK. Renal artery variations: embryological basis and surgical correlation. *Rom J Morphol Embryol*. 2010; 51(3):533-536.
16. Das S, Paul S. Variation of renal hilar structures: a cadaveric case. *Eur J Anat* 2006;10:41-43.
17. Rouvière O, Lyonnet D, Berger P, Pangaud C, Gelet A, Martin X. Ureteropelvic junction obstruction: use of helical CT for preoperative assessment: comparison with intraarterial angiography. *Radiology* 1999;213: 668-673.
18. Sampaio FJ, Passos MA. Renal arteries: anatomic study for surgical and radiological practice. *Surg Radiol Anat* 1992; 14(2):113-117.
19. Budhiraja V, Rastogi R, Asthana A K. Variant origin of superior polar artery and unusual hilar branching pattern of renal artery with clinical correlation. *Folia Morphol*. 2011; 70(1): 24-28
20. Saldarriaga B, Pinto SA, Ballesteros LE. Morphological expression of the renal artery. A direct Anatomical

- study in a Colombian half-caste population. *Int J Morphol.* 2008;26:31–38.
21. N. Shakuntala Rao, Krishna Kishore, Sujatha. K, H.R.Krishna Rao. Extra Hilar Branching Of Renal Arteries: An Anatomical Study. *Int J Anat Res.* 2015;3(4):1568-1572. DOI: 10.16965/ijar.2015.290
22. Gulas E, Wysocki G, Szymanski J et al. Morphological and clinical aspects of the occurrence of accessory (multiple) renal arteries. *Arch Med Sci.* 2018; 14(2): 442–453.
23. Mir NS, Hassan AU, Rangrez R, et al. Bilateral duplication of renal vessels: anatomical, medical and surgical perspective. *Int J Health Sci (Qassim)* 2008;2 (2):179–185.
24. Merklin RJ, Michels NA. The variant renal and suprarenal blood supply with data on the inferior phrenic, ureteral and gonadal arteries: a statistical analysis based on 185 dissections and review of the literature. *J Int Coll Surg.* 1958 ;29:41-76.
25. Khamanarong K, Prachaney P, Utraravichien A, Tong-Un T, Sripaoraya K. Anatomy of Renal Arterial Supply. *Clinical Anatomy.* 2004;17:334 –336
26. Satyapal KS, Haffjee AA, Singh B, Ramsaroop L, Robbs JV, Kalideen JM. Additional renal arteries: incidence and morphometry. *Surg Radiol Anat* 2001;23:33-38.
27. Ozkan U, Oguzkurt L, Tercan F et al. Renal artery origins and variations: angiographic evaluation of 855 consecutive patients. *Diagn Interv Radiol* 2006; 12:183-186
28. Graves FT. The Aberrant Renal Artery. *J Anat.* 1956 ; 90: 553–558
29. Rizzari MD, Suszynski TM, Gillingham KJ, Matas AJ, Ibrahim HN. Outcome of living kidney donors left with multiple renal arteries. *Clin Transplant.* 2012 ;26(1):E7-11.
30. Keibel F, Mall FP. *Manual of human embryology.* J.B. Lippincott, Philadelphia. 1912;2, 820-825
31. Manisha S More, Manoj D Togale, Daksha Dixit, S P Desai . A morphometric study of human adult cadaveric kidneys. *MedPulse – International Medical Journal* June 2015;2 (6):355-358. <http://www.medpulse.in>
32. Murlimanju BV, Kumar BM, Kumar N et al. Morphometric parameters of the human adult kidney: An anatomical study. *Int. J. Morphol.* 2014; 32(2):656-659.
33. Raza M, Hameed A, Khan MI. Ultrasonographic assessment of renal size and its correlation with body mass index in adults without known renal disease. *J Ayub Med Coll Abbottabad.* 2011 ;23(3):64-68.
34. Van der Sande NGC, Visseren FLJ, van der Graaf Y et al. Relation between Kidney Length and Cardiovascular and Renal Risk in High-Risk Patients. *Clin J Am Soc Nephrol.* 2017;12(6):921-928.
35. Jovanovic D, Gasic B, Pavlovic S, Naumovic R. Correlation of kidney size with kidney function and anthropometric parameters in healthy subjects and patients with chronic kidney diseases. *Ren Fail.* 2013; 35(6):896-900