

## REVASCULARISATION OF AN IMMATURE PERMANENT TOOTH USING PLATELET RICH FIBRIN AND BIODENTIN AS A MATRIX - A CASE REPORT

Dr. Anil K Tomer<sup>1</sup>, Dr. Panna Mangat<sup>2</sup>, Dr. Akankshita Behera<sup>3</sup>, Dr. Savneet Kour<sup>4</sup>, Dr. Artika Gupta<sup>5</sup>,  
Dr. Vasuda Bhagat<sup>6</sup>, Dr. Nitish Mittal<sup>7</sup>

<sup>1</sup>Professor and Head, Dept. of Conservative Dentistry and Endodontics, Divya Jyoti, College of Dental Sciences and Research, Modinagar, Ghaziabad

<sup>2</sup>Professor, Dept. of Conservative Dentistry and Endodontics, Divya Jyoti, College of Dental Sciences and Research, Modinagar, Ghaziabad

<sup>3,5,7</sup> Post Graduate students, Dept. of Conservative Dentistry and Endodontics, Divya Jyoti, College of Dental Sciences and Research, Modinagar, Ghaziabad

<sup>4</sup>BDS, Private Practitioner, Jammu.

<sup>6</sup>Post Graduate Student, Dept. of Oral Medicine Radiology, Divya Jyoti, College of Dental Sciences and Research, Modinagar, Ghaziabad

**Article Info:** Received 29 June 2019; Accepted 28 July. 2019

**DOI:** <https://doi.org/10.32553/ijmbs.v3i7.431>

**Address for Correspondence:** Dr. Akankshita Behera , PG Student, Dept. of Conservative Dentistry and Endodontics, Divya Jyoti College of Dental Sciences and Research, Modinagar, Ghaziabad, Uttar Pradesh

**Conflict of interest:** Nil

### Abstract

Any injury to the pulp during its development lead to cessation of dentin formation and root growth. Status of the pulp and root development are the decisive factors in the treatment approach. Various treatment options include surgery with root end sealing, apexification using calcium hydroxide ,placement of apical plug and regenerative endodontic procedures to induce

apexogenesis. This study describes the treatment of an immature permanent tooth which was treated with regenerative approach using 3% NaOCl and 17% ethylenediaminetetraacetic acid as irrigants, and then medicated with triple antibiotic paste, after that platelet rich fibrin (PRF) and Biodentine were place in the canal. On follow up at 3 ,6,12 months healing of periapical lesion, dentinal thickening, and apical closure were evident. So, PRF can be used for the treatment of immature permanent teeth with periapical lesion, as part of a regenerative endodontic procedures.

**Keywords:** Platelet rich fibrin (PRF), Biodentine, open apex, revascularisation

### INTRODUCTION

Current endodontic therapy aims to maintain the health of the pulp in cases of inflammation but a much desired objective is the regeneration of a healthy pulp-dentin complex. Presence of an immature apex in a tooth with pulpal injury presents a significant challenge, as routine root canal procedures cannot be performed ideally when the apex is not closed. Better alternative to these cases, even when the tooth exhibit periapical pathology, is offered by revascularization procedures.

Revascularization procedures helps to preserve the vitality of remaining dental pulp stem cells and mesenchymal stem cells of the apical papilla resulting

in the root maturation i.e. elongation of root length with an increase in root dentin thickness.

The conventional method of revitalization procedure was done by inducing bleeding into the pulp canal by mechanically irritating the periapical tissues. The blood clot acts as a matrix for the in growth of new tissues into the pulp canal. But, this procedure cause discomfort for the patient while mechanically irritating the periapical tissues.

In revascularization various biomaterials such as collagen, platelet rich plasma (PRP) can be used as a scaffold in addition to blood clot. However, the use of bovine thrombin for the activation of Platelet Rich Plasma (PRP) has been an issue of controversy which led to the development of the second generation Platelet concentrate known as Choukroun's Platelet

Rich Fibrin (PRF) which is totally autologous in nature. PRF was developed in France by Choukroun *et al*, in 2001. This technique is very simple and inexpensive. PRF contains platelets, growth factors, and cytokines that enhance the healing potential of both soft and hard tissues. This case report describes regenerative endodontic treatment using PRF in immature tooth.

### CASE REPORT

A 16-year-old male patient reported to the department of conservative dentistry and endodontics with a chief complaint of pain in relation to maxillary left central incisor. History revealed that the patient had suffered trauma at the age of 11 years. The vitality of the tooth was done by the cold test, using refrigerator spray . It showed negative response. Radiographic examination showed an immature tooth with a wide open apex and a radiolucent area in proximity of the apex of the tooth. Asymptomatic apical periodontitis with necrotic pulp was the diagnosis.(Figure1). On basis of clinical and radiographic findings, regenerative endodontic procedures were planned using platelet rich fibrin (PRF).

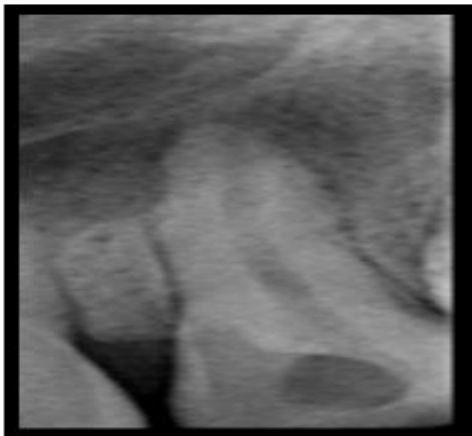
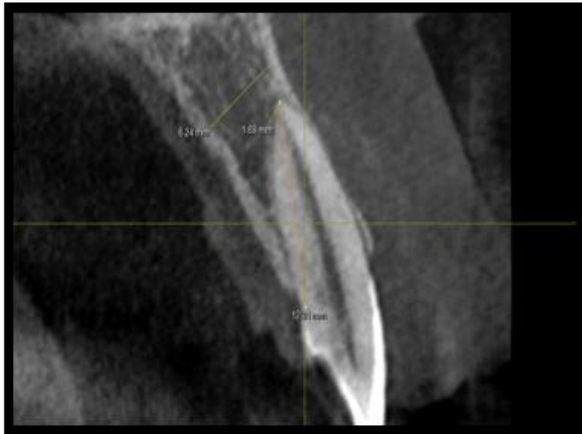
Figure 1: Pre-operative CBCT and IOPAR

Access cavity was prepared under local anaesthesia and rubber dam isolation. Working length was determined using radiograph . Biomechanical preparation was done upto 70 K file. Copious irrigation was done using 3% NaOCl and 17% ethylenediaminetetraacetic acid. Triple antibiotic was prepared by mixing equal proportions of metronidazole, ciprofloxacin and minocycline (Figure 2) . This antibiotic mixture was placed into the canals using a lentulo spiral up to the canal orifice. A cotton pellet was placed inside the pulp chamber and access cavity was sealed with Cavit .

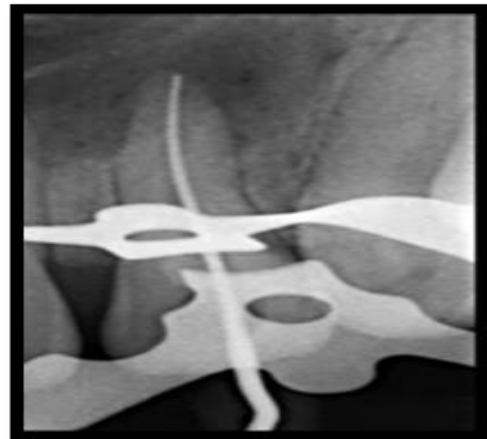
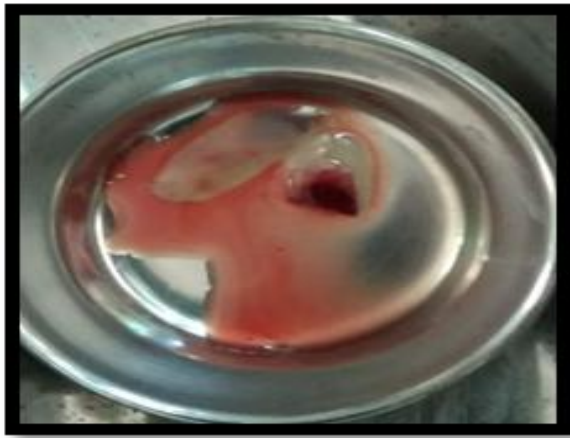
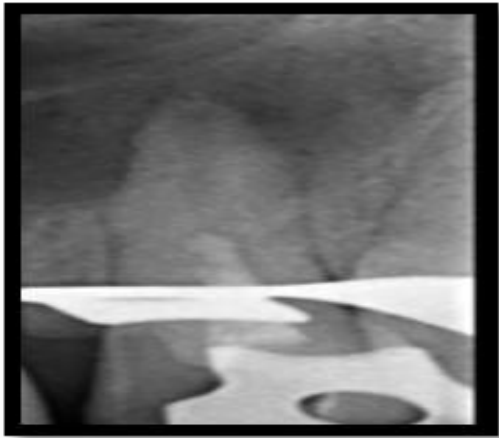
Figure 2: Working length determination and placement of triple antibiotic paste

Patient was recalled after 21 days. A 10 ml blood was drawn from the patient's right arm. The blood sample was transferred into a test tube without anti-coagulant and centrifuged immediately in centrifugal machine at 3000rpm for 10 minutes to obtain the PRF.

PRF was obtained in the test tube as the middle layer with acellular plasma at the top and red blood cell (RBC) at the bottom .PRF was removed from the test tube with the help of sterile tweezers and was converted into membrane (Figure 3a) .This fibrin membrane was fragmented into small pieces with the help of surgical scissors . So, that it can be easily placed inside the canals. Local anaesthesia was given and after rubber dam isolation, the access cavity was reopened and irrigated with saline to remove the antibiotic mixture .Canal was dried with paper points and was ready for the placement of PRF (Figure 3b).



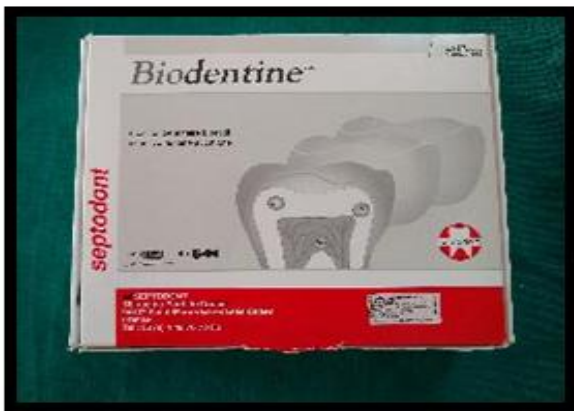(3A)



(3B)

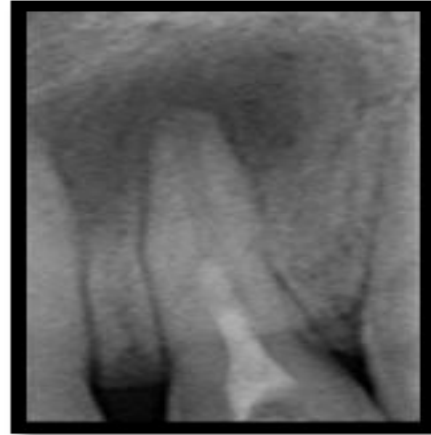**Figure 3a, 3b: PRF and placement of PRF in the canal**

The membrane was placed in the pulp chamber and pushed apically with the help of endodontic pluggers below the level of cementoenamel junction. Biodentine (Septodont, France) was placed directly over the fibrin clot and the remainder of the cavity was sealed with composite restoration (Figure 4)

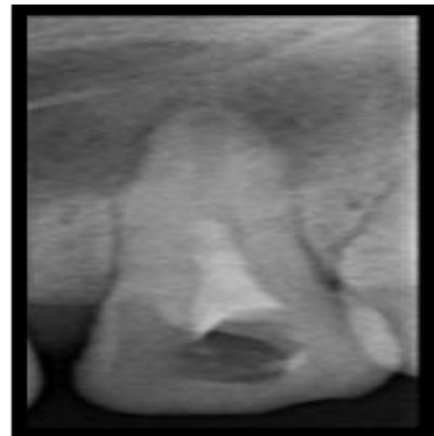

**Figure 4: Biodentine**

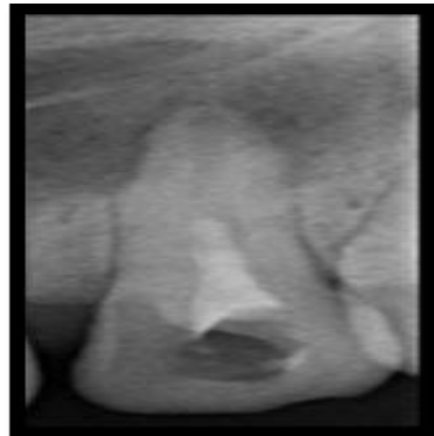On follow up at 3,6,12 months, clinically tooth was asymptomatic and was not tender to percussion. Pulp tests, cold test showed positive response. Radiographic examination showed the resolution of periapical lesion, thickening of dentinal walls, root lengthening with apical closure observed on CBCT scans.(Figure 5)



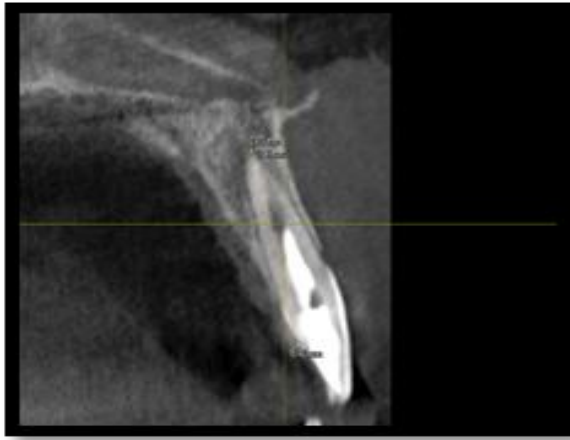
(A)



(B)



(C)



(D)

Figure 5: (a,b,c,d). Follow up at 3,6,12 months and CBCT scan after 1 year

## DISCUSSION

Regenerative endodontics are biologically based procedures designed to replace damaged structures, including dentin and root structures, as well as cells of the pulp dentin complex.. Several case reports demonstrated that, teeth with necrotic pulp and immature apices are capable of regenerating tissues of pulp-dentin complex, continue root maturation with closure of apex and can regain tooth vitality with proper disinfection and a suitable scaffold.

Banchs and Trope conducted a case report where revascularization of immature permanent teeth with apical periodontitis was made possible by inducing blood clot into the pulp canal by mechanically irritating the periapical tissues which they attributed to the total disinfection of the canal. This procedure might cause discomfort to the patient , so there was a quest for a better approach in regenerative endodontics which led to the introduction of Platelet Rich Plasma, Platelet Rich Fibrin (PRF) in the revitalization procedures.

Unlike previous case reports, we use PRF which is a second generation platelet concentrate with a simplified preparation technique autologous in nature. It is an accumulation of platelets and cytokines in a fibrin clot. The platelets concentrate mainly at the junction between the red corpuscles (red thrombus) and the PRF clot in the test tube. This platelet component of PRF is considered vital for regeneration .PRF has several advantages over other platelet concentrates. It enmeshes glycosaminoglycans, which in turn attracts platelet cytokines and also has greater capacity for cell

migration. The PRF releases high quantities of growth factors like transforming growth factor beta-1, platelet derived growth factor AB, vascular endothelial growth factor and glycoprotein, which stimulates cell migration and proliferation.

Biodentine was directly placed over the PRF clot to obtain a tight seal and avoid bacterial contamination. Biodentine possess enhanced properties such as quick setting time (in comparison with MTA), good marginal adaptation and high strength not usually associated with other tricalcium cements . Chang SW et al., suggested that this could be useful for regenerative endodontic procedures, since it stimulates odontoblastic differentiation and nodule formation during mineralisation .

At the end of 1 year follow-up, the tooth was responding positively to pulp sensibility tests and the radiographic examination revealed resolution of periapical lesion, thickening of the dentinal walls, root lengthening with apical closure showing continuous lamina dura. This effect can be due to cytokines and growth factors released from PRF. Evidence have shown that, pulp-like tissue can be regenerated with the use of platelet concentrate. The successful outcome of this case can be attributed to the formation of pulp-like tissue and cell differentiation. The exact nature of the tissue generated can be studied only by histological examination.

## CONCLUSION

The outcome of this case report suggests that the conservative treatment approach can create a suitable environment for pulp regeneration and result in root maturation via regaining the vitality of the tooth. The trio of disinfection with triple antibiotic paste, PRF as a scaffold and Biodentine as a bio-interactive material seems to be a viable combination for pursuing regenerative treatment. However, long term follow up is necessary to ensure and evaluate success.

## REFERENCES

1. Silva RV, Silveira FF, Nunes E. Apexification in non-vital teeth with immature roots: report of two cases. *Iran Endod J.* 2015;10(1):79-81.
2. Trope M. Treatment of the immature teeth with non-vital pulps and apical periodontitis. *Dent Clin North Am.* 2010 Apr;31:313–24
3. Chueh LH, Ho YC, Kuo, Lai WH, Chen YH, Chiang CP. Regenerative endodontic treatment for necrotic

- immature permanent teeth. *J Endod.* 2009;35:160–165
4. Chueh LH, Huang GT. Immature teeth with periradicular periodontitis or abscess undergoing apexogenesis: A paradigm shift. *J Endod* 2006;32:1205–13
  5. Torabinejad M, Turman M. Revitalization of tooth with necrotic pulp and open apex by using platelet-rich plasma: A case report. *J Endod.* 2011;37:265–8
  6. Huang FM, Yang SF, Zhao JH, Chang YC. Platelet-rich fibrin increases proliferation and differentiation of human dental pulp cells. *J Endod.* 2010;36:1628–32
  7. Shivashankar VY, Johns DA, Vidyanath S, Kumar MR. Platelet rich fibrin in the revitalization of tooth with necrotic pulp and open apex. *J Conserv Dent.* 2012;15(4):395–98.
  8. Kim JH, Kim Y, Shin SJ, Park JW, Jung IY. Tooth discoloration of immature permanent incisor associated with triple antibiotic therapy: A case report. *J Endod.* 2010;36(6):1086–91.
  9. Keswani D, Pandey RK. Revascularization of an immature tooth with a necrotic pulp using platelet-rich fibrin: A case report. *Int Endod J.* 2013;46(11):1096–104.
  10. Chang SW, Lee SY, Ann HJ, Kum KY, Kim EC. Effects of calcium silicate endodontic cements on biocompatibility and mineralization-inducing potentials in human dental pulp cells. *J Endod.* 2014; 40(8):1194–200