

## EFFECT OF AGE & SEX ON MORPHOMETRIC EVALUATION OF ACETABULAR ANGLES – A PLAIN CT BASED STUDY.

Dr Surjeet Singh<sup>1</sup>, Dr Punit Katoch<sup>2</sup>

Department of Orthopaedics, Dr Rajendra Parsad Government Medical College, Kangra at Tanda, Himachal Pradesh

**Article Info:** Received 30 June 2019; Accepted 19 July, 2019

**DOI:** <https://doi.org/10.32553/ijmbs.v3i7.400>

**Address for Correspondence:** Dr Punit Katoch

**Conflict of interest:** Nil

### Abstract

**Background:** Anthropometric study of the hip joint has important clinical implications. A thorough knowledge of hip joint anatomy is a prerequisite to understand its biomechanics.

**Methods:** It was a hospital based observational study conducted for the period of one year starting from 17th September 2015 to 16th September 2016. The study population included all patients in the age group of 18 years and above submitting to the department of Radiodiagnosis for either abdominal, lower spinal or non orthopaedic pathology of pelvic and hip region.

**Results:** Mean of right acetabular in males is  $16.9^{\circ} \pm 4.33^{\circ}$ SD and mean of left acetabular anteversion angle in males is  $16.5^{\circ} \pm 4.2^{\circ}$ SD. Mean of right acetabular in females is  $18.1^{\circ} \pm 4.8^{\circ}$ SD and mean of left acetabular anteversion angle in females is  $17.6^{\circ} \pm 4.7^{\circ}$ SD

**Conclusion:** There is significant side to side difference in acetabular abduction angle of male and female and abduction angle don't change significantly with age. There is significant side to side difference in acetabular anteversion angle of male (p-value <0.05) and female and anteversion angle don't change significantly with age. Anteversion angle found to be more in female as compared to male.

**Keywords:** Hip bone, Acetabular angle, CT scan.

### Introduction

It is well known that abduction and anteversion angles cannot reliably be evaluated with plain X-ray film, since pelvic tilt changes the measurement of angles of the native acetabulum by as much as  $10^{\circ}$ , more over it is difficult to study 3-dimensional acetabulum on 2-dimensional radiograph completely. Measurements derived from CT have the potential to alleviate this problem, but changing obliquity, rotation, and tilt of a pelvis in a CT scanner affected the measurement of acetabular variables.<sup>2</sup>

Acetabular anteversion and abduction angles are widely used in orthopaedic surgery practice. However, their definition and evaluation is often based on partial scientific evidence. Radiological inclination is defined as angle between the longitudinal axis and acetabular axis, when this is projected in coronal plane where as Radiological anteversion is the angle between acetabula plane and coronal plane.<sup>3</sup>

### MATERIAL AND METHODS

### Methodology:

This study was conducted in the department of Orthopaedics and Radiodiagnosis at Dr RPGMC Tanda. It was a hospital based observational study conducted for the period of one year starting from 17th September 2015 to 16th September 2016. The study population included all patients in the age group of 18 years and above submitting to the department of Radiodiagnosis for either abdominal, lower spinal or non orthopaedic pathology of pelvic and hip region. The following patients were excluded from study.

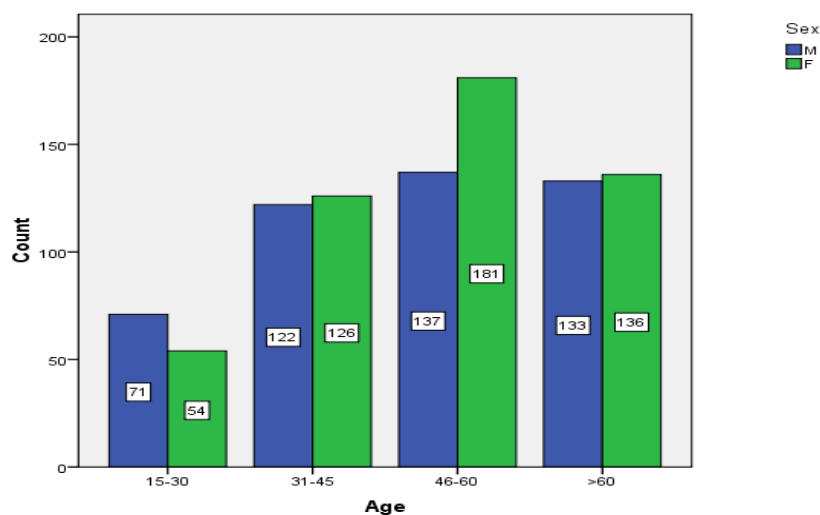
- The patient with fracture neck of femur, fracture of acetabulum, pelvic fracture.
- Old operated cases of above mentioned fractures.
- Patient with deformity in the hip.
- Osteoarthritis of hip
- Patients who denied consent

Each patient and his attendants were adequately informed of the aims, methods, the anticipated benefits and potential risks of the study and the discomfort it may entail them and the remedies thereof. Every precaution was taken to respect the privacy of the patient, the confidentiality of the patient's information and to minimize the impact of the study on his/her physical and mental integrity and personality. The patients were given the right to abstain from participation in the study or to withdraw consent to participate at any time of the study without reprisal. Due care and caution was taken at all stages of the research to ensure that the patient is put to minimum risk, suffer from no

irreversible adverse effects and, generally, benefit from and by the research or experiment. Written informed consent was obtained from all the patients and attendants included in the study.

All CT scan included scanning by Anteroposterior tomogram as well as axial images of both acetabulum. All angles were measured at CT work station. Measurements of the angles were performed by a team comprising of one member from the department of Orthopaedics and other from Radiodiagnosis. The process of measurement was supervised by two consulting Orthopaedicians.

## RESULTS:



The study had total 960 patients; 463 males and 497 females. Majority of the population is from the age group (46- 60) years. Majority of the males were in age group from 46 to 60 years (  $n=137/463$  ) and majority of the females were in same age group, 46 to 60 years (  $n=181/497$  ). Lowest number of males and females were in age group ranging from 15 to 30 years (male,  $n=71/463$ ; female,  $n=54/497$  ).

**Table 1: Showing distribution of right and left acetabular abduction angle in sex wise of different age groups.**

Age group (Yrs)	Sex			
	Male		Female	
	R.Abduction (Mean±SD) (°)	L.Abduction (Mean±SD) (°)	R.Abduction (Mean±SD) (°)	L.Abduction (Mean±SD) (°)
15-30	34.3±5.3	35±5.3	35.6±2.8	36.8±4.0
31-45	34.0±4.0	35.1±4.65	34.7±4.2	36.3±4.5
46-60	33.9±4.6	34.7±4.67	34.1±4.6	35.3±4.6
>60	34.3±4.8	34.9±4.71	34.1±4.7	35.1±4.8
Total	34.1±4.6	34.9±4.7	34.4±4.5	35.6±4.6
p-value	<0.001		<0.001	

Mean of right acetabular abduction angle in males is  $34.1^{\circ} \pm 4.6^{\circ}$ SD and mean of left acetabular abduction angle in males is  $34.9^{\circ} \pm 4.7^{\circ}$ SD. It also shows that there is significant difference in abduction angle from side to side however there is no significant change with increasing age (p-value is  $<0.05$ ). Highest mean value is observed on right side is  $34.3^{\circ} \pm 5.3^{\circ}$ SD in age group 15 to 30 years and  $35.1^{\circ} \pm 4.6^{\circ}$ SD on left side in 31 to 45 years. Mean of right acetabular abduction angle in females is  $34.4^{\circ} \pm 4.5^{\circ}$ SD and mean of left acetabular abduction angle in females is  $35.6^{\circ} \pm 4.6^{\circ}$ SD with an interquartile range of  $5.5^{\circ}$  on right and  $6.5^{\circ}$  on left side. It also shows that there is significant difference in abduction angle from side to side (p value  $<0.05$ , significant), however there is no difference with increasing age. Highest value of mean acetabular abduction angle is  $35.6^{\circ} \pm 2.82^{\circ}$ SD on right side and  $36.8^{\circ}$  on the left side in age group 15 to 30 years.

Significant difference in acetabular abduction angle in males and females and difference in left and right side of abduction angle is also significant.

**Table 2: Showing distribution of right and left acetabular anteversion angle in sex wise of different age groups.**

Age group (Yrs)	Sex			
	Male		Female	
	R. anteversion (Mean $\pm$ SD) ( $^{\circ}$ )	L. anteversion (Mean $\pm$ SD) ( $^{\circ}$ )	R. anteversion (Mean $\pm$ SD) ( $^{\circ}$ )	L. anteversion (Mean $\pm$ SD) ( $^{\circ}$ )
15-30	15.8 $\pm$ 4.66	15.4 $\pm$ 4.35	18.2 $\pm$ 4.07	17.7 $\pm$ 3.86
31-45	16.6 $\pm$ 4.43	16.0 $\pm$ 4.19	18.2 $\pm$ 4.49	17.6 $\pm$ 3.92
46-60	17.5 $\pm$ 4.35	17.0 $\pm$ 4.17	17.9 $\pm$ 4.85	17.4 $\pm$ 4.55
>60	17.03 $\pm$ 4.06	17.1 $\pm$ 4.2	18.3 $\pm$ 5.27	17.8 $\pm$ 5.54
Total	16.9 $\pm$ 4.03	16.5 $\pm$ 4.2	18.1 $\pm$ 4.8	17.6 $\pm$ 4.7
p-value	<0.01		<0.01	

Mean of right acetabular in males is  $16.9^{\circ} \pm 4.3^{\circ}$ SD and mean of left acetabular anteversion angle in males is  $16.5^{\circ} \pm 4.2^{\circ}$ SD with an interquartile range of 6mm on right and  $5.5^{\circ}$  on left side. It also shows that there is significant change in anteversion angle from side to side (p-value  $<0.05$ , not significant) and with increasing age. Highest values were observed in age group of 60 years and above and lowest in 15 to 30 years. Mean of right acetabular in females is  $18.1^{\circ} \pm 4.8^{\circ}$ SD and mean of left acetabular anteversion angle in females is  $17.6^{\circ} \pm 4.7^{\circ}$ SD with an interquartile range of 6mm on right and  $5.5^{\circ}$  on left side. It also shows that there is significant difference in anteversion angle from side to side (p-value  $<0.05$ , significant) however there is no significant with increasing age. Highest value on right side is  $18.3^{\circ} \pm 5.2^{\circ}$ SD observed in age group 60 years and above and  $17.8^{\circ} \pm 5.5^{\circ}$ SD on left side in same age group

## DISCUSSION

The present study was conducted to do the morphometric evaluation of acetabular width,

depth and angles using plain CT scan in patients 18 years and above submitting either with abdominal, lower spinal or non orthopaedic pathology of pelvic region, to the department of Radiodiagnosis fulfilling the inclusion criterias, were included in study. An extensive Pub Med search revealed few studies conducted in rural areas. A total of 960 patients were evaluated under following headings.

Present study demonstrated abduction angle to be  $34.3^{\circ}$  on right and  $35.3^{\circ}$  on the left side. It was observed that there is a significant difference in abduction angle in female and male and there is also a significant intraindividual difference in right and left side of the acetabulum. Our values are lower than values reported in some of the studies <sup>2,3</sup>. But there are other studies which has reported abduction angle less than  $40^{\circ}$  <sup>4,5</sup>, which are close to our study. The data also showed trends that there is side to side as well as gender based difference in abduction angle <sup>6,7</sup>.

We found anteversion angle comparable with other studies <sup>2,3</sup> which show an increase in value with age,

however some author report there is quite small age related difference in angle when variability of angle seen between individuals. We also found that anteversion angle is more in female as compared with male<sup>8,9</sup> and there is significant side to side difference in anteversion angle in female in present study.

## CONCLUSION

There is significant side to side difference in acetabular abduction angle of male and female and abduction angle don't change significantly with age. There is significant side to side difference in acetabular anteversion angle of male (p-value <0.05) and female and anteversion angle don't change significantly with age. Anteversion angle found to be more in female as compared to male

## REFERENCES

1. Lubosky O, Peleg E, Joskowicz L, Liebergall M, Khoury A. Acetabular orientation variability and symmetry based on CT Scan of Adults. *Int J Computer Assisted Radiology and Surgery* 2010;5:449-54.
2. Murray DW. The definition and measurement of acetabular orientation. *J Bone Joint Surg Br* 1993;75:228-32.
3. Anda S, Svenningsen S, Dale LG, Benum P. The acetabular sector angle of the adult hip determined by computed tomography. *Acta Radiol Norway* 1986; 27: 443-8.
4. Murphy SB, Kijewski PK, Millis MB, Harless A. Acetabular dysplasia in the adolescent and young adult. *Clin Orthop* 1990;261:214-23.
5. Genda E, Iwasaki N, Li G. Normal hip joint contact pressure distribution in single-leg standing – effect of gender and anatomic parameters. *J Biomech*. 2001; 34: 895-905.
6. Umer M, Thambyah A, Tan WT. Acetabular morphometry for determining hip dysplasia in the Singaporean population. *J Orthop Surg (Hong Kong)*.2006; 14: 27-31.
7. McKibbin B. Anatomical factors in the stability of the hip joint in the newborn. *J Bone Joint Surg Br*. 1970;52:148-159.
8. Lewinnek GE, Lewis JL, Tarr R. Dislocations after total hip replacement arthroplasties. *J Bone Joint Surg Am*.1978; 60: 217- 20.
9. Buller LT, Rosneck J, Monaco FM. Relationship between proximal femur and acetabular alignment in normal hip joint using 3-dimensional computed tomography .*Am J Sports Med*.2011; 10: 1177.