

Clinicopathological Spectrum of Colorectal Polyps in a Tertiary Care Center

Smriti Rathore¹, Prashant Kumar Singh²

¹Assistant Professor, Department of Pathology, Shri Balaji Institute of Medical Sciences, Chhattisgarh, India

²Assistant Professor, Department of Medicine, Shri Balaji Institute of Medical Sciences, Chhattisgarh, India

Received: 02-10-2025 / Revised: 24-10-2025 / Accepted: 30-10-2025

DOI: <https://doi.org/10.32553/ijmbs.v9i5.3190>

Corresponding author: Smriti Rathore

Conflict of interest: No conflict of interest

Abstract:

Background: Colorectal polyps comprise a wide range of mucosal lesions encountered during colonoscopic evaluation, and their clinical significance varies depending on histological type and associated dysplasia. Timely detection and accurate histopathological assessment of these lesions remain central to colorectal cancer prevention.

Objectives: The study was conducted to evaluate the clinicopathological features of colorectal polyps and to analyze their distribution with respect to demographic profile, site, histology, and dysplasia.

Materials and Methods: A retrospective analysis was performed at Shri Balaji Institute of Medical Science over a three-year period. One hundred colorectal polyp specimens received in the Department of Pathology were included. Available clinical and endoscopic details were reviewed, and all specimens were examined histologically using routine hematoxylin and eosin staining. Statistical analysis was carried out using descriptive methods and the chi-square test.

Results: Neoplastic polyps formed the majority of cases, among which adenomatous polyps were most frequently identified. Dysplasia was observed predominantly in adenomatous polyps, and this association was found to be statistically significant ($p < 0.001$).

Conclusion: Adenomatous polyps formed the majority of colorectal polyps in the present study and were often associated with dysplastic changes. Careful histopathological assessment of all colorectal polyp specimens is therefore important in routine practice.

Keywords: Colorectal polyps, adenoma, dysplasia, histopathology, retrospective study

This is an Open Access article that uses a funding model which does not charge readers or their institutions for access and distributed under the terms of the Creative Commons Attribution License (<http://creativecommons.org/licenses/by/4.0>) and the Budapest Open Access Initiative (<http://www.budapestopenaccessinitiative.org/read>), which permit unrestricted use, distribution, and reproduction in any medium, provided original work is properly credited.

Introduction

Colorectal polyps are abnormal mucosal growths arising from the epithelial lining of the colon and rectum and are frequently detected during colonoscopic evaluation [1]. These lesions are of clinical importance as certain types, particularly adenomatous polyps, are well-established precursors of colorectal carcinoma [2].

The concept of the adenoma–carcinoma sequence, proposed by Fearon and Vogelstein, explains the gradual progression of benign adenomatous lesions to invasive malignancy through a series of genetic alterations [3]. Several factors influence the malignant potential of colorectal polyps, including their size, histological pattern, degree of dysplasia,

and anatomical location within the colon [4,5].

While non-neoplastic polyps such as hyperplastic and inflammatory polyps are generally considered to have minimal malignant risk, increasing attention has been directed toward serrated polyps due to their role in an alternative pathway of colorectal carcinogenesis [6–8]. Recognition of these lesions is therefore essential during histopathological evaluation.

The occurrence and distribution of colorectal polyps vary across populations and are influenced by age, sex, dietary habits, lifestyle factors, and geographic region [9–11]. In the Indian population, comprehensive data describing the clinicopathological spectrum of colorectal polyps remain limited, particularly from tertiary care centers [12–14].

Histopathological examination remains the definitive method for classifying colorectal polyps and assessing their malignant potential [15]. A clear understanding of the local pattern of these lesions can aid in improving screening strategies and guiding appropriate clinical management. The present study was undertaken to analyze the clinicopathological spectrum of colorectal polyps in a tertiary care hospital over a three-year period.

Materials and Methods

Study Design and Setting

A retrospective descriptive study conducted at Shri Balaji Institute of Medical Science.

Study Duration

Three years (retrospective analysis of cases received before 1st November, 2025).

Sample Size

100 colorectal polyp specimens.

Inclusion Criteria

- All endoscopically resected colorectal polyps
- Adequate biopsy specimens

Exclusion Criteria

- Inadequate or autolyzed specimens
- Recurrent polyps

Histopathological Evaluation

Specimens were fixed in 10% formalin, processed routinely, and stained with hematoxylin and eosin. Polyps were classified based on WHO classification.

Statistical Analysis

Data were analyzed using SPSS software. Descriptive statistics were expressed as frequencies and percentages. Association between variables was assessed using Chi-square test. A p-value < 0.05 was considered statistically significant.

Results

A total of **100 colorectal polyp cases** were analyzed during the study period.

Age Distribution

The age of patients ranged from **18 to 78 years**, with a **mean age of 52.4 ± 13.6 years**. The highest number of cases was observed in the **51–60 years** age group (30%), followed by patients aged above 60 years (26%). The lowest incidence was noted in patients aged ≤30 years (8%). **Table 1** shows the age-wise distribution of cases.

Table 1: Age Distribution of Patients with Colorectal Polyps

Age Group (years)	Number of Cases (n)	Percentage (%)
≤30	8	8.0
31–40	14	14.0
41–50	22	22.0
51–60	30	30.0
>60	26	26.0
Total	100	100

Gender Distribution

Out of 100 patients, **62 were males** and **38 were females**, showing a **male predominance** with a male-to-female ratio of **1.6:1**.

Anatomical Distribution of Polyps

The **rectum** was the most common site of involvement, accounting for **38%** of cases, followed by the **sigmoid colon (26%)**, **descending colon (14%)**, **ascending colon (12%)**, and **transverse colon (10%)**. The anatomical distribution of colorectal polyps is depicted in **Figure 1**.

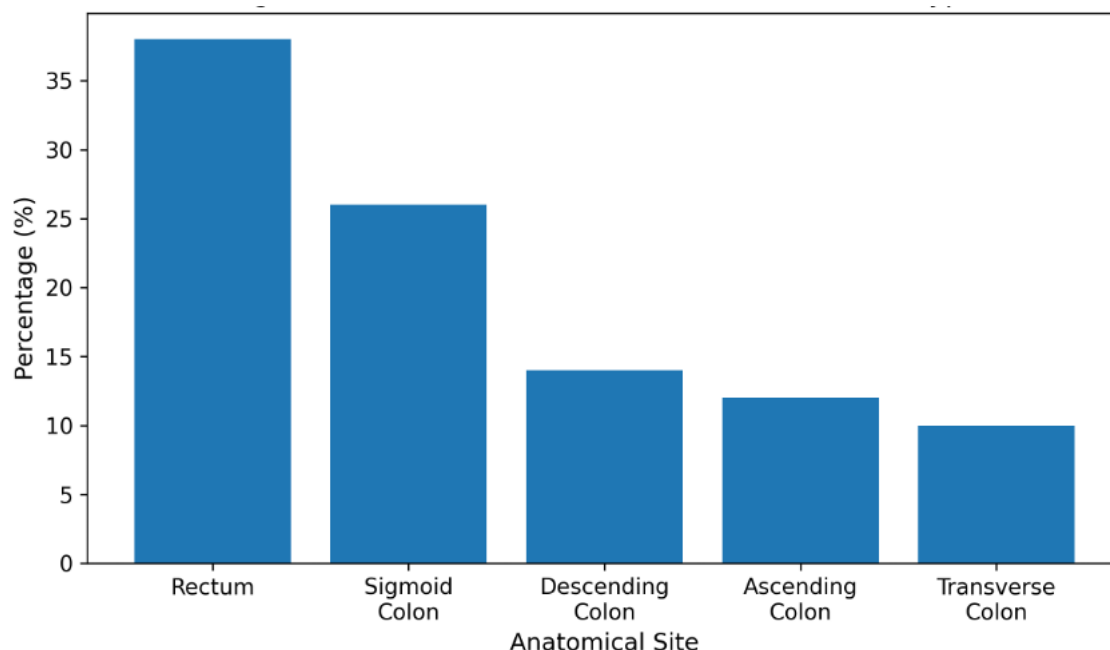


Figure 1: Anatomical Distribution of Colorectal Polyps

This figure shows the anatomical distribution of colorectal polyps observed in the study. The rectum was the most commonly involved site, followed by the sigmoid colon, while fewer cases were noted in the remaining colonic segments.

Histopathological Spectrum

On histopathological examination, polyps were broadly categorized into **neoplastic** and **non-neoplastic** lesions. Neoplastic

polyps constituted **62%** of cases, while **38%** were non-neoplastic.

Among individual histological types, **adenomatous polyps** were the most common (56%), followed by **hyperplastic polyps (18%)**, **inflammatory polyps (14%)**, **serrated polyps (8%)**, and **hamartomatous polyps (4%)**. The histopathological spectrum is summarized in **Table 2**.

Table 2: Histopathological Types of Colorectal Polyps

Type of Polyp	Number of Cases (n)	Percentage (%)
Adenomatous	56	56.0
Hyperplastic	18	18.0
Inflammatory	14	14.0
Serrated	8	8.0
Hamartomatous	4	4.0
Total	100	100

The relative proportion of neoplastic and non-neoplastic polyps is illustrated in **Figure 2**.

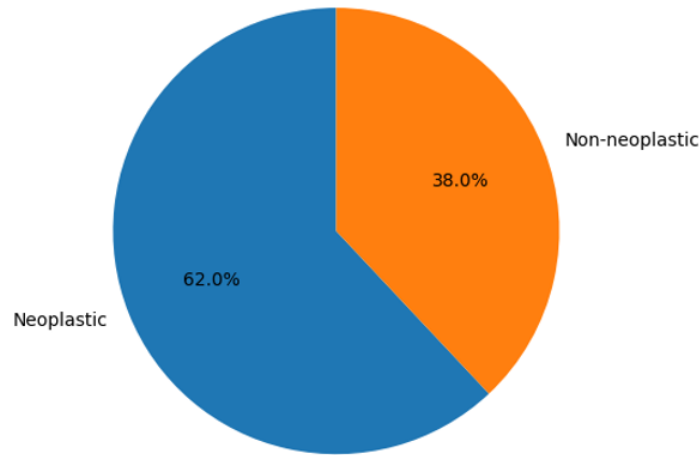


Figure 2: Distribution of Neoplastic and Non-Neoplastic Polyps.

This figure illustrates the proportion of neoplastic and non-neoplastic colorectal polyps in the study population. Neoplastic polyps constituted a higher percentage of cases compared to non-neoplastic polyps.

Among the **56 adenomatous polyps**, **41 cases (73.2%)** showed **low-grade dysplasia**, while **15 cases (26.8%)** exhibited **high-grade dysplasia**.

Degree of Dysplasia in Adenomatous Polyps

The distribution of dysplasia grades is presented in **Table 3** and illustrated in **Figure 3**.

Table 3: Degree of Dysplasia in Adenomatous Polyps (n = 56)

Degree of Dysplasia	Number of Cases (n)	Percentage (%)
Low-grade	41	73.2
High-grade	15	26.8
Total	56	100

Figure 3: Degree of Dysplasia in Adenomatous Polyps

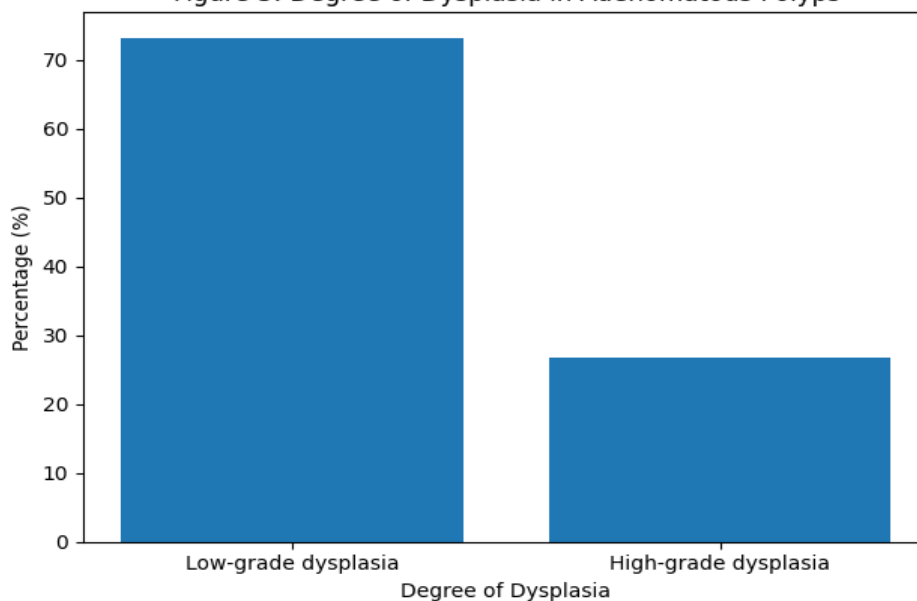


Figure 3: Distribution of Low-Grade and High-Grade Dysplasia in Adenomatous Polyps.

This figure depicts the distribution of dysplasia grades among adenomatous polyps. Low-grade dysplasia was more frequently observed than high-grade dysplasia in the present study.

Association Between Histological Type and Dysplasia

A statistically significant association was observed between **adenomatous polyps and presence of dysplasia** when compared to non-neoplastic polyps.

- **Chi-square (χ^2) value:** 18.6
- **p-value:** < 0.001 (statistically significant)

This confirms that dysplasia was predominantly associated with neoplastic polyps, particularly adenomatous polyps.

Summary of Key Findings

In the present study, colorectal polyps were most frequently observed in patients in the sixth decade of life, with a clear male predominance. The rectum emerged as the most common anatomical site of involvement, followed by the sigmoid colon. Histopathological evaluation revealed that neoplastic polyps were more prevalent than non-neoplastic lesions, with adenomatous polyps constituting the majority of cases. Among adenomatous polyps, low-grade dysplasia was the most frequently encountered, although a substantial proportion exhibited high-grade dysplasia. A statistically significant association was identified between adenomatous polyps and the presence of dysplasia, underscoring their premalignant potential and highlighting the importance of routine histopathological assessment for early detection and colorectal cancer prevention.

Discussion

Colorectal polyps are being identified more frequently in routine clinical practice, largely due to the increased use of colonoscopy, particularly in older age groups [16]. In the present study, most patients belonged to the sixth decade of life.

This age distribution is comparable to that reported by Williams et al. and Bond, who also observed a higher prevalence of polyps in older individuals [17,18].

A higher number of cases were noted among male patients. Similar observations have been made in earlier studies, where male predominance has been attributed to differences in lifestyle factors, hormonal influences, and healthcare-seeking behavior [19]. With respect to anatomical location, the rectum and sigmoid colon were the most frequently involved sites in the present study. This pattern has been consistently reported in both Indian and Western literature [20,21].

Histopathological examination revealed adenomatous polyps as the most common subtype. This finding is expected, as adenomas are well known to represent the most important precursor lesions for colorectal carcinoma [22]. In our study, dysplasia was predominantly observed in adenomatous polyps, supporting the adenoma–carcinoma sequence described by Fearon and Vogelstein and further elaborated in subsequent studies [23].

The presence of high-grade dysplasia in more than one-fourth of adenomatous polyps is clinically relevant. Such lesions are considered high risk and usually warrant closer follow-up and complete excision [24]. Although serrated polyps were less frequently encountered, their identification remains important in routine pathology reporting because of their recognized role in an alternative pathway of colorectal carcinogenesis [25].

Overall, the findings of this study reinforce the need for careful histopathological evaluation of all colorectal polyp specimens received in routine practice, as accurate classification and grading directly influence patient management and surveillance strategies.

Limitations

The present study has certain limitations that should be acknowledged. Being a

retrospective, single-center study, the findings may not be fully generalizable to the wider population. The sample size was relatively limited, and detailed follow-up data were not available to assess long-term outcomes or progression of polyps. Additionally, clinical risk factors such as dietary habits, family history, and lifestyle factors could not be evaluated due to incomplete records. Molecular and immunohistochemical analyses were not performed, which may have provided further insights into the biological behavior of different polyp subtypes. Despite these limitations, the study offers valuable clinicopathological data from a tertiary care setting.

Conclusion

Adenomatous polyps were the most common colorectal polyps and showed a significant association with dysplasia. Histopathological evaluation plays a pivotal role in identifying high-risk lesions and preventing progression to colorectal carcinoma.

References

1. Morson BC. Precancerous lesions of the colon and rectum. *JAMA*. 1962;179:316–321.
2. Winawer SJ, Zauber AG, Ho MN, et al. Prevention of colorectal cancer by colonoscopic polypectomy. *N Engl J Med*. 1993;329(27):1977–1981.
3. Fearon ER, Vogelstein B. A genetic model for colorectal tumorigenesis. *Cell*. 1990;61(5):759–767.
4. Levine JS, Ahnen DJ. Adenomatous polyps of the colon. *N Engl J Med*. 2006;355(24):2551–2557.
5. Konishi F, Morson BC. Pathological characteristics of colorectal adenomas. *Dis Colon Rectum*. 1990;33(6):419–423.
6. Torlakovic E, Snover DC. Serrated adenomatous polyposis in humans. *Am J Surg Pathol*. 1996;20(4):445–451.
7. Snover DC. Update on the serrated pathway to colorectal carcinoma. *Hum Pathol*. 2011;42(1):1–10.
8. Leggett B, Whitehall V. Role of the serrated pathway in colorectal cancer pathogenesis. *Gastroenterology*. 2010;138(6):2088–2100.
9. Strum WB. Colorectal adenomas. *N Engl J Med*. 2016;374(11):1065–1075.
10. Lieberman DA, Rex DK, Winawer SJ, et al. Guidelines for colonoscopy surveillance after screening and polypectomy. *Gastroenterology*. 2012;143(3):844–857.
11. Brenner H, Kloor M, Pox CP. Colorectal cancer. *Lancet*. 2014;383(9927):1490–1502.
12. Shinya H, Wolff WI. Morphology, anatomic distribution, and cancer potential of colonic polyps. *Cancer*. 1975;36(5):1855–1863.
13. Misra SP, Dwivedi M. Colonic polyps: Clinical, endoscopic, and histological spectrum in North India. *Indian J Gastroenterol*. 2004;23(1):7–10.
14. Goh HS, Ooi BS. Colorectal polyps in an Asian population. *Dis Colon Rectum*. 1995;38(4):337–342.
15. Fenoglio-Preiser CM, Noffsinger AE, Stemmermann GN, et al. *Gastrointestinal Pathology: An Atlas and Text*. 3rd ed. Philadelphia: Lippincott Williams & Wilkins; 2008.
16. Rex DK, Schoenfeld PS, Cohen J, et al. Quality indicators for colonoscopy. *Am J Gastroenterol*. 2015;110(1):72–90.
17. Williams AR, Balasooriya BA, Day DW. Polyps and cancer of the large bowel: A necropsy study. *Lancet*. 1982;1(8281):779–781.
18. Bond JH. Polyp guideline update: Diagnosis, treatment, and surveillance for patients with colorectal polyps. *Gastroenterology*. 2000;119(3):837–853.
19. Kim SE, Paik HY, Yoon H, et al. Sex- and gender-specific disparities in colorectal cancer risk. *World J Gastroenterol*. 2015;21(17):5166–5173.

20. Singh K, Goyal A, Mahajan NC, et al. Histopathological spectrum of colorectal polyps: A tertiary care study. *J Clin Diagn Res.* 2016;10(6):EC01–EC04.
21. Vatn MH, Stalsberg H. The prevalence of polyps of the large intestine in Oslo. *Scand J Gastroenterol.* 1982;17(7):819–825.
22. Burt RW. Colon cancer screening. *Gastroenterology.* 2000;119(3):837–853.
23. Vogelstein B, Fearon ER, Hamilton SR, et al. Genetic alterations during colorectal tumor development. *N Engl J Med.* 1988;319(9):525–532.
24. Lieberman D, Moravec M, Holub J, et al. Polyp size and advanced histology in patients undergoing colonoscopy. *Gastroenterology.* 2007;133(4):1077–1085.
25. East JE, Atkin WS, Bateman AC, et al. British Society of Gastroenterology position statement on serrated polyps. *Gut.* 2015;64(7):991–1000.