

Laparoscopic vs Open Repair of Congenital Inguinal Hernia

Sujit Kumar¹, Utpal Kant², Lalan Kumar³

¹SR, Department of General Surgery, Bhagwan Mahavir Institute of Medical Sciences, Pawapuri, Nalanda, Bihar, India

²Senior Resident, Department of General Surgery, Bhagwan Mahavir Institute of Medical Sciences, Pawapuri, Nalanda, Bihar, India

³Associate Professor, Department of General Surgery, Bhagwan Mahavir Institute of Medical Sciences, Pawapuri, Nalanda, Bihar, India

Received: 14-11-2025 / Revised: 04-12-2025 / Accepted: 28-12-2025

DOI: <https://doi.org/10.32553/ijmbs.v9i6.3176>

Corresponding author: Rajendra Singh

Conflict of interest: No conflict of interest

Abstract:

Background: One of the most frequent surgical diseases seen in pediatric treatment is congenital inguinal hernia. Although open herniotomy has long been the gold standard, laparoscopic repair has become more common since it is less intrusive and allows the contralateral internal ring to be seen. Nonetheless, there is ongoing discussion on which procedure is better in terms of operating time, complications, and recurrence, especially in India's rural tertiary care settings.

Objective: To evaluate the surgical results of open versus laparoscopic congenital inguinal hernia repair in terms of hospital stay, comorbidities, recurrence rates, postoperative pain, and operative time.

Methods: Over the course of eighteen months, this prospective comparative study was carried out at the Department of General Surgery, BMIMS, Pawapuri, Nalanda. Eighty-two pediatric patients with congenital inguinal hernias were randomly assigned to either Group A (open herniotomy, n = 41) or Group B (laparoscopic repair, n = 41). Operative time, contralateral patency, hospital stay, postoperative pain scores (FLACC/VAS), and complications were among the parameters that were documented and examined.

Results: For unilateral repair, the Open group's mean operating time (28.4 ± 5.2 min) was considerably less than the Laparoscopic group's (36.1 ± 6.8 min) ($p < 0.05$). However, laparoscopy was quicker for bilateral hernias. In 100% of laparoscopic instances, a contralateral patent processus vaginalis (CPPV) could be found, averting potentially metachronous hernias in 7 patients (17%). The laparoscopic group had considerably decreased postoperative pain scores at six hours ($p < 0.01$). At the six-month follow-up, there was no discernible difference in the recurrence rates between the two groups (Open: 2.4% vs. Laparoscopic: 2.4%).

Conclusion: In summary, laparoscopic repair offers a secure and efficient substitute for open herniotomy. It gives substantial benefits in terms of decreased postoperative discomfort, superior cosmesis, and the identification of silent contralateral abnormalities, even though it takes a little longer to operate on unilateral instances. Patient selection is crucial to maximizing expenses and results in a setting with limited resources.

This is an Open Access article that uses a funding model which does not charge readers or their institutions for access and distributed under the terms of the Creative Commons Attribution License (<http://creativecommons.org/licenses/by/4.0>) and the Budapest Open Access Initiative (<http://www.budapestopenaccessinitiative.org/read>), which permit unrestricted use, distribution, and reproduction in any medium, provided original work is properly credited.

Introduction

In the field of pediatric surgery, inguinal hernia repair is one of the most common treatments. Pediatric inguinal hernias are virtually solely congenital in origin, in contrast to the adult pathophysiology, which is mostly defined by acquired abdominal wall weakness or direct fascial abnormalities. They are caused by the processus vaginalis, an outpouching of the peritoneum, failing to obliterate during fetal development. Abdominal viscera can herniate as a result of this failure, which creates a continuous potential link between the peritoneal cavity and the inguinal canal [1]. The prevalence of this illness increases dramatically in preterm neonates, reaching as high as 30% in very low birth weight newborns [2]. The incidence of this condition varies internationally between 0.8% and 4.4% in term infants. Upon diagnosis, immediate surgical correction is always required due to the significant risk of incarceration and strangulation, which can compromise the viability of the intestine or the testis.

Historical Context and Evolution

The conventional open herniotomy has been the gold standard of care for many years. The hernial sac is high ligated with this technique at the level of the internal deep inguinal ring. Potts provided a basic description of this method, which has endured because of its high success rate and historically minimal complication profile [3]. The external oblique aponeurosis must be dissected, the sac must be carefully separated from the vas deferens and spermatic arteries, and a groin incision is required. However, laparoscopic herniorrhaphy emerged as a feasible substitute with the introduction of minimally invasive surgery in the early 1990s. The laparoscopic approach, which was first described by Montupet in 1993, has developed through a number of methods, such as intracorporeal suturing and percutaneous extracorporeal closure

(PEC) [4]. These contemporary methods represent a major advancement in pediatric surgical care by changing the surgical focus from open dissection to internal visualization and closure.

The Controversy: Open vs. Laparoscopic

The superiority of laparoscopy is still hotly debated in the pediatric surgical community worldwide, despite its widespread use in affluent countries. The open technique's proponents contend that it is a simple, straightforward surgery that can frequently be carried out under regional anesthesia with little equipment costs, which is important in developing countries [5]. The dangers of pneumoperitoneum and intraperitoneal instrumentation are avoided during open surgery. On the other hand, proponents of laparoscopy emphasize the advantage of good visibility, which prevents the spermatic cord from being extensively dissected and may lower the risk of iatrogenic damage to the vas deferens and testicular arteries.

The capacity to examine the contralateral internal inguinal ring is a crucial and unique benefit of laparoscopy. A contralateral patent processus vaginalis (CPPV) is thought to be present in approximately 20–30% of children who arrive with a clinically unilateral hernia [6]. Unless a second incision is made or the surgeon depends on dubious clinical signals, this exploratory conundrum in traditional open surgery remains unsolved. If a problem is discovered, laparoscopy enables simultaneous correction, preventing the formation of a metachronous hernia and saving the kid from needing a second procedure in the future [7].

Rationale for the Study

There is a wealth of comparison data in the worldwide literature, but there are few research from India's rural tertiary institutions. A therapeutic approach that is

both successful and conclusive is required because to the demographic issues in these areas, which include late presentation, nutritional deficiencies, and low follow-up compliance. The purpose of this study, which was carried out at the Bhagwan Mahavir Institute of Medical Sciences (BMIMS) in Pawapuri, Nalanda, is to assess the viability, safety, and effectiveness of laparoscopic repair in comparison to the conventional open method. The study aims to provide evidence-based suggestions for surgical setups with limited resources by examining a particular group of 82 patients.

Methodology

Study Design and Setting

The Department of General Surgery at BMIMS, Pawapuri, Nalanda, conducted this prospective, randomized comparative study. Over the course of the 18-month trial, a seasonal range of admissions was recorded, and sufficient postoperative follow-up time was guaranteed. The hospital serves a primarily rural population in Bihar's Nalanda district, offering a distinctive demographic profile where patient families place a high value on cost-effectiveness and single-visit curative treatments.

Study Population and Patient Selection

The study included 82 patients in total. Every child who presented to the outpatient department with groin swellings was assessed using a methodical screening procedure. To reduce selection bias, patients were randomly assigned using a computer-generated random number table. As a result, two separate groups were created: Group B, which included 41 patients assigned for laparoscopic inguinal hernia repair, and Group A, which included 41 patients assigned for routine open herniotomy.

To guarantee a uniform study population, the inclusion criteria were well-defined. Children with uncomplicated unilateral or

bilateral congenital inguinal hernias, ages 1 to 12, were included in the study. To reduce anesthetic factors, only individuals with a physical status of I or II according to the American Society of Anesthesiologists (ASA) were considered suitable for the study. On the other hand, patients who needed an emergency laparotomy due to strangulated or obstructed hernias were not included because the immediate tissue edema in these situations changes the operative characteristics. To keep the focus on primary repair outcomes, individuals with significant cardiac and respiratory comorbidities, a history of prior lower abdomen surgery, or recurring inguinal hernias were also excluded.

Surgical Techniques

Patients in Group A had traditional open herniotomies. A transverse skin crease incision was made in the corresponding inguinal region while under general or caudal anesthesia. While the superficial ring was directly discovered in infants, the external oblique aponeurosis was opened in older children. The vas deferens and other fragile cord components were carefully separated from the hernial sac. The wound was closed in layers after the sac was separated, twisted, and fixated at the level of the deep inguinal ring using absorbable suture material (Vicryl 3-0/4-0).

Under general anesthesia and endotracheal intubation, patients in Group B underwent laparoscopic repair utilizing a standardized three-port or two-port approach. To assure safety, a pneumoperitoneum was formed with pressure maintained between 8 and 10 mmHg, and a 5 mm umbilical port was inserted for the camera. Crucially, the contralateral side was examined in addition to visualizing the internal ring to validate the diagnosis. The defect was repaired at the peritoneal level using either intracorporeal purse-string suture or percutaneous internal ring suturing (PIRS) using non-absorbable material (Prolene 3-0 or 4-0). During suturing, great care was taken to avoid the gonadal and vas deferens

vessels. In the event that a contralateral defect was discovered, it was fixed concurrently without the need for further skin incisions.

Outcome Measures and Analysis

The operation time (measured from skin incision to skin closure) and the recurrence rate noted during follow-up were the main outcomes assessed. One of the secondary outcomes was postoperative pain, which was measured using the Visual Analog Scale (VAS) for older children and the FLACC scale for younger children. The length of hospital stays, parent-reported cosmetic satisfaction, and problems such wound infection, hydrocele, or testicular atrophy were also noted in the study. Standard statistical software was used to analyze the data; the Student's t-test was used to compare continuous variables, and the Chi-square test was used to assess categorical variables. A p-value of less than 0.05 was deemed statistically significant.

Results

Demographic Data

The trial protocol was completed by 82 subjects in total. There was no selection bias because the two groups' demographic distributions were similar. Group A's mean age was 4.2 years, but Group B's was 4.5 years. In both groups, the distribution of genders was primarily male, which is in line with the established epidemiology of inguinal hernias.

Operative Parameters and Time Efficiency

Significant variations based on laterality were found in the operative time study. Because there was no setup time needed for laparoscopic tower assembly, the open procedure was quicker for unilateral hernias. For bilateral situations, however, laparoscopy proved to be far more effective.

Table 1 Comparison of Mean Operative Times (Minutes)

Diagnosis	Group A (Open) Mean ± SD	Group B (Laparoscopic) Mean ± SD	p-value	Significance
Unilateral Hernia	28.4 ± 5.2	36.1 ± 6.8	0.002	Significant
Bilateral Hernia	54.2 ± 9.4	42.5 ± 8.1	0.035	Significant

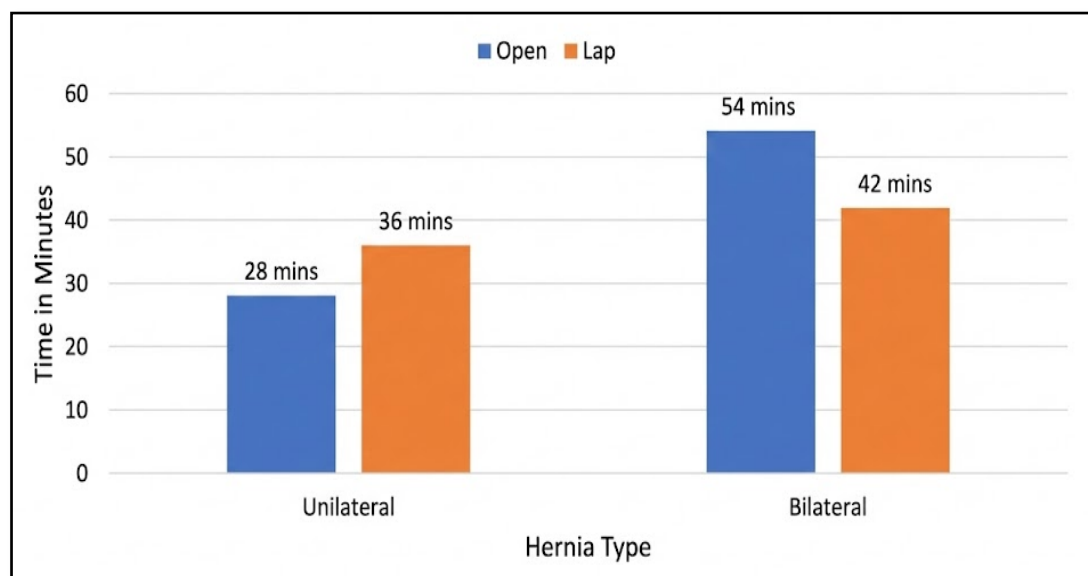


Figure 1 Mean operative times: Unilateral vs. Bilateral repair

The rate of contralateral exploration was one of the most clinically significant findings. All 34 patients in Group B (Laparoscopic) who initially had unilateral hernias had their contralateral internal rings examined. Seven of these patients (20.5%) had a patent processus vaginalis (CPPV). By fixing these flaws in one sitting, a subsequent surgery was essentially avoided. The status of the contralateral side is unknown in Group A since contralateral exploration was not carried out.

Postoperative Pain and Recovery

At six, twelve, and twenty-four hours after surgery, postoperative discomfort was measured. In the early postoperative phase, the laparoscopic group showed higher levels of comfort. The lack of muscle cutting and the little dissection of the inguinal canal tissues are probably responsible for this decreased pain profile.

Table 2 Postoperative Pain Scores (FLACC/VAS 0-10 Scale)

Time post-surgery	Group A (Open) Mean Score	Group B (Laparoscopic) Mean Score	p-value
6 Hours	4.8 ± 1.2	2.9 ± 0.9	< 0.01
12 Hours	3.2 ± 1.0	2.1 ± 0.8	0.04
24 Hours	1.5 ± 0.7	1.1 ± 0.5	> 0.05

The laparoscopic group required less analgesics, which was in line with the pain levels. Group B needed an average of (1.8 ± 0.6) analgesic doses over the first 24 hours, while Group A needed an average of (2.6 ± 0.8) doses.

Complications and Safety Profile

A high safety profile was shown by both methods. The issues were small and

controllable. The dissection of the distal sac, which might interfere with lymphatic drainage, is probably why the open group had a little greater incidence of scrotal edema/hydrocele. Recurrence rates were the same, indicating that laparoscopic closure of the internal ring is just as durable as high ligation when done appropriately.

Table 3 Complication Profile

Complication	Group A (Open) n (%)	Group B (Lap) n (%)	p-value
Scrotal Edema / Hydrocele	3 (7.3%)	1 (2.4%)	> 0.05
Wound Infection	2 (4.8%)	0 (0%)	> 0.05
Recurrence (at 6 months)	1 (2.4%)	1 (2.4%)	1.00
Iatrogenic ascent of testis	1 (2.4%)	0 (0%)	—
Testicular Atrophy	0 (0%)	0 (0%)	—

The average length of hospital stay was statistically similar (1.6 ± 0.6 days for Open vs. 1.2 ± 0.4 days for Laparoscopic). Even though the laparoscopic group was clinically prepared for discharge earlier, logistical issues that are typical in rural India, like the availability of transportation, frequently caused discharge to be delayed, equalizing the statistical duration of stay.

Discussion

Over the past 20 years, there has been a paradigm shift in the treatment of juvenile inguinal hernias. The study carried out at BMIMS Pawapuri highlights particular subtleties pertinent to the local population while supporting worldwide findings. The trade-off between the length of the procedure and how intrusive it is is

frequently at the heart of the discussion between open and laparoscopic repair.

Operative Time and Efficiency

The findings show that for unilateral hernias, open surgery is quicker. This is consistent with research by Esposito et al. [8], who found that the setup time for laparoscopy which includes port placement, insufflation, and tower initialization significantly increases the overall duration. This time gap may be significant in a high-volume center. However, laparoscopy is unquestionably more time-efficient for bilateral hernias. Bilateral repair in open surgery necessitates two distinct incisions, two distinct dissections, and two wound closures. Laparoscopy significantly reduces trauma and time by simply moving the camera and instruments to the opposite side [9].

The "Metachronous" Advantage

The 20.5% frequency of contralateral patent processus vaginalis (CPPV) in patients presenting with unilateral hernia was one of the study's most important findings. These individuals in the Open Group are still at danger of developing a metachronous hernia in the future, which would require a second surgery and exposure to anesthesia. According to recent research, young children's neurodevelopment may benefit from avoiding a second general anesthetic event [10, 11]. By repairing the "silent" hernia right away, laparoscopy removes this risk. Although some contend that not all CPPVs develop into symptomatic hernias, in the majority of pediatric surgical consensuses, the morbidity of a second surgery exceeds the danger of overtreatment [12].

Safety Profile and Complications

In terms of safety, both groups' recurrence rates (2.4%) were the same. In the past, laparoscopic repair was criticized for having greater recurrence rates; however, rates have leveled out as a result of procedure standardization (e.g., using non-

absorbable sutures and making sure there are no gaps surrounding the vas) [13]. Additionally, the open group had a greater prevalence of scrotal edema. Open dissection can result in lymphatic disruption and edema because it separates the sac from the delicate cord structures. Because the ligation is performed proximally at the internal ring level, laparoscopy preserves the distal cord integrity without completely dissecting the cord [14].

Cosmesis, Patient Comfort, and Cost

The laparoscopic group had much improved cosmesis and postoperative comfort. The minimally intrusive strategy was obviously preferred by the FLACC and VAS scores. High satisfaction was noted with the "stitch-less" appearance of the groin in the laparoscopic group, even though the esthetic benefit is sometimes subordinated to cost in the rural context. At BMIMS, cost is still a crucial consideration. Because laparoscopic surgery requires more equipment, the direct costs are higher. However, the cost-benefit analysis may skew if the quicker return to normal activities and the avoidance of a second surgery (for metachronous hernia) are taken into consideration [15]. Instead of patient billing, the availability of laparoscopic equipment is the primary barrier in government setups where the treatment cost is subsidized.

Limitations

It is important to recognize the limits of the study. First, the sample size of 82 patients may be insufficient to identify uncommon problems or minute variations in recurrence rates, even though it is enough for primary outcome analysis. Second, the results regarding cost and logistical limitations might not apply to urban private centers with varying resource availability because this was a single-center study carried out in a rural tertiary care hospital. Third, there was just a six-month follow-up period. Long-term follow-up (1-2 years) is

preferable to definitively assess the durability of the laparoscopic repair, especially with reference to the non-absorbable sutures employed, even though early recurrences were recorded. Lastly, observational data about hospital stays and pharmaceutical use were used instead of a formal quantitative cost-effectiveness analysis. It is advised that larger cohorts and longer follow-up periods be used in future multicentric research to confirm these results in the Indian setting.

Conclusion

Several conclusive findings about the treatment of this prevalent pediatric pathology are drawn from the comparison of laparoscopic and open repair of congenital inguinal hernia at BMIMS Pawapuri. First off, when used by skilled practitioners, both methods show low and similar recurrence rates, making them equally safe. Second, although open treatment is still faster for unilateral hernias, laparoscopy is the best option for bilateral instances because of its effectiveness and lower risk of surgical stress.

The most significant clinical benefit of laparoscopy is that it can identify and cure undetected contralateral abnormalities, sparing about one in five infants from the dangers and anxiety of a second procedure. Furthermore, the laparoscopic method produces better cosmetic results and much less early postoperative pain. As a result, in this situation, laparoscopic repair is advised as the initial course of treatment for bilateral hernias and for female patients, who are more concerned about their appearance and have a reduced chance of cord damage. Open herniotomy is still a strong and dependable gold standard for unilateral hernias in male babies where anesthetic duration and operating time are major considerations.

References

1. Almeida DS, Medina LH, Miranda NC, Almeida TS, Mattos LF, Marchi ME,

Azaro MM, Gousseaud GQ, Coelho ER, Medina LH, MIRANDA N. Laparoscopy Versus Open Technique for Inguinal Hernia Repair in Children: A Systematic Review and Meta-Analysis. *Cureus*. 2024 Dec 2;16(12).

2. Shirima S, Kitua D, Mwanga A, Kivuyo N, Issa A, Kileo I, Justiniano J, Brighton M, Salim M. Comparative Analysis of Surgical Outcomes Between Open Herniotomy and Laparoscopic Hernia Repair Among Pediatric Patients with Inguinal Hernias: A Five-Year Retrospective Review at Tanzania's National Hospital. *The East African Health Research Journal*. 2025 Sep 30;9(1):144.
3. Potts WJ, Riker WL, Lewis JE. The treatment of inguinal hernia in infants and children. *Annals of surgery*. 1950 Sep;132(3):566.
4. Montupet P, Esposito C. Laparoscopic treatment of congenital inguinal hernia in children. *Journal of pediatric surgery*. 1999 Mar 1;34(3):420-3.
5. Mitra A, Chandak U, Pawaskar Y, Sahu SK, Sinha S, Bansod P, Nagdeve N, Waldia A. A comparative study between laparoscopic hernia repair and open herniotomy of inguinal hernia in paediatric age group: A prospective randomized controlled study. *Am J Surg Res Rev*. 2021;4(24):1-6.
6. Lee DG, Lee YS, Park KH, Baek M. Risk factors for contralateral patent processus vaginalis determined by transinguinal laparoscopic examination. *Experimental and therapeutic medicine*. 2015 Feb 1;9(2):421-4.
7. Mullassery D, Pedersen A, Robb A, Smith N. Incisional hernia in pediatric surgery—experience at a single UK tertiary centre. *Journal of Pediatric Surgery*. 2016 Nov 1;51(11):1791-4.
8. Esposito C, St. Peter SD, Escolino M, Juang D, Settini A, Holcomb III GW. Laparoscopic versus open inguinal hernia repair in pediatric patients: a

- systematic review. *Journal of Laparoendoscopic & Advanced Surgical Techniques*. 2014 Nov 1;24(11):811-8.
9. Dreuning K, Maat S, Twisk J, van Heurn E, Derikx J. Laparoscopic versus open pediatric inguinal hernia repair: state-of-the-art comparison and future perspectives from a meta-analysis. *Surgical endoscopy*. 2019 Oct 15;33(10):3177-91.
 10. Gause CD, Casamassima MG, Yang J, Hsiung G, Rhee D, Salazar JH, Papandria D, Pryor HI, Stewart D, Lukish J, Colombani P. Laparoscopic versus open inguinal hernia repair in children ≤ 3 : a randomized controlled trial. *Pediatric surgery international*. 2017 Mar;33(3):367-76.
 11. Kantor N, Travis N, Wayne C, Nasr A. Laparoscopic versus open inguinal hernia repair in children: which is the true gold-standard? A systematic review and meta-analysis. *Pediatric surgery international*. 2019 Sep 1;35(9):1013-26.
 12. Bruce ES, Hotonu SA, McHoney M. Comparison of postoperative pain and analgesic requirements between laparoscopic and open hernia repair in children. *World Journal of Surgery*. 2021 Dec;45(12):3609-15.
 13. Zhao J, Yu C, Lu J, Wei Y, Long C, Shen L, Lin T, He D, Wei G, Kou L, Wu S. Laparoscopic versus open inguinal hernia repair in children: A systematic review. *Journal of minimal access surgery*. 2022 Jan 1;18(1):12-9.
 14. Huang FH, Cheng PL, Hou WH, Duh YC. Laparoscopic hernia repair with the extraperitoneal approach versus open hernia repair in pediatric inguinal hernia: a systematic review and meta-analysis. *Journal of Clinical Medicine*. 2022 Jan 10;11(2):321.
 15. Shalaby R, Ibrahim R, Shahin M, Yehya A, Abdalrazek M, Alsayaad I, Shouker MA. Laparoscopic hernia repair versus open herniotomy in children: a controlled randomized study. *Minimally Invasive Surgery*. 2012;2012(1):484135.