

Pink and Blue of Bones- A Histopathological Analysis of Bony Neoplasm in a Tertiary Hospital of Bihar

Aishwarya Krishna¹, Pallavi Mehra², Sneha Aditi³, Dilip Kumar⁴

¹Junior Resident, Department of Pathology, Patna Medical College and Hospital, Patna, Bihar, India

²Assistant Professor, Department of Pathology, Patna Medical College and Hospital, Patna, Bihar, India

³Senior Resident, Department of Pathology, Patna Medical College and Hospital, Patna, Bihar, India

⁴Professor, Department of Pathology, Patna Medical College and Hospital, Patna, Bihar, India

Received: 17-04-2024 / Revised 16-05-2024 / Accepted 12-06-2024

Corresponding author: Sneha Aditi

DOI: <https://doi.org/10.32553/ijmbs.v8i3.2812>

Conflict of interest: Nil

Abstract:

Background: Bone lesions have low incidence with diverse presentation and due to the presence of their limited studies it has become a challenging task to reach an accurate diagnosis.

Aim and Objective: This study aims in studying variety of bony lesions observed clinically and histopathologically. Further categorizing into non neoplastic, tumour-like, benign tumour or malignant tumour and determining its correlation with the age and gender predisposition of these lesions.

Materials and Methods: An ambispective study was executed in Pathology department , PMCH, Patna from May 2020 to April 2024 in which a total of 102 cases were collected. The necessary information for the retrospective analysis, such as the patient's age, sex, lesion location, and diagnosis, was obtained from the requisition form and the histopathology data kept in the department of pathology from May 2020 to May 2022.

And for prospective study all the radiological proven bony lesions which were excised during period of May 2022 to April 2024 and were sent for histopathological examination were examined.

Results: Non-neoplastic lesions were more common than neoplastic lesions among the 102 specimens that underwent histological examination (53 versus 49). With 21.5% of cases, tuberculous osteomyelitis was the most prevalent non-neoplastic lesion. The most common benign neoplastic lesion detected was a giant cell tumor of the bone (11.76%), while the most common malignant lesion found was osteosarcoma (2.94%).

Conclusion: To improve patient management and diagnosis accuracy, it is advised to utilize clinical, radiological, and histological findings in an integrated manner.

This is an Open Access article that uses a funding model which does not charge readers or their institutions for access and distributed under the terms of the Creative Commons Attribution License (<http://creativecommons.org/licenses/by/4.0>) and the Budapest Open Access Initiative (<http://www.budapestopenaccessinitiative.org/read>), which permit unrestricted use, distribution, and reproduction in any medium, provided original work is properly credited.

Introduction

The dynamic heterogeneous tissue that is bone is made up of are cartilaginous, osteoid, fibrous, and bone marrow

components. These components can result in a variety of pathological lesions, ranging from neoplastic illnesses to degenerative

alterations, inflammation, and metabolic diseases.[1]

Bone tumors account for only 0.5% of all cancer cases worldwide, making them comparatively rare. [1] The majority of bone neoplasms are categorized as either benign or malignant by the WHO. Some neoplasms have borderline and intermediate characteristics, despite the clear demarcation between these two categories.

Bone lesions exhibit a spectrum of characteristics, from non-harmful to swiftly lethal, in terms of their clinical, radiological, and morphological properties. To establish a diagnosis, the patient's age, gender, and lesion site are required. Certain benign diseases, such as osteomyelitis, can mimic cancerous tumours whereas myeloma which is a malignant tumour mimics benign aetiology.

Accurate Diagnosis requires a systematic and an Integrated approach involving histopathological, Radiological and clinical features.

Material and Methods:

An ambispective investigation of all bone lesions was carried out under the histopathology section of the Department of Pathology of Patna Medical College and Hospital. from May 2020 to April 2024. 102 cases in total, regardless of the participants' sex or age, were gathered.

Age, sex, lesion site, diagnosis, and other relevant details for each patient were obtained for the retrospective study from the department's histopathology report and requisition form. Every slide that had been stained with hematoxylin and eosin (H and E) was reexamined, the tissue was visually inspected, and fresh slices were obtained whenever needed.

Radiologically confirmed bone lesions treated by open biopsy, curettage, or amputation and subjected to standard tissue processing were included in the prospective analysis. First, 10% formalin was used to fix the tissue, and then 5% nitric acid was used to decalcify the removed bone sections. The paraffin block was prepared. H and E were used to stain them for microscopic inspection.

Based on the diagnosis, the bony lesions were classified as benign, malignant, tumor-like, or non-neoplastic. Prior to their inclusion in the trial, all patients provided their informed permission.

Results:

A histological analysis was conducted on 102 instances with different types of bone lesions. They were divided as benign, malignant, tumor-like, and non-neoplastic lesions. [Table 1]

Table 1: Showing categorization of bony lesions into non neoplastic, tumour like, benign neoplasm and malignant neoplasm.

Non neoplastic lesions	Tumour like lesions	Benign neoplasm	Malignant neoplasm
Tubercular osteomyelitis [22]	Simple bone cyst [2]	Giant cell tumour [12]	Osteosarcoma [3]
Chronic Osteomyelitis [16]	Aneurysmal bone cyst [7]	Osteochondroma [9]	Chondrosarcoma [1]
Acute/chronic inflammation [12]	Fibrous dysplasia [1]	Enchondroma [5]	Ewing's sarcoma [1]
Synovitis [1]	Non ossifying Fibroma [2]	Osteoblastoma [1]	Plasmacytoma [1]
Crystal deposition disease [2]	Chondromyxoid fibroma [1]	Haemangioma [1]	Metastases [2]
Total =53	N= 13	N=28	N= 8

Fifty-three instances (51.9%) had non-neoplastic lesions identified. Lesions in the neoplastic bone explained of the 49 cases (48 %), 8 cases (0.78%) were malignant and 41

instances (40.1 %) were benign. The younger population, specifically those in the age range of 21 to 30 years, is more susceptible to bone lesions. [Table 2]

Table 2: Lesions in bone and its presentation with age.

Age	Non neoplastic	Benign	Malignant
<25	15	10	2
25-35	12	20	1
35-45	6	5	2
45-55	15	5	2
>55	5	1	1

Table 3: Sex predilection and various bony lesion.

	Non neoplastic	Benign	Malignant
Male	33	24	6
Female	20	17	2

With a male-to-female ratio of 1.6:1, they are more common in males (61.76%) than in females (38.23%) [Table 3].

The most frequent non-neoplastic lesion was tuberculous osteomyelitis (21.5%), which was followed by chronic osteomyelitis (15.68%). Aneurysmal bone cysts accounted for 6.86% of all tumor-like lesions.

The most frequent bone lesions of benign neoplastic genesis were giant cell tumors (11.76%), which were followed by osteochondroma (8.82%). It was discovered that primary bone cancers (5.88%) were more common than metastatic lesions (1.96%).

Tumour like conditions

Non-ossifying fibroma

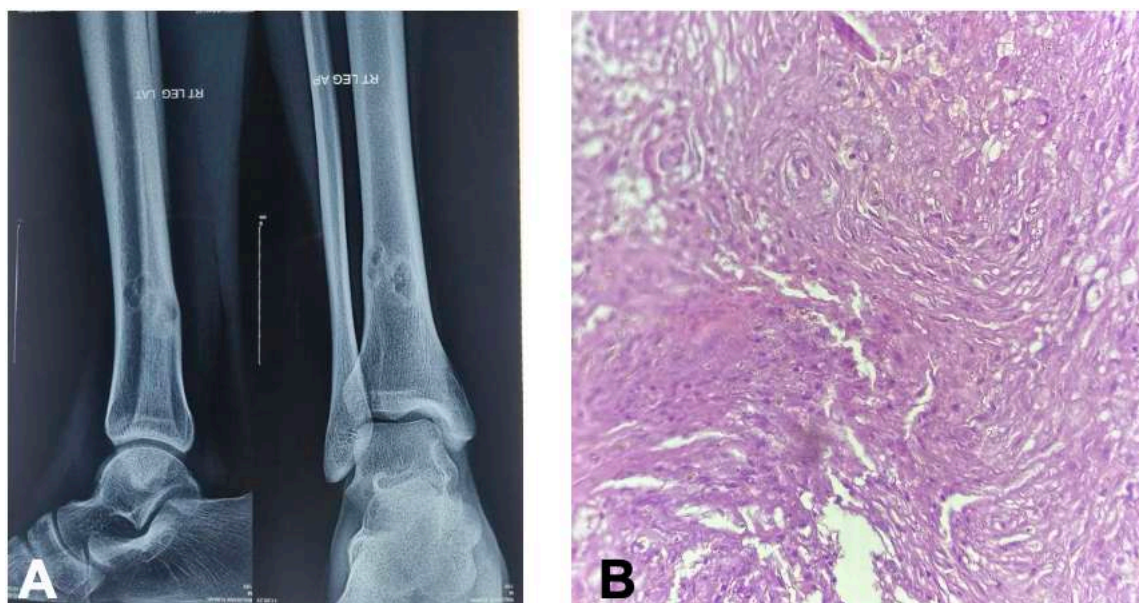


Figure 1: (A)X-ray- shows multiple lytic lesions in the diaphysis of distal end of right tibia. (B) H&E – 20x – shows spindle shaped fibroblasts arranged in storiform pattern

Fibrous dysplasia

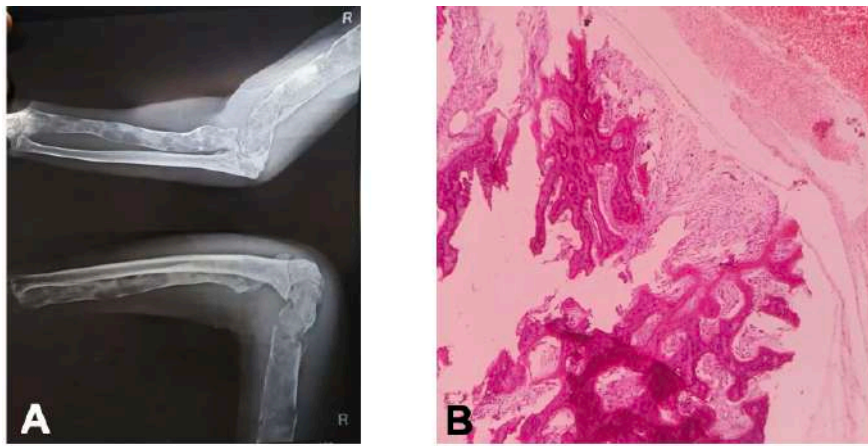


Figure 2: (A) X-ray- shows multiple well circumscribed intramedullary lesion with a sclerotic rim in the diaphysis of right humerus. (B) H&E - 20x – shows Chinese letter pattern of intervening fibrous stroma containing bland spindle cells.

Benign neoplastic lesions

Giant cell tumour

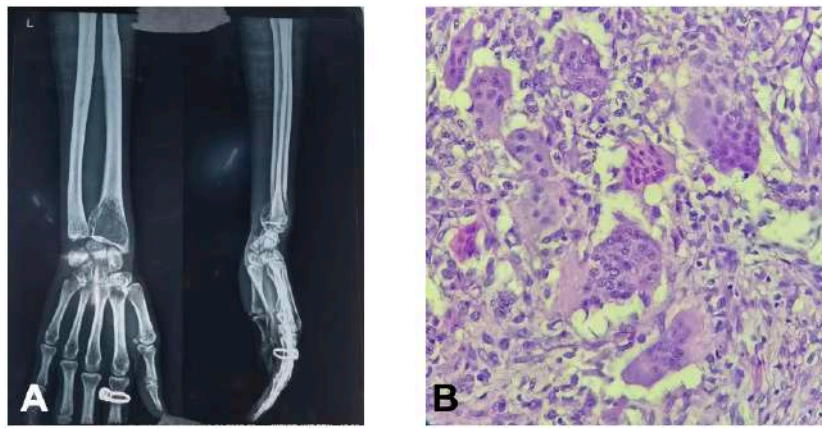


Figure 3: (A) X-ray - showing lytic lesion arising from epiphysis of distal radius of left forearm. (B) H&E - 40x – shows multinucleated giant cells in neoplastic stroma.

Enchondroma

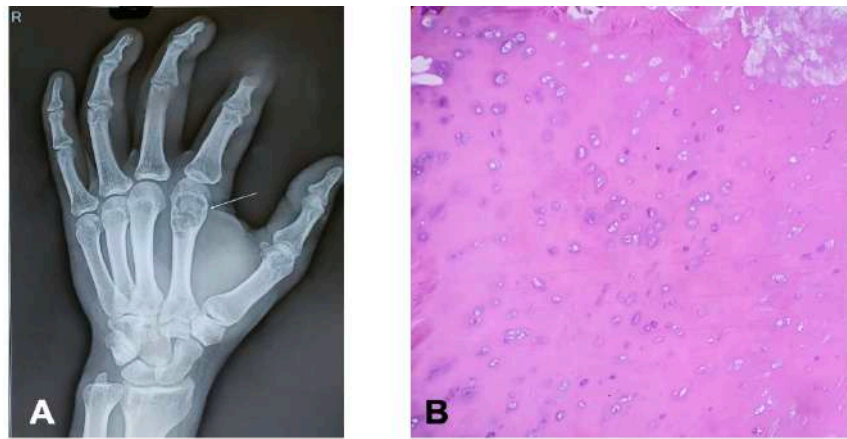


Figure 4: (A) X-ray - shows lytic lesion in the metaphysis of distal end of second metacarpal of right hand. (B) H&E - 20x – shows tumour cells in hyaline cartilage matrix.

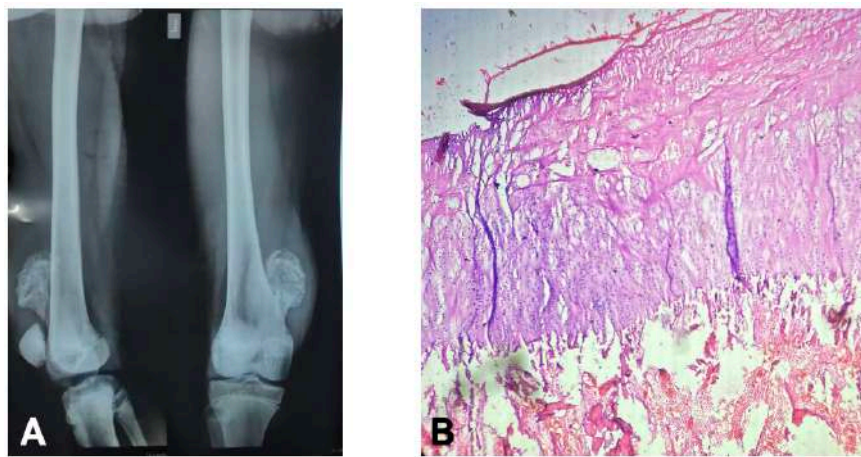

Figure 5: (A) X-ray - shows pedunculated exophytic lesion arising from the metaphysis of the medial side of distal end of left femur. (B) H&E - 20x – shows mature hyaline cartilage cap overlying bone.

Primary malignant lesions

Osteosarcoma

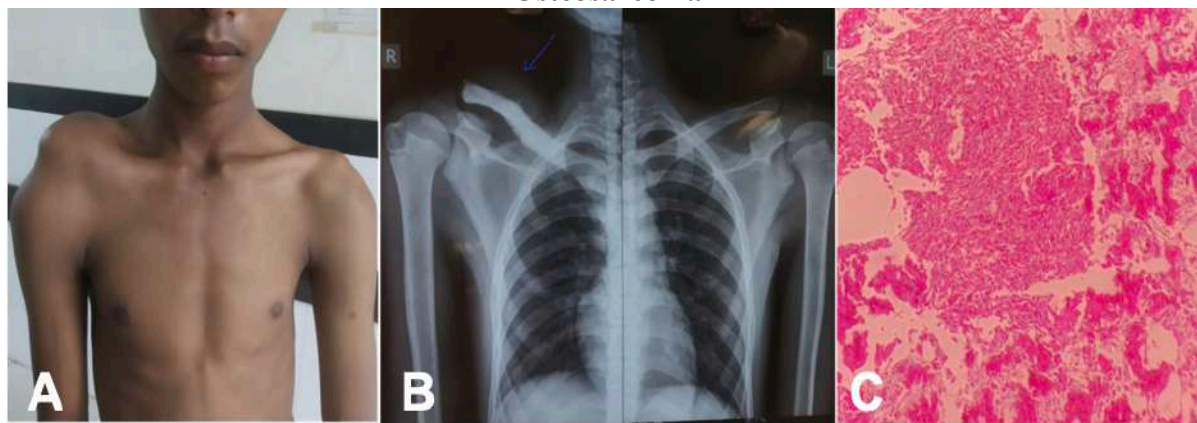


Figure 6: (A) Clinical picture - shows swelling over right shoulder. (B) X-ray - shows periosteal reaction over lateral end of right clavicle. (C) H&E- 20x - shows malignant spindle cells with significant atypia and pleomorphism producing lace like woven bone.

Chondrosarcoma

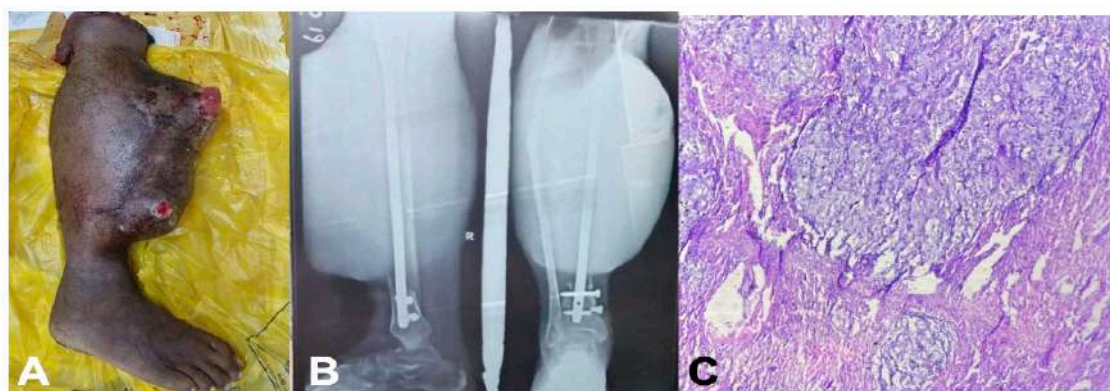


Figure 7: (A) Gross - shows amputated right leg with an enlarged mass forming nodules and ulcerations over skin. (B) X-ray - shows cortical destruction of the right tibia along with soft tissue involvement. (C) H&E - 20x – shows atypical chondrocytes in malignant hyaline matrix with myxoid change.

Metastatic lesions

One mets from invasive ductal carcinoma right breast subsequent immuno-
hisochemical markers were applied for confirmation

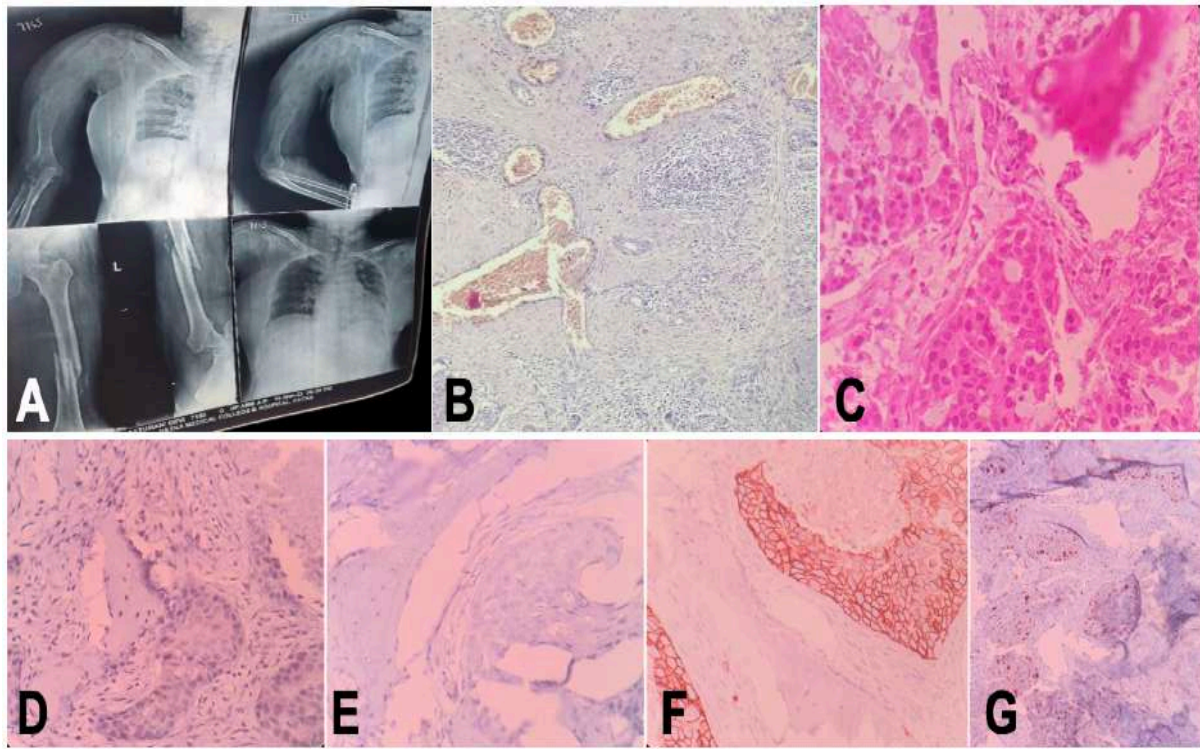


Figure 8: (A) X-ray - shows multiple lytic lesions in the right humerus causing pathological fracture. (B) H&E - 20x - shows malignant ductal cells surrounding the bony trabeculae. (C) H&E - 40x shows malignant ductal cells arranged in a cribriform pattern. (D) IHC 20x- ER -ve. (E) IHC 20x- PR -ve. (F) IHC 20x- Her2 +ve. (G) IHC 20x- Ki67 - 70%.

Bone metastasis from multiple myeloma

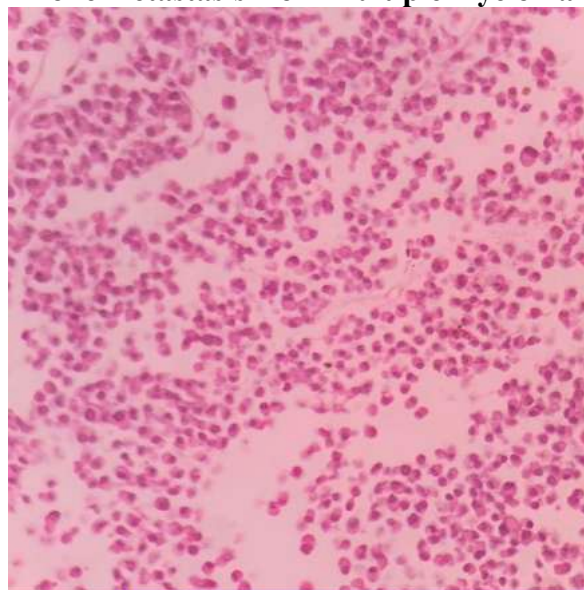


Figure 9: H&E - 20x - shows plasma cell infiltration of bone marrow in Myeloma

Discussion

This investigation was carefully conducted to identify various bone lesions. Of the 102 cases of bone lesions in our study, 53 cases (or non-neoplastic lesions) were the most common type. In our investigation, we observed 13 cases of tumor-like lesions, 28 cases of benign bone tumors, and 8 cases of malignant bone lesions.

A male to female ratio of 1.6:1 was observed in the majority of bone lesions, which is consistent with findings from studies by Karia et al., Manjani S et al., Rani R et al., and Modi D et al. (1-4). In our study, the second and third decades of life were the age group when the incidence of different bone lesions peaked. Other studies that looked at age incidence also found similar results.[1-6]

Non-neoplastic bone lesions accounted for the majority of cases (51.9%). This result was consistent with prior research conducted by Modi D et al. [4] In our analysis, the most frequent non-neoplastic lesion was tubercular osteomyelitis (21.5%), which was followed by acute/chronic osteomyelitis (15.6%), in line with studies by Patel et al. and Rafiq et al.[9,13] .

According to certain research, chronic osteomyelitis is more common than tubercular osteomyelitis. [5]. Research by Karia, KM, and others. revealed that osteomyelitis was the most prevalent condition, followed by inflammatory lesions [1].

Aneurysmal bone cysts were the most prevalent type of tumour-like lesion. Our study's proportion of tumor-like lesions, 12.7%, is comparable to that of a study conducted by Gayathri T. Et al. (11.3%). [6]

According to other studies, benign tumors were more common than malignant ones. [1]. The most frequent benign bone neoplasm in our sample was a giant cell tumor(11.7%), which is consistent with previous research [4,5]. The most frequent benign tumor of the bone is a giant cell tumor. Patients over 20 years old with a majority

of females are typically affected. The epiphysis of the long bone is the conventional site; from there, it can expand to the metaphyseal area, invade the intermuscular septa, rupture through the cortex, or even cross a joint space. According to studies by Sharma and Mehta [1,15] and Karia KM et al., osteochondroma was the second most common. The results of Patel et al.'s study, states osteochondroma was the most prevalent benign neoplasm followed by giant cell tumor.

In the present study, which is consistent with other studies [4,5], primary malignant bone tumors were more common than metastatic tumors; in contrast, metastases in the bone were more frequently detected in studies conducted by Karia KM [1]. The fact that our analysis was based on a limited number of cases could be the most plausible explanation. The most prevalent malignant tumor (2.94%) was osteosarcoma. Other trials with osteosarcoma frequencies ranging from 9.1% to 35.14% revealed similar findings.[12] The occurrence of osteosarcoma has two peak incidences. One peak occurs between the ages of 10 and 25, while the other occurs beyond 40. Ewing's sarcoma, plasmacytoma, and chondrosarcoma were among the other primary malignant tumors.

In our study, metastatic bone tumors were observed in the older age group (above 50 years). Similar results with an average age of 50 were found in a study by George M. Et al. [5]. Similar to a study by Karia KM et al., we found that metastatic bone lesions were more common in the female group in our study. [1] while metastatic tumor deposits shown a preference for men in the study of Rafiq and Tanwani [9].

Conclusion:

Bone lesion histopathological examination is regarded as an intricate field of pathology. Our study's findings were contrasted with numerous other similar investigations carried out by various authors. A broad range of bone abnormalities exist, and

certain tumors have a preference for particular ages, sexes, and sites, all of which are consistent with our analysis based on the data we evaluated. Due to the low occurrence of these lesions, there is little experience in treating them, which makes diagnosis more challenging. Consequently, it is advised to employ clinical, radiographic, and histological findings in concert to improve patient management and diagnosis accuracy.

References:

1. Karia KM, Iqbal MB, Patil AA, Agrawal NS, Kumar H. Study to correlate The histopathological spectrum of bone lesions with Demographic profile of patients in a tertiary care Institution. *Clin Cancer Investig J* 2017;6:254-7.
2. Manjani S et al (2021). Histopathological Spectrum of Bone Lesions in a Tertiary Care Hospital. *Saudi J Pathol 5 Microbiol*, 6(1), 5-7.
3. Rani R, Gupta I, Suri J. Histopathological Study of Bone Tumours- 4 Years Study in A Tertiary Care Centre. *JK Science* 2022;24(4):243-248
4. Modi D, Rathod GB, Delwadia KN, Goswami HM. Histopathological study Of bone lesions – A review of 102 cases. *IAIM*, 2016; 3(4): 27-36.
5. George Mathew and Shwetha Jose (2017) ‘Histopathological Study of Bone Lesions’, *International Journal of Current Advanced Research*, 06(09), pp. 6330-6333. DOI: <http://dx.doi.org/10.24327/ijcar.2017.6333.0920>
6. Gayathri T., Shashikala V., Rekha S, Spectrum of tumour and tumour-like lesions of bone in a Tertiary Care Hospital in North Karnataka, India. *Indian J Pathol Oncol* 2018;5(1):75-80
7. Choudhary, Kavita & Singh, Ankit & Singh, Kaustubh. (2022). Histopathological Spectrum of Neoplastic and Nonneoplastic Bone Lesions. *International Journal of Medical and Biomedical Studies*. 6. 10.32553/ijmbs.v6i5.2555.
8. Rhutso Y, Laishram RS, Sharma LD, Debnath K. Histopathological evaluation of bone tumors In a tertiary care hospital in Manipur, India. *J Med Soc* 2013;27:135-9.
9. Rafiq M, Tanwani AK. Spectrum of bone lesions at Pakistan Institute of medical sciences. *J Islamabad Med Dent Coll* 2012;2:69-71.
10. Sirikulchayanonta V, Klongwansayawan S. Metastatic Bone tumors in Ramathibodi Hospital, Thailand. *J Med Assoc Thai* 1992; 75 Suppl 1:131-5.
11. Settakom J, Lekawanvijit S, Arpornchayanon O, Rangaeng S, Vanitanakom P, Kongkarnka S, et al. Spectrum of bone tumors in Chiang Mai University Hospital, Thailand according to WHO Classification 2002: A study of 1,001 cases. *J Med Assoc Thai* 2006;89:780-7.
12. Negash BE, Admasie D, Wamisho BL, Tinsay MW. Bone tumors at Addis Ababa University, Ethopia: Agreement between radiological and histopathological Diagnosis- a 5-year analysis at Black-Lion Teaching Hospital. *Malawi Med J* 2009; 1:62-5.
13. Patel D, Patel P, Gandhi T, Patel N, Patwa J. Clinicopathological Study of bone lesions in tertiary care center – A review of 80 cases. *IJAR* 2015;3:1267-72.
14. Hathila RN, Mehta JR, Jha BM, Saini PK, Dudhat RB, Shah MB. Analysis of bone lesions in tertiary care Center – A review of 79 cases. *Int J Med Sci Public Health* 2013;2:1037-40.
15. Sharma S, Mehta NP. Histopathological study of bone tumors. *IJSR* 2015;4:1970-2.