

Unilateral Duplication of Renal Vessels: Exploring Anatomical, Clinical, and Surgical Insights

Ujwala Bhanarkar^{1*}, Amit Kumar Pal², Biswabina Ray³

^{1,2} Assistant Professor, Department of Anatomy, AIIMS, Kalyani, West Bengal, India

³Dean Research and Professor and Head, Department of Anatomy, AIIMS, Kalyani, West Bengal, India

Received: 14-06-2024 / Revised 16-06-2024 / Accepted 25-06-2024

Corresponding author: Dr. Ujwala Bhanarkar

DOI: <https://doi.org/10.32553/ijmbs.v8i3.2805>

Conflict of interest: Nil

Abstract:

The classic description of renal vascularization typically refers to a renal artery and vein. Nevertheless, this vascular configuration exhibits numerous anatomical variations in terms of their number, origin, and course, primarily attributable to ontogenetic alterations. While performing standard abdominal dissections for medical students, we examined the kidneys and their vasculature observing variations in the morphological arrangements of the right renal artery and renal vein. This case report aims to shed light on these variations, thereby enhancing clinicians' awareness of the intricate blood supply to the kidney. Understanding the diverse patterns of renal artery variations holds significance for urologists, radiologists, and surgeons alike. Such insights can prove invaluable for practitioners engaged in invasive procedures and vascular surgeries.

Keywords: renal artery, renal vein, vascular variation, anatomical variants, renal surgery

This is an Open Access article that uses a funding model which does not charge readers or their institutions for access and distributed under the terms of the Creative Commons Attribution License (<http://creativecommons.org/licenses/by/4.0>) and the Budapest Open Access Initiative (<http://www.budapestopenaccessinitiative.org/read>), which permit unrestricted use, distribution, and reproduction in any medium, provided original work is properly credited.

1. Introduction

In traditional anatomical terms, the renal vasculature typically comprises a renal artery branching from the abdominal aorta and a renal vein tributary to the inferior vena cava [1]. A sole renal artery, originating from the paired lateral branches of the abdominal aorta, at the level of the intervertebral disc between L1 and L2, just below the inception of the superior mesenteric artery provides blood to each kidney. As it approaches the kidney's hilum, this artery splits into anterior and posterior branches, further branching into segmental arteries that nourish distinct renal segments. Conversely, renal venous return is tasked with draining blood from venous branches, which correspond to the

arteries of both kidneys, into the inferior vena cava, ultimately emptying at approximately the level of the second lumbar vertebra.

Nevertheless, this described vascular pattern exhibits numerous anatomical variations concerning their number, origin, and course. It is estimated that variations in renal arteries are encountered in approximately 35% of cases, whereas alterations in renal veins, though less common, occur in about 18% of observed cases [2, 3].

2. Case Report

During routine dissection of the abdomen and pelvis for medical students in the 64-

year-old female cadaver at the Department of Anatomy, All India Institute of Medical Sciences, Kalyani, West Bengal, India, it was observed that there was variation in the renal vasculature of the right kidney. The renal vessels were dissected carefully and cleaned and photographs were taken for illustrations.

2.1 Variations found in the right renal artery

The right kidney was supplied by two renal arteries instead of one in this case. The female cadaver exhibited unilateral double renal arteries, each with comparable sizes, which were identified as superior and inferior renal arteries. The superior renal artery emerged from the abdominal aorta inferior to the level of origin of the superior mesenteric artery. This artery is ramified into an extra two divisions 2.5 cm before entering into the kidney. The anterior superior division of the right superior renal artery referred to as the upper polar branch entered the upper pole of the kidney whereas the posterior inferior division of the right superior renal artery referred to as the hilar branch entered the hilum of the kidney posterior to the lower hilar division of the renal vein and anterior to the renal pelvis. The right inferior renal artery which

arose 10 cm below the origin of the right superior renal artery from the abdominal aorta continued undivided and entered the lower pole of the right kidney posterior to the ureter along with the lower renal vein.

2.2 Variations found in the right renal vein

The right kidney in this case was drained by three renal veins into the inferior vena cava. The superior renal vein arising from the superior border of the hilum was crossed anteriorly by the hilar branch of the right superior renal artery. The middle renal vein arising from the lower border of the hilum of the right kidney runs in the upward direction to make an acute angle with the superior renal vein, joins with it and finally drains into the inferior vena cava. From anterior to posterior the middle renal vein, hilar branch of the superior renal artery and renal pelvis are the relations of the structures present in the hilum of the right kidney. The inferior renal vein arising from the lower pole of the right kidney postero superiorly to the inferior division of the renal artery traverses horizontally to drain in the inferior vena cava. The inferior renal vein is crossed anteriorly by the ureter. Hence duplication of renal veins is found in the present case.

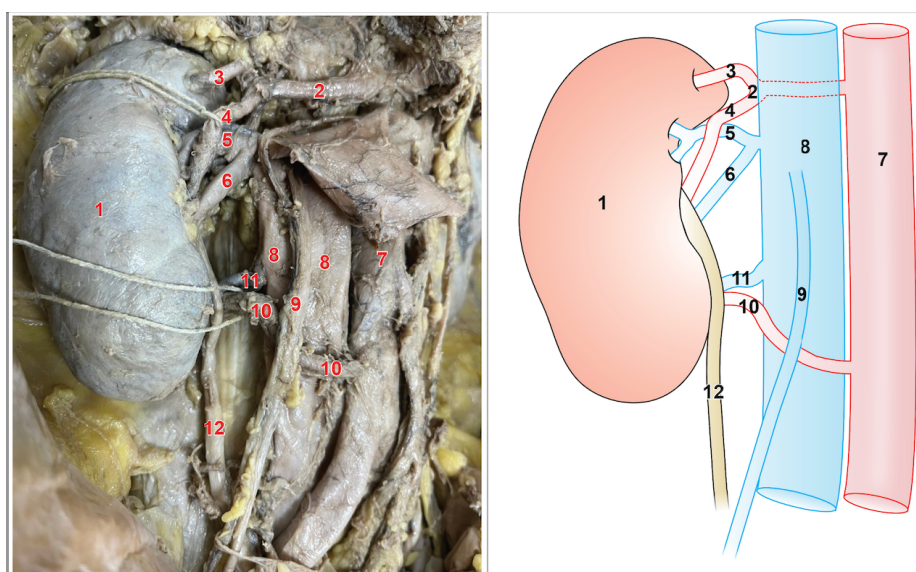


Figure 1: Variations of renal artery and renal vein in right kidney (Schematic representation on right side 1-Right kidney, 2-Superior renal artery, 3-Upper polar branch of superior renal artery, 4-Middle hilar branch of superior renal artery, 5-Superior renal vein, 6-Middle renal vein, 7- Abdominal aorta, 8-IVC, 9-Right gonadal vein, 10-Inferior renal artery, 11-Inferior renal vein, 12-Right ureter)

3. Discussion

The renal arteries arise from the abdominal aorta and supply approximately 20% of the cardiac output to the kidneys. Although the concept of renal vascular segmentation was initially noted by John Hunter in 1794, a more comprehensive understanding emerged in the 1950s through corrosion cast studies. These studies delineated five distinct arterial segments: apical, superior, middle, inferior, and posterior. Understanding the anatomy of these segments is crucial for performing nephrectomies accurately.

The reported incidence of multiple renal arteries is 20.2% on the right side and 19% on the left side [5]. The renal vessels i.e. renal arteries as well as renal veins were double on both sides [6]. Also in a retrospective analysis of the details of the anatomy of the renal arteries of 403 kidney donors multiple renal arteries occurred bilaterally in 10.2% of donors and unilaterally in 20.8%, a total incidence of 31% [7]. In the present case there was duplication of renal vessels on the right side whereas the left side was found to have single renal vessels. In a study of renal arterial vasculature of 594 kidneys from 300 subjects (28 cadavers, 272 CT) multiple renal arteries were discovered in 22% of subjects and 12.12% of kidneys [8].

Mansur DI et al evaluated Computed Topographic images of 206 kidneys in which they found that 25.72% of kidneys were supplied by double renal artery and 0.49% by triple renal artery. The prevalence of superior polar artery was found in 6.79%, hilar in 10.19% and inferior polar in 9.22% [9]. The findings of this study are in correlation with the findings of our case report in terms of variations in the branching pattern of the renal artery.

Hassan SS et al studied 7 cadavers and found double, triple, and quadruple renal veins unilaterally (5; 8%) and double and triple renal arteries unilaterally (3; 5%) [10]. Hostiu S *et al* reviewed 105 articles

to establish the actual prevalence of renal vein variations and found overall prevalence for retroaortic renal vein was 3%, for circumaortic renal vein - 3.5% and for multiple renal veins - 16.7% [11]. These findings align with the observations outlined in our case report.

The presence of variations in the number, branching, distribution patterns, and relationships of renal vessels, as observed in different cadavers presents a challenge to healthcare professionals involved in diagnosing and treating patients with renal, urologic, or related diseases. These variations could also pose risks to otherwise healthy kidney donors, leading to minor or major health compromises.

3.1 Embryological basis for the variations of renal artery

The developmentally definitive renal artery supplying the kidney represents the lateral splanchnic branch of the aorta at the level of a second lumbar vertebra. Urogenital rete arteriosum is a network formed by mesonephric arteries that gives rise to arterial segments which supply the gonads, mesonephros and metanephros.

There are nine pairs of lateral mesonephric arteries arising from the dorsal aorta between the 6th cervical to the 3rd lumbar segments. The renal arteries arise from the third to fifth pairs of these vessels. As development progresses, these arteries undergo degeneration, resulting in the persistence of only one mesonephric artery on each side, which then becomes the definitive renal artery. However, if more than one artery from these arteries persists, it leads to the presence of multiple renal arteries [4].

3.2 Embryological basis for the variations of renal vein

The renal veins are formed by the anastomosis of the supra- and subcardinal veins. Two renal veins form (ventral and dorsal); however, the dorsal vein usually degenerates, and the ventral vein forms the

renal vein [1]. If there is persistence of the dorsal vein it may result in duplication of veins on the right side. Accessory renal veins consisted of persistent mesonephric veins that drained into the right subcardinal vein.

Hence, the authors advocate for the inclusion of clinically significant variations in renal anatomy during preclinical anatomy teaching. This approach would provide students with essential knowledge that promotes awareness and preparedness for clinical practice.

4. Conclusion

Understanding these variations of renal vessels is crucial for accurately interpreting cross-sectional images, preventing misdiagnosis of retroperitoneal and mediastinal masses or adenopathy, and notifying the surgeon and angiographer about potential sources of pre-operative complications.

Acknowledgements

The authors extend their heartfelt gratitude to the individuals who generously donated their bodies to science, enabling crucial anatomical research. The findings from such studies have the potential to advance humanity's collective understanding, leading to enhancements in patient care. Hence, these donors and their families warrant our utmost appreciation.

References

1. Sontakke, Y. (2023). Textbook of Human Anatomy Volume 4. 1st ed. CBS Publishers & Distributors pvt. Ltd. 2023, pp-320-350.
2. Cruzat, C., Olave, E. (2013). Irrigación renal: multiplicidad de arterias. *Int. J. Morphol.* 31, 911–914.
3. Gebremickael, A., Afework, M., Wondmagegn, H., Bekele, M., (2021). Renal vascular variations among kidney donors presented at the national kidney transplantation center, Addis Ababa, Ethiopia. *Transl. Res. Anat.* 25;100145.
4. Buddhiraja, V., Rastogi, R., Anjankar, V., Ramesh Babu, CS., Goel P., (2013). Supernumerary Renal Arteries and Their Embryological and Clinical Correlation: A Cadaveric Study from North India. *ISRN Anatomy.* 2013;4057712.
5. Janschek, E. C., Rothe, A. U., Holzenbein, T. J., Langer, F., Brugger, P. C., Pokorny, H., et al. (2004). Anatomic basis of right renal vein extension for cadaveric kidney transplantation. *Urology.* 63(4):660–4
6. Mir, N. S., Ul Hassan, A., Rangrez, R., Hamid, S., Sabia, Tabish, S. A., Iqbal, Suhaila, Masarat, & Rasool, Z. (2008). Bilateral Duplication of Renal Vessels: Anatomical, Medical and Surgical perspective. *International journal of health sciences,* 2(2), 179–185.
7. Coen, L. D., and A. T. Raftery. (1992). Anatomical variations of the renal arteries and renal transplantation. *Clinical Anatomy: The Official Journal of the American Association of Clinical Anatomists and the British Association of Clinical Anatomists.* 5.6 (1992): 425-432.
8. Tardo, D.T., Briggs, C., Ahern, G., Pitman, A., Sinha, S. (2017). Anatomical variations of the renal arterial vasculature: An Australian perspective. *J Med Imaging Radiat Oncol.* 61(5):643-649.
9. Mansur, DI., Karki, S., Mehta, D. K., Shrestha, A., Dhungana, A. (2019). A Study on Variations of Branching Pattern of Renal Artery with its Clinical Significance. *Kathmandu Univ Med J (KUMJ).* 17(66):136-140.
10. Hassan, S. S., El-Shaarawy, E. A., Johnson, J. C., Youakim, M. F., Ettarh, R. (2017). Incidence of variations in human cadaveric renal vessels. *Folia Morphol (Warsz).* 76(3):394-407.
11. Hostiuc, S., Rusu, M. C., Negoii, I., Dorobanțu, B., Grigoriu, M. (2019). Anatomical variants of renal veins: A meta-analysis of prevalence. *Sci Rep.* 9(1):10802.