

## The Pulley Technique Revisited

B J Sebastian, B Mirshekar-Syahkal, T Athisayaraj, N Ward

West Suffolk Foundation NHS Trust

Bury St Edmunds, United Kingdom

Received: 04-11-2023 / Revised: 24-11-2023 / Accepted: 15-12-2023

DOI: <https://doi.org/10.32553/ijmbs.v7i12.2750>

Corresponding author: B J Sebastian

Conflict of interest: No conflict of interest.

### Background

A 75-year-old man was referred with rectal bleeding and was booked for a flexible sigmoidoscopy on the straight to test pathway. The scope was successfully inserted to the Splenic flexure, without much difficulty. The initial withdrawal was smooth but later became difficult; the scope appeared to be frozen, and we were unable to withdraw further – it was possible to advance the scope, but unable to withdraw. The patient was comfortable and various manoeuvres were tried, like clockwise and counter clockwise torque, change of position etc. Unfortunately, none of these manoeuvres were successful. History, physical examination and scope position on magnetic scope imager confirmed the scope in a left inguinoscrotal hernia.

Various manoeuvres to withdraw the scope were unsuccessful. The endoscopist and a colleague came up with a plan to keep the scope in a ‘long loop’ position in the hernia, by manually holding to the scope, through the scrotum and allowing it to slide on withdrawal, which proved successful.

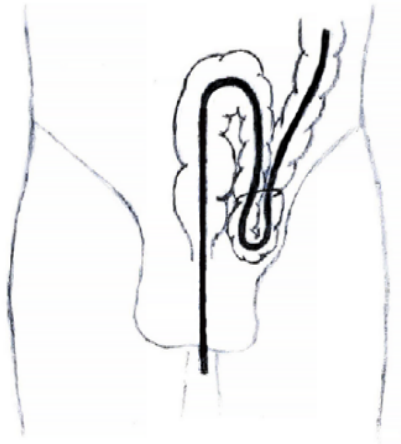
### Technique and Discussion

Lower GI endoscopy is a commonly performed procedure, with a low risk of complications. This was the first time the endoscopists, who are both experienced, came across this problem. As Inguinal hernia is a common condition, one would expect to see this complication more frequently.

However, on literature search, there are only few reports. Endoscopists have dealt with the situation in different ways. During the search, we came across the ‘Pulley’ technique, described in 1991 by Koltun et al<sup>i</sup>, which was similar to what we did. We will review the literature and explain the Pulley technique for the benefit of the endoscopists, who are unaware of this technique. The first report we could identify about a colonoscope getting stuck in a hernia was by Leisser et al<sup>ii</sup> in 1990, who describes ‘cautious application of pressure from different directions’, resulting in successful reduction. Leichtmann et al describes use of adhesive plaster to reduce the hernia before colonoscopy<sup>iii</sup>. There is also a report by M P Saunders<sup>iv</sup> in 1995, reporting another case. Since then, there have been multiple reports in the literature<sup>v, vi, vii</sup>

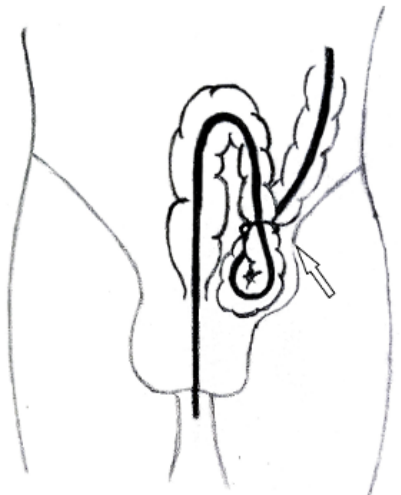
The incarceration seems to occur predominantly on the left side, and although can occur during insertion or withdrawal, incarceration during withdrawal appears to be more common<sup>5</sup>. If the hernial orifice is narrow, it might prevent the colonoscope from progressing into the sac. When the orifice is bigger, it might permit the entry of the scope into the hernia, but prevent it from exiting the sac. If the orifice is even

bigger, the scope might enter and exit the hernia, thereby permitting the colonoscopy to continue (Fig 1).



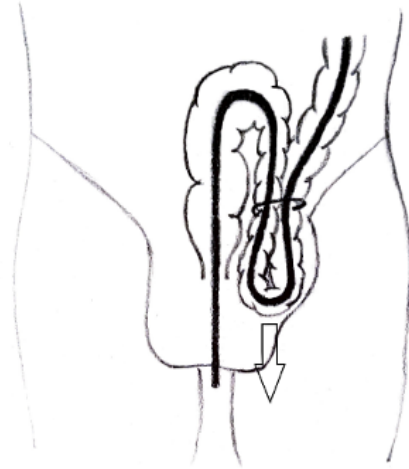
**Figure 1:**

However, on withdrawal, the afferent and efferent limbs of the scope will crowd the hernial orifice, creating short loop (the scope has a minimum radius of curvature, which could be bigger than the hernial defect), preventing withdrawal of the scope (Fig 2).



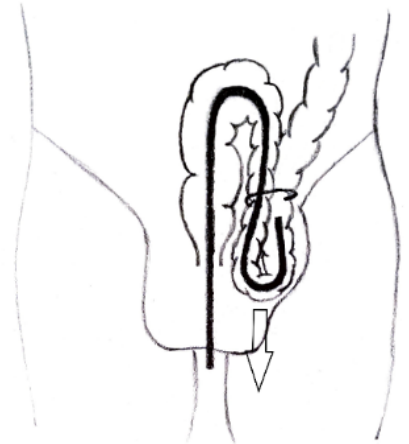
**Figure 2:**

Many techniques are described, starting from simple manipulation to reduction under anaesthetic. However, the pulley technique seems to be the simplest and the most effective. The pulley technique has been described by Koltun *et al*<sup>1</sup>. They suggested advancing the scope to the reform a long (large) loop and then held in that position by grabbing the colonoscopy in the scrotum, along the inner edge of the curvature (Fig 3).



**Figure 3:**

On withdrawal, the position is maintained, which allows the scope to exit the sac, one limb at a time (Fig 4). The fingers holding the scope in the scrotum acts as a pulley.



**Figure 4:**

### Conclusion

Incarceration of the colonoscopy is surprisingly uncommon, given the incidence of inguinal herniae and the increasing numbers of lower GI endoscopies. However, every endoscopist needs to be aware of this potential complication and the simple method of managing it, the Pulley technique.

## References

- <sup>i</sup> Koltun WA, Collier JA. Incarceration of colonoscope in an inguinal hernia. "Pulley" technique of removal. *Dis Colon Rectum* 1991; 34: 191-193 [PMID: 1993418]
- <sup>ii</sup> Leisser A, Delpre G, Kadish U. Colonoscope incarceration: an avoidable event. *Gastrointest Endosc.* 1990 Nov-Dec;36(6):637-8. doi: 10.1016/s0016-5107(90)71200-x. PMID: 2279673.
- <sup>iii</sup> Leichtmann GA, Feingelrent H, Pomeranz IS, Novis BH. Colonoscopy in patients with large inguinal hernias. *Gastrointest Endosc.* 1991 Jul-Aug;37(4):494. doi: 10.1016/s0016-5107(91)70797-9. PMID: 1916182.
- <sup>iv</sup> Saunders MP. Colonoscope incarceration within an inguinal hernia: a cautionary tale. *Br J Clin Pract.* 1995 May-Jun;49(3):157-8. PMID: 7779671.
- <sup>v</sup> Tan VP, Lee YT, Poon JT. Incarceration of a colonoscope in an inguinal hernia: Case report and literature review. *World J Gastrointest Endosc.* 2013 Jun 16;5(6):304-7. doi: 10.4253/wjge.v5.i6.304. PMID: 23772270; PMCID: PMC3680622.
- <sup>vi</sup> Torrealba M, Matlock R, Petrun B, Zera R, Malli A. Incarcerated Colonoscope in a Left Inguinal Hernia During Diagnostic Colonoscopy. *ACG Case Rep J.* 2021 Apr 26;8(4):e00564. doi: 10.14309/crj.0000000000000564. PMID: 33928178; PMCID: PMC8078289.
- <sup>vii</sup> Abe Y, Ohya Y, Nakahara O, Chiyonaga S, Maeda Y, Ichikawa R, Imamura M, Yamabe S, Morinaga T, Tsuji A, Hayashida S, Iizaka M, Sasaki M, Inomata Y. Incarceration of a colonoscope in an inguinal hernia: A report of two cases. *DEN Open.* 2022 May 10;3(1):e126. doi: 10.1002/deo2.126. PMID: 36247312; PMCID: PMC9549876.