

***Schizophyllum spp.* in Covid-19- A Series of Ten Cases from a Tertiary Care Hospital of Central India.**

**Dr. Sunita Raj Gajbhiye¹, Dr. Diptanu Majumder*², Dr. Nirmal Manohar Channe³,
Dr. Bhawana Bajare⁴, Dr. Sunanda S Zodpey⁵**

¹MBBS, MD, Professor, Department of Microbiology, Government Medical College, Nagpur, India.

ORCID: 0000-0003-3046-7827

²MBBS, MD, Senior Resident, Department of Microbiology, Seth GS Medical College and KEM Hospital, Mumbai, India

ORCID: 0009-0005-5282-3791

³MBBS, MD, DNB, Assistant Professor, Department of Microbiology, Government Medical College, Nagpur, India.

⁴MBBS, MD, Assistant Professor, Department of Microbiology, Government Medical College, Nagpur, India.

⁵MBBS, MD, Professor & Head of the Department, Department of Microbiology, Government Medical College, Nagpur, India

Received: 19-09-2023 / Revised: 14-10-2023 / Accepted: 20-11-2023

DOI: <https://doi.org/10.32553/ijmbs.v7i11.2744>

Corresponding author: Dr. Diptanu Majumder

Conflict of interest: No conflict of interest.

Abstract

Background: *Schizophyllum species* can cause diverse clinical infections like sinusitis, pulmonary disease, ulcerative lesions of the palate, atypical meningitis, cerebral abscess which can occur in both immunocompetent and immunocompromised individuals. Although it is one of the emerging fungi, data on clinical features and outcomes of fungal diseases caused by *Schizophyllum spp.* in India are currently not sufficient. A failure to exhibit morphological characteristics leads to difficulties in identification, incorrect therapy and decreased frequency of reporting. It is one of the underreported fungal species and the disease load is much higher than reported. Here, we report a series of ten cases where *Schizophyllum* is isolated as the causative fungal agent.

Materials and methods: Nasal scrappings were taken from suspected mucormycosis patients and processed for KOH mount and fungal culture by standard methods.

Results: *Schizophyllum spp.* were isolated from ten suspected patients and majority of them had history of Covid-19, increased blood sugar level and steroid therapy. One of them was a case of T-lymphoid leukaemia under chemotherapy. All the patients were discharged from the hospital after successful treatment.

Conclusion: During the second wave of Covid-19 pandemic there was sudden rise of mucormycosis cases in India. This study shows that *Schizophyllum spp.* can also be a causative fungal agent in post covid patients showing similar signs and symptoms like mucormycosis and can easily be misdiagnosed

Introduction

Severe Acute Respiratory Syndrome- Corona virus-2 (SARS-CoV-2) is responsible for lower respiratory tract infection which can lead to diffuse alveolar damage with severe inflammatory exudation and altered immune response [1].

Covid patients accompanied with comorbidities and immunocompromised state such as diabetes, prolonged neutropenia, Glucocorticoid use, transplantation, inherited or acquired immunodeficiencies, and tumour are more likely to develop different fungal co-infection.

Schizophyllum spp. is a mold of phylum Basidiomycota, Schizophyllaceae family distributed widely in nature and grows on rotting wood and other plants [2,3].

This fungus is rarely reported in humans because it is difficult to diagnose in many clinical settings. It has been recognized as the etiological agent of a variety of hypersensitivity disorders, such as allergic sinusitis, bronchopulmonary mycoses, chronic eosinophilic pneumonia, and of invasive infections such as fatal disseminated infections involving the lungs, orbit, and brain [4,5].

Among them, bronchopulmonary infections and sinusitis account for more than 90% of the reported cases worldwide [6]. The localisation or spreading of the infection from the original site to other tissues and organs depend on the factors such as the immune status of the host, deviation of the nasal septum, use of corticosteroid therapy and duration of exposure to the spores [4].

This fungus is rarely reported till date as a causative agent of fungal co-infection in Covid-19 patients. To the best of our knowledge, this is the first study from this region of India reporting a series of ten cases of schizophyllum infection associated with Covid-19 patients during the 2nd wave of the pandemic.

METHODOLOGY

This study was conducted in the Diagnostic Microbiology Laboratory of a tertiary care hospital in central India. We received nasal scrapings of suspected patients from various departments during April to September, 2021. Demographic details, detailed medical history, clinical features, COVID-19 infection and treatment history, final clinical diagnosis and treatment outcome were recorded for all the patients. Standard imaging was done for all patients which included Computed tomography (CT) and magnetic resonance imaging (MRI) of the paranasal sinus(PNS), Chest and orbit and the findings are mentioned in the table no-1.

Nasal scrapings were processed for potassium hydroxide (KOH) mount, Gram stain and Fungal culture according to the standard procedures. The specimens were inoculated on two Sabouraud's Dextrose Agar (SDA) slants, one incubated at 37°C and another at room temperature. From a fungal growth observed, slide culture was prepared on corn meal agar and incubated at room temperature in wet chamber and observed for sporulation on alternate days. Findings on Lactophenol Cotton Blue (LPCB) mount and microscopic characteristics of the slide culture were used for the presumptive diagnosis. The suspected cultures were kept in dark for better growth with enhanced pigment production.

Hyaline septate branched hyphae of variable thickness (figure no-1) were found on KOH mount. On SDA, spreading, woolly, whitish to pale colored growth was seen after 3-4 days with characteristic droplets of exudate. (Fig no- 2) Later it became dark brown and spreading over the surface of the slant. It became rough and leathery with enhanced reddish pigment when grown in the dark at room temperature (figure no- 3). On microscopy, branched septate hyphae was found with clamp connection morphologically suggestive of *Schizophyllum spp.* (figure no- 4)

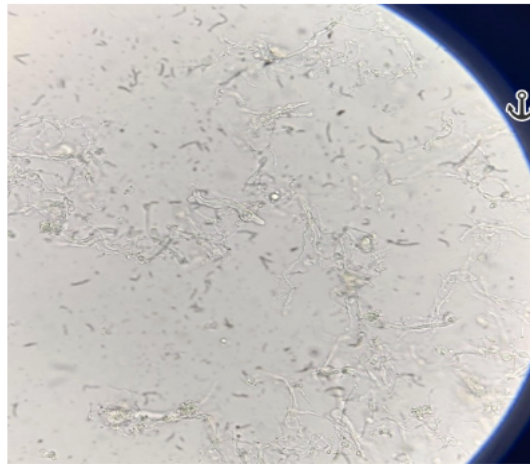


Figure 1: KOH mount showing the fungal hyphae

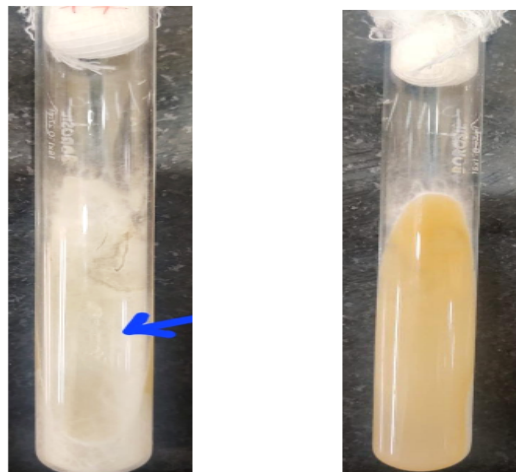


Figure 2: Droplets of exudate on the obverse view and reverse view




Figure 3: SDA slopes kept on the dark (Obverse & Reverse view)

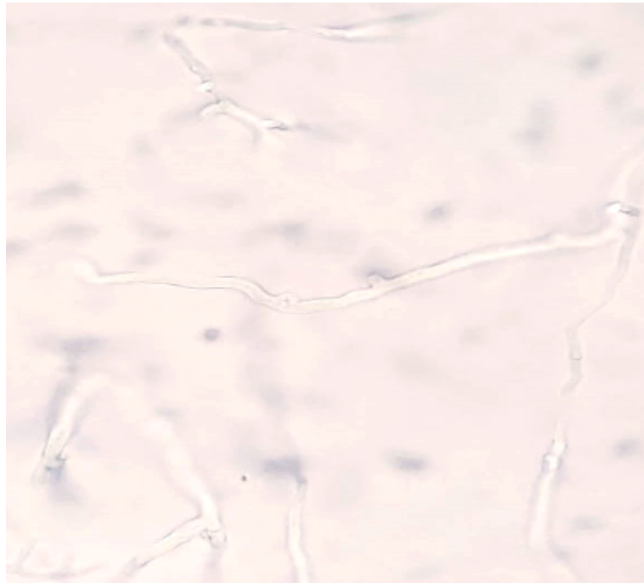


Figure 4: Culture on corn meal agar

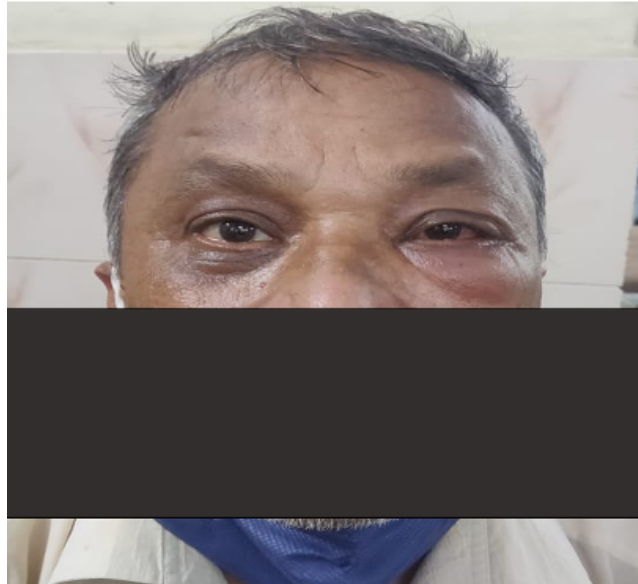

Figure 5: One of the patients with left sided periorbital swelling

Results

The patients included in this case series were from the second wave of the covid pandemic and all of them were post covid. Most of the patients were from the age group of 30 to 70 years with male preponderance. Paranasal symptoms alone were present in 50% patients followed by ophthalmological symptoms in 40% patients. Both these symptoms were found in 80% of the patients.

Majority of the patients had comorbidities like diabetes, hypertension and history of steroid therapy. Seven of them were treated surgically with endoscopic debridement followed by liposomal amphotericin-B and oral posaconazole for 14 days and the remaining three patients were treated with only antifungals like Amphotericin-B, posaconazole and itraconazole. After clinical improvement all the patients were discharged from the hospital. Detailed history of all the patients is mentioned in table no-1.

Table 1: Clinical details of the patients

Sr No	Age/ Sex	Presenting Complaints	Past History	Additional Findings	Treatment Received
1.	16/M	Swelling around the right eye	T- Lymphoblastic lymphoma on chemotherapy Diabetes mellitus	Hb- 5.5, TLC-3600, Platelet count- 10,200 CT PNS- Thickening of right ethmoidal sinus, oedematous thickening of right zygomaticus muscle suggestive of cellulitis	Blood transfusion Endoscopic debridement Liposomal Amphotericin-B Posaconazole
2.	39/M	Headache Peri-nasal and Facial pain	Diabetes mellitus	CT PNS- Thickening of left maxillary sinus	Left endoscopic debridement
3.	60/M	Mucopurulent nasal discharge Nasal obstruction Headache	No	CT PNS- Mucosal thickening of Bilateral Maxillary sinus	Endoscopic debridement Posaconazole
4.	61/M	Fever Productive cough & Haemoptysis Shortness of breath- grade 3	Hypertension	CRP-29, LDH-439, CKMB- 8.7, Ferritin-1253 HRCT Chest- S/o Infective etiology. ?fungal CT PNS- Thickening of right ethmoidal sinus suggestive of fungal sinusitis	Amphotericin-B Itraconazole
5.	37/M	Blurring of vision Toothache Facial pain Hearing loss	No	CT PNS- Mucosal thickening of Bilateral Maxillary sinus	Endoscopic debridement Amphotericin-B Posaconazole
6.	45/M	Left sided facial pain and swelling toothache	No	MRI PNS- Altered thickening of maxillary ostium	Endoscopic debridement
7.	29/M	Periorbital and paranasal pain Toothache	No	Not known	Endoscopic debridement
8.	28/M	Periorbital swelling	Post covid mucormycosis	MRI suggestive of inflammatory changes	Amphotericin-B Posaconazole
9.	69/F	Fever Productive cough Shortness of breath	Hypertension Intestinal fibrosis	CRP-48, CKMB- 27, LDH- 264, Ferritin- 78	Amphotericin-B Posaconazole
10.	55/M	Blurring of vision Periorbital swelling	Diabetes mellitus	CT PNS- Soft tissue swelling and focal erosion in B/L ethmoidal sinus and intra-orbital abscess formation	Endoscopic debridement Orbital decompression with subtotal maxillectomy Amphotericin-B

Discussion

In COVID-19 patients, overexpression of inflammatory cytokines, and impaired cell-mediated immune response with decreased CD4+T and CD8+T cell counts make them susceptible to fungal co-infection [7]. The combination of diabetes, immunosuppression and increased use of corticosteroids to combat infection with COVID-19 appears to be the additional factors increasing the risk of development and aggravating existing opportunistic fungal infections like *Schizophyllum spp.*[8]. There is increase in the frequency of fungal infections caused by basidiomycetes particularly, *Schizophyllum spp.* and it has become a much more common human pathogen in both immunocompetent and immunocompromised hosts [9, 10].

CT PNS of seven of the patients was suggestive of sinusitis. Studies from different countries have reported *Schizophyllum* as a causative organism of fungal sinusitis in both immunocompromised and immunocompetent patients [11-15]. In this study, all the ten patients were post-covid with the history of corticosteroid therapy. Ophthalmological infection caused by *Schizophyllum spp.* also reported by Sa HS *et al.* in 2012, Kaur *et al.* in the year 2020 [11, 13]. Similarly, there is case report of pneumonia caused by *S. commune* in a immune compromised individual of acute myeloid leukemia [16].

It has clinical similarity with aspergillosis and mucormycosis and clinically it is very difficult to differentiate them. There was a sudden outbreak of mucormycosis during the second wave of covid-19 and these ten patients were clinically suspected to have mucormycosis. Hence, seven of them were treated with endoscopic debridement followed by liposomal amphotericin B and oral posaconazole therapy. Surgical debridement and antifungal therapy are the treatment of choice in invasive fungal sinusitis and the treatment outcome is found to be good. However, the type, dose and duration of antifungal agents to be administered remain uncertain as, currently no sufficient data available

regarding epidemiological cutoff values or clinical breakpoints for *Schizophyllum spp.*[17]. Drugs known to have anti-mold activity are considered as favorable antifungal agent and recommended as the initial choice in patients with respiratory tract invasive fungal disease caused by *Schizophyllum* [16]. Cases of allergic bronchopulmonary mycosis caused by *Schizophyllum* were successfully treated with oral Itraconazole therapy and recrudescence of the disease was prevented for four years [18].

Conclusion

During the second wave of Covid-19, infections showing similar symptoms were misdiagnosed clinically as Mucormycosis and treated accordingly. But unlike mucor, it has good prognosis with proper oral antifungal therapy. We want to emphasize that accurate identification and proper treatment approach can prevent the disease burden caused by *Schizophyllum spp.* Hence, broad knowledge of different clinical presentations and high index of suspicion are required to ensure accurate diagnosis and correct treatment in immunocompromised patients.

Limitations of the study:

Elaborate species identification could not be done due to constrained resources in the laboratory.

Highlights: *Schizophyllum spp.* Can be a causative fungal agent in post-covid patients showing similar symptoms as mucormycosis.

Acknowledgement: Technical staff of Mycology section, Department of Microbiology, Government Medical College, Nagpur

References

1. Wang Y, Wang Y, Chen Y, Qin Q. Unique epidemiological and clinical features of the emerging 2019 novel coronavirus pneumonia (COVID-19) implicate special control measures. *J Med Virol.* 2020.
2. Cavanna C, Pagella F, Esposito MC, Tamarozzi F, Clemente L, Marone P, *et al.* Human infections due to *Schizophyllum commune*: case

- report and review of the literature. *J Mycol Med.* 2019;29:365–71.
3. Zhang SX, O'donnell K, Sutton DA. Fusarium and other opportunistic hyaline fungi. In: Jorgensen JH, Carroll KC, Funke G, Pfaller MA, Landry ML, Richter SS, Warnock DW, eds. *Manual of clinical microbiology.* 11th ed. Washington, DC: ASM press; 2015;2069-70.
 4. Chowdhary A, Randhawa HS, Gaur SN, Agarwal K, Kathuria S, Roy P, et al. *Schizophyllum commune* as an emerging fungal pathogen: A review and report of two cases. *Mycoses* 2013;56:1-10.
 5. Reddy AK, Ashok R, Majety M, Chitta M, Narayen N. Fungal keratitis due to *Schizophyllum commune*: An emerging pathogenic fungus. *Mycoses* 2016;59:757-9.
 6. Chan JFW, Teng JLL, Li IWS, Wong SCY, Leung SSM, Ho PO, et al. Fatal empyema thoracis caused by *Schizophyllum commune* with cross-reactive cryptococcal antigenemia. *J Clin Microbiol.* 2014;52:683–7.
 7. Song G, Liang G, Liu W. Fungal Co-infections Associated with Global COVID-19 Pandemic: A Clinical and Diagnostic Perspective from China. *Mycopathologia.* 2020 Aug;185(4):599-606. doi: 10.1007/s11046-020-00462-9. Epub 2020 Jul 31. PMID: 32737747; PMCID: PMC7394275.
 8. Amin A, Vartanian A, Poladian N, Voloshko A, Yegiazaryan A, Al-Kassir AL, Venketaraman V. Root Causes of Fungal Coinfections in COVID-19 Infected Patients. *Infect Dis Rep.* 2021 Dec 4;13(4):1018-1035. doi: 10.3390/idr13040093. PMID: 34940403; PMCID: PMC8701102.
 9. Buzina W, Lang-Loidolt D, Braun H, Freudenschuss K, Stammberger H. Development of molecular methods for identification of *Schizophyllum commune* from clinical samples. *J Clin Microbiol* 2001; 39: 23912396.
 10. Lacaz Cda S, Heins-Vaccari EM, De Melo NT, HernandezArriagada GL. Basidiomycosis: a review of the literature. *Rev Inv Med Trop Sao Paulo* 1996; 38: 379390.
 11. Sa HS, Ko KS, Woo KI, Peck KR, Kim YD. A case of sino-orbital infection caused by the *Schizophyllum commune*. *Diagnostic microbiology and infectious disease.* 2012 Aug 1;73(4):376-7.
 12. Michel J, Maubon D, Varoquaux DA, Boulze C, Normand AC, Righini CA, Piarroux R, Dessi P, Ranque S. *Schizophyllum commune*: an emergent or misdiagnosed fungal pathogen in rhinology?. *Sabouraudia.* 2015 Nov 26;54(3):301-9.
 13. Kaur M, Chander J, Singla N, Das A, Sood S, Guarro J. Sino-orbital infection caused by *Schizophyllum commune*-rare presentation of a basidiomycetous fungus. *Journal de Mycologie Medicale.* 2020 Jan 30;30(2):100934.
 14. Narazaki T, Nakashima Y, Tsukamoto Y, Nishida R, Tsuda M, Muta H, Kimura D, Masuda T, Takamatsu A, Kohashi K, Murakami D. *Schizophyllum commune* sinusitis after allogeneic bone marrow transplantation for myelodysplastic syndrome: A case report and literature review. *Transplant Infectious Disease.* 2020 Feb;22(1):e13205.
 15. Filipe R, Caldas JP, Soares N, Sabino R, Verissimo C, Silva R, Silva-Pinto A, Tavares M, Sarmiento A. *Schizophyllum commune* sphenoidal sinusitis as presentation of a non-Hodgkin Lymphoma. *Medical mycology case reports.* 2020 Jun 1;28:26-8.
 16. Kim H, Yi Y, Cho SY, Lee DG, Chun HS, Park C, Kim YJ, Park YJ. Pneumonia due to *Schizophyllum commune* in a Patient with Acute Myeloid Leukemia: Case Report and Literature Review. *Infect Chemother.* 2022 Mar;54(1):195-201. doi: 10.3947/ic.2020.0068. Epub 2020 Sep 18. PMID: 33124214; PMCID: PMC8987182.
 17. Rihs JD, Padhye AA, Good CB. Brain abscess caused by *Schizophyllum commune* an emerging basidiomycete pathogen. *Journal of Clinical Microbiology.* 1996;34(7):1628–1632
 18. Ogawa H, Fujimura M, Ohkura N, Makimura K. Implications of high antifungal susceptibility on *Schizophyllum commune*-associated allergy in clinical practice. *Antimicrob Agents Chemother.* 2013 Nov;57(11):5783. doi:10.1128/AAC.01657-13. PMID: 24123344; PMCID: PMC3811255.