

Emergency Management of Symphysis and Right Angle of Mandible Fracture with Laceration Wound at Buccal and Submental Region: A Case Report

Tendi Fauzi¹, Winarno Priyanto², Endang Syamsudin³

¹Student in the Faculty of Dentistry, Padjadjaran University, Bandung, Indonesia

²Staff of Oral and Maxillofacial Surgery Department, Dr. Hasan Sadikin General Hospital Bandung, Indonesia

³Staff of Oral and Maxillofacial Surgery Department, Faculty of Dentistry, Padjadjaran University, Bandung, Indonesian

Received: 19-08-2023 / Revised: 14-09-2023 / Accepted: 07-10-2023

DOI: <https://doi.org/10.32553/ijmbs.v7i10.2725>

Corresponding author: Tendi Fauzi

Conflict of interest: No conflict of interest.

Abstract

Introduction: Fracture of the mandible is a case that is quite commonly found in the ER of The Oral and Maxillofacial Surgery Department at Dr. Hasan Sadikin General Hospital Bandung, fractures of the mandible rank second to fractures of the facial area because it is a prominent bone that is located at the edge and position in the lower third of the face. Emergency management aims to take any appropriate action, prevent complications, and consult other departments involved.

Objective: To explain the emergency management of symphysis and right angle of mandible fracture with laceration wound at buccal and submental region.

Case report: A man age 21 year came with bleeding from the mouth due to a motorcycle accident approximately 24 hours before admission to the hospital. Physical examination showed asymmetrical face, edema at right cheek region, laceration wound at right cheek and chin region, and multiple abrasive wound at facial region. There were steps, crepitus on symphysis, and right angle of mandible region. Intraoral examination showed laceration wounds on the gingiva.

Case management: The laceration area is then sutured both intraoral and extraoral followed by the application of closed reduction in the mandible with interdental wiring at the lower jaw aiming to prevent infection and malunion. The management of soft tissue and hard tissue injury is by reduction, fixation, and immobilization of fractures, management of pain, and administration of antibiotics.

Conclusion: The emergency management of symphysis and right angle of mandible fracture with laceration wound at the buccal and submental region is promptly and rapidly carried out with minimal intervention by using closed reduction method gave good results in stability and function before definitive treatment.

Keywords: angle mandible, closed reduction, fracture, laceration, symphysis

Introduction

Injury has become a major cause of death and disability worldwide. Injury is an increasingly significant health problem throughout the world. Every day, 16000 people die from injuries, and for every person who dies, several thousand more are injured, many of them with permanent sequelae. A fracture is defined as a breach in the continuity of the bone. The facial area is one of the most frequently injured areas of the body, accounting for 23–97% of all facial fractures. The mandible is the only mobile bone of the facial skeleton and there has been a significant increase in the number of cases in recent years. It is embryologically a membrane bone and is more commonly fractured than the other bones of the face. Mandibular fractures occur twice as often as midfacial fractures. The energy required to fracture it being of the order of 44.6–74.4 kg/m, which is about the same as the zygoma and about half that for the frontal bone. It is four times as much force is required to fracture the maxilla. ^{[1],[2],[4]}

The causes of mandible fractures are diverse and include: motor vehicle collisions (MVCs), assaults, falls, sports- and industrial-related injuries, ballistic injuries, and pathologic fractures. Taking all-comers, approximately 75% of mandible fractures are caused by MVC and assault, 7% are due to falls, 7% and 4% due to industrial- and sports-related injuries, respectively, and the remainder is due to pathological, ballistic, and other miscellaneous causes (Figure 1). The most common etiology is variable depending on the socioeconomic status of the patient and the population being examined. For example, in rural or developing countries, MVC remains the most common cause of mandibular trauma; whereas in certain urban settings of developed nations, assault, and interpersonal violence can account for much of the mandibular trauma presenting to trauma centers. ^{[3],[5],[7]}

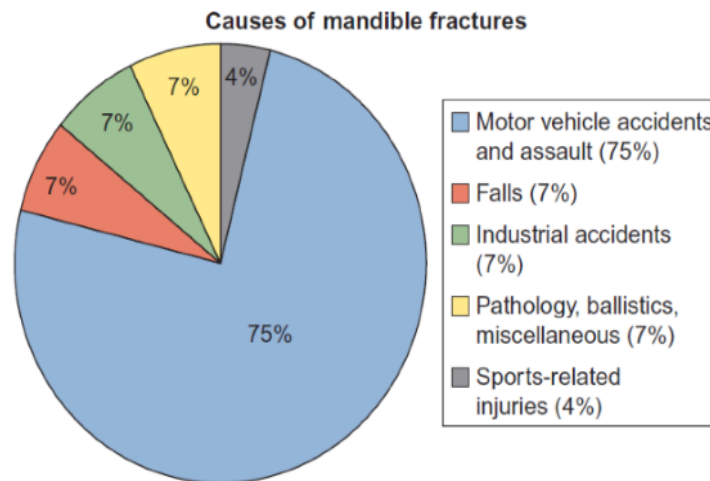


Figure 1: Cause of mandible fractures ^[5]

The incidence of mandible fractures by anatomical location is as follows: angle (31%), condyle (24%), symphysis and parasymphysis (23%), body (19%), ramus (2%), and coronoid process (1%). In addition, a number of studies have looked at the association between causality and fracture location. In fractures secondary to MVC, the body

is the most common site of injury. In those associated with assault, the angle and body are most commonly involved. Boole et al. found that fractures after motorbike accidents most commonly involved the condyle or ramus (Figure 2). ^{[3],[5],[7]}

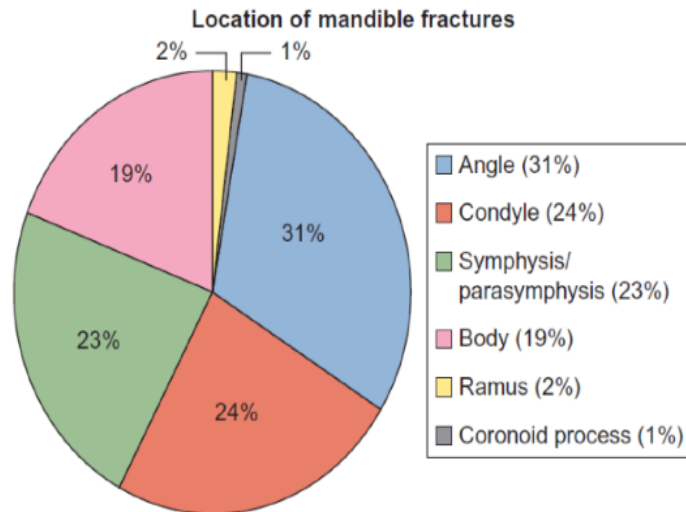


Figure 2: Location of mandible fracture ^[5]

In patients with the trauma of mandible fractures, attention should be given to the possibility of airway obstruction that can be caused by mandibular fracture itself or due to intraoral bleeding that causes blood aspiration. The fall of the tongue toward the back, mucus, blood, vomiting, and foreign objects can block the airway. Shifting of mandibular fracture fragments results in malocclusion in the form of open bite or crossbite and difficulty in opening the mouth wide, which results in difficulty in controlling breathing and swallowing. This certainly requires immediate treatment. ^{[1],[6],[11]}

Treatment of mandibular bone fractures requires certain considerations compared to other fracture treatments. The emergency treatment takes precedence. Treatment of mandibular fractures aims to restore occlusion and function and facilitate direct bone healing by adequate reduction and immobilization on the fractured site. ^{[1],[9],[11]}

Advanced trauma life support (ATLS) is the first step that should be applied in emergency cases. Airway obstruction should be evaluated as soon as possible since the mid-face is the beginning of the respiratory pathway. Hemorrhage and secretions may obstruct the oropharynx and nasopharynx. Removal of fractured teeth, clots, and loose dental crowns or dentures are important to open the oral airway. Packing should be used to control acute

bleeding. Intubation to secure the airway in unstable mid-face fractures is the next step that should be considered in emergency patients. It is important to keep the airway open in mid-face fractures because there is always the potential of airway obstruction due to displacement of bones or severe bleeding in such cases. After providing a secure airway, ATLS protocol can be continued. When the patient is stable, facial examination to detect the mid-face fractures is executed. ^{[1],[3]} This case report will describe principles to explain the emergency management of symphysis and right angle of mandible fracture with laceration wound at buccal and submental region using temporary fixation to prevent further complications.

Case Report

A 21-years-old male patient came with bleeding from his mouth. Approximately 12 hours before admission, when the patient was riding a motorcycle at medium speed suddenly there was a car from the opposite direction that hit him caused him lost his balance and fell with mechanism his face hit the asphalt first. The patient experienced no history of fainting, nausea, and vomiting. There was bleeding from the mouth and there was no bleeding from the nose and ear. Then the patient was brought to a private hospital in the Tangerang area and was performed injection of anti-tetanus and 2 kinds of medicine, chest x-ray and head CT-scan. Then he was referred to Hasan Sadikin

Emergency Department for further treatment. There was no history of alcohol intoxication.

Physical examination showed facial asymmetrical face, edema at right cheek region (Figure 3). Lacerated wound at right cheek and chin region with 3x2x1 cm; 1x1x0.5 cm in size, irregular edge,

muscle based and multiple abrasive wound at facial region (Figure 4A). There were steps, crepitus on symphysis and right angle of mandible region. Intraoral examination shows lacerated wound at gingiva of teeth 31-32 with 1x1x0.5 cm, irregular edge, bone based (Figure 4B).



Figure 3: Extra oral profile from the side and front.

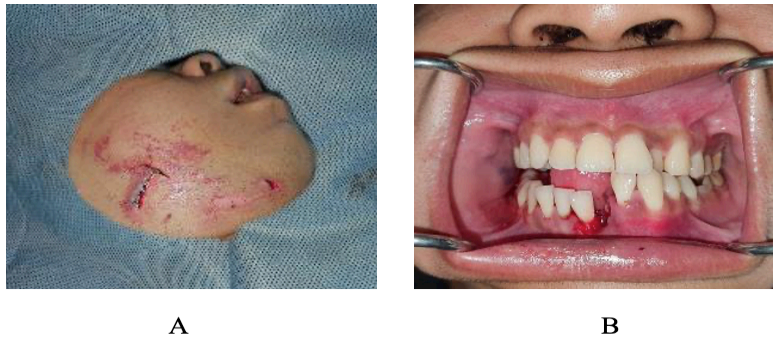

Figure 4: (A) Lacerated wound at buccal and submental (B) Lacerated wound at gingiva 31-32

Radiographic features of head CT-Scan showed no soft tissue swelling, sulci and gyrus are not compressed, sylvian fissure are not compressed, ventricle and system are not compressed, and there was no midline shift (Figure 5). Radiographic features of 3D head CT-Scan showed

Discontinuity of symphysis mandible bone and discontinuity of right angle mandible bone (Figure 6). The diagnoses made are Symphysis and right angle of mandible fracture with laceration wound at buccal, submental and gingiva of teeth 31-32 region region.

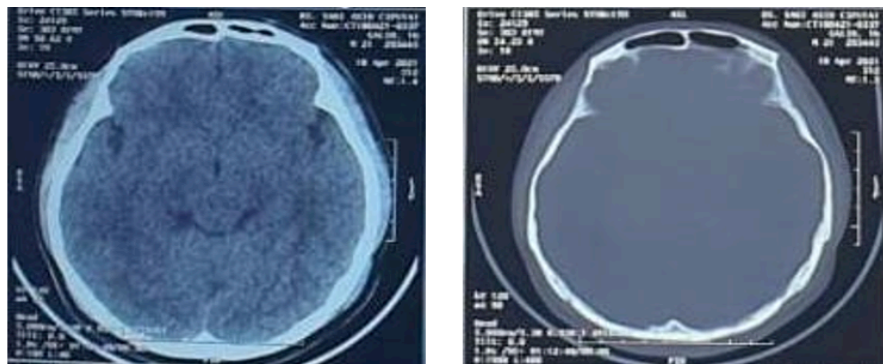


Figure 5: CT Scan X-ray

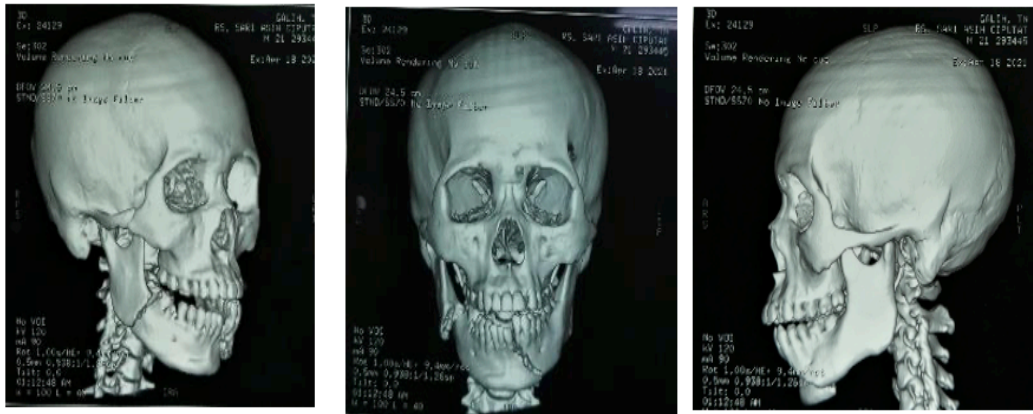


Figure 6: Head 3D CT-Scan

The management of this patient was done by the wound debridement was done using 0.9% NaCl mixed with gentamicin, using a ratio of 500 cc of 0.9% NaCl mixed with 2 cc gentamicin (10 mg/cc). Intraoral laceration wound was stitched using silk vicryl 4.0 and the extra oral wound laceration was sutured using nylon 6.0. Fixation was performed using Inter Dental Wiring (IDW) Erich Arch Bar on the lower jaws of teeth 36-46 (Figure 7).

Discussion

Fracture of the mandible is a case that is quite commonly found in the ER of The Oral and Maxillofacial Surgery Department at Dr. Hasan Sadikin General Hospital Bandung. Handling of Fracture mandible in the initial step is emergency following the ATLS (Advanced Trauma Live Support) rules, consisting of the initial examination or primary survey including airway or airway examination, breathing, blood circulation including shock treatment or circulation, handling soft tissue injuries, and temporary immobilization and evaluation of possible injuries.

The second step is the definitive treatment of fractures. The goal of fracture management is to restore occlusion, mechanical strength of the fracture area, and achieve maximum normal masticatory muscle function. Integration of the fracture is one of the main targets for successful treatment other than occlusion.

Though a myriad of classification schemes have been presented in the maxillofacial trauma

literature, there is no single system globally accepted by practitioners by which to standardize communication. The most commonly referenced scheme is classification by anatomic region: symphysis, body, angle, ramus, condyle, coronoid, and alveolus (Figure 8). These anatomic units are often further subclassified into favorable and unfavorable patterns. Favorableness is determined by the direction of a fracture line when viewed on radiographs in the horizontal or vertical plane. The displacing forces of the muscles of mastication influence the favorableness of mandible fractures. Horizontally favorable fracture lines resist upward displacing forces (Figure 9). A vertically favorable fracture line resists the medial pull of the medial pterygoid on the proximal fragment when viewed in the vertical plane (Figure 10). The following defines each subunit by its anatomy and elucidates relevant favorable and unfavorable fracture patterns.^{2,6,9}

The symphyseal region of the mandible is defined as the region between the roots of the central incisors, running from the alveolar process through the inferior border of the mandible in a vertical orientation. The angle region of the mandible is defined as a triangular area bounded by the anterior border of the masseter muscle to the posterosuperior attachment of the masseter muscle, usually distal to the third molar area. The angle of the mandible is thinner than the body of the mandible. Most fractures of the angle occur in the location of the third molar and extend to the antegonial notch anterior to the true angle. The

masseter, temporalis, and medial pterygoid muscle attachments to the ramus cause displacement of the proximal segment of the angle of the mandible in a superior and medial direction when the fracture is horizontally and vertically unfavorable, respectively. Alternately, these muscles can serve to secondarily stabilize the proximal and distal bony segments in fracture patterns that are vertically and horizontally favorable. The more anterior a fracture occurs along the angle/ body, the more the superior displacement of the fracture is counteracted by the pull of the mylohyoid muscle downward.^{4,6,9}

The physical examination should consist of palpation and inspection. The four classic signs of inflammation, pain, swelling, redness and localized heat, are highly indicative signs of a mandible fracture. Fractured dentition, gingival bruising, lacerations, mobility of teeth, decreased incisal opening and malocclusion are common intraoral findings associated with mandible fractures. Alteration of sensation to the lower lip and chin is pathognomonic of a fracture of the mandible posterior to the mental foramen. However, nondisplaced fractures of the parasymphysis, body or angle rarely give rise to numbness in the distribution of the inferior alveolar nerve. Gingival tissue should be inspected for bruising or lacerations. Trauma causing bleeding, a hematoma, and discontinuity of skin or mucosa may indicate an injury to the underlying mandible. Sublingual ecchymosis is the most common pathognomonic sign of a fracture of the mandible, especially of the symphyseal, parasymphyseal or body regions. posterior open-bite can indicate a fracture of the symphysis, parasymphysis, or alveolar process. Skin on the face of the affected area should be inspected for lacerations, hematoma and swelling, for example, a wound under the chin is a common site of laceration typically indicating symphyseal, parasymphysis, and/or subcondylar fractures. Asymmetries of a patient's face are indications of the possibility of a mandible fracture and abnormal facial contours of the mandible should be assessed.^{[2],[7],[9]}

Outlines the most common radiographic studies utilized in the diagnosis of mandible fractures. The panoramic radiograph (panorex) can be extremely useful in the initial evaluation of the patient with mandibular trauma. Though panoramic radiography may not be readily available, most of the information on the location and vector of displacement can ultimately be garnered by a plain film mandible series inclusive of the following views: (1) Caldwell posteroanterior (PA) radiograph; (2) lateral oblique radiograph; (3) mandibular occlusal view; (4) periapical view; (5) reverse Towne's view. Similarly, these practice patterns have been extended to include the evaluation of trauma within the craniomaxillofacial skeleton, and as such, helical CT with the addition of 3D reformatting has largely supplanted plain-film radiography as the diagnostic gold standard in the acute setting. CT of the craniofacial skeleton provides detailed resolution, and the ability to rapidly and accurately assess the fracture location, vector, and degree of displacement.^{[4],[5],[9]}

The main principles of mandible fractures management are infection control, fracture fragment reduction, fixation, and immobilization. The management of fracture has to eliminate the movement of fracture fragments, because excessive fracture movement can inhibit new bone formation and predisposes it to infection. Several risk factors specifically related to mandibular fracture can cause malunion or non-union. The most common risk factors are infection, poor positioning, lack of immobilization of fracture fragments, presence of foreign bodies, and unfavorable muscle traction in fracture fragments.^{[1],[9],[11]}

In trauma patients with mandibular fractures, attention should be given to the possibility of airway obstruction that can be caused by mandible fracture itself or due to intraoral bleeding that causes blood aspiration [3],[6]. In all these cases there is bleeding from the oral cavity so it is necessary to immediately treat the bleeding so that airway obstruction does not occur and shock due to a lot of bleeding. Temporary immobilization in

all of these cases was immediately carried out by interdental wiring erich's arch bar so that the stable bone fragments were not pulled posteriorly that could interfere with breathing. [2],[7],[11]

Debridement treatment must be accompanied by lifting existing foreign objects. Debridement must include the edges of the wound, bone fragments, foreign objects that enter the wound, necrotic tissue, and if found a hematoma at the same time evacuated. Wounds in the cavity and face can develop into severe infections that spread to the brain can result in meningitis and brain abscesses if treatment is inadequate. In all of these cases immediate debridement and suturing of the situation and treatment of the wound are used to prevent infection. [1],[2],[6]

Efforts to deal with infections are closely related to the use of antibiotics, especially in open fractures. Patients should be given anti-inflammatory medication, and if there are unclean wounds, the administration of the tetanus vaccine needs to be considered. Emergency measures to prevent infection in all of these cases include injecting a serum anti-tetanus drug (ATS) or tetanus toxoid (TT) and 1 gram Ceftriaxone antibiotics. [1],[10],[11]

Definitive treatment of mandibular fracture aimed to reposition the fracture segment into normal anatomic position (reduction) and keep it from moving with fixation. Furthermore, immobilization is used to stabilization fragment when healing process occurred. On the simple mandible fracture are using closed reduction and temporary fixation, then normal occlusion can be reached. In this case the treatment of mandible fracture is fixation and immobilization with erichbar wiring. Erich's arch bar is one of the most commonly used arch bars. This arch bar is connected to a hook on the outer surface with a flat malleable stainless steel metal strip, making it more effective, faster, and easier when fixed. The bar is available in rolls. Bars are cut according to the length of the dental arch, and this will reduce injury to the soft tissue with prominent edges. [6],[9],[11]

Conclusion

The emergency management of symphysis and right angle of mandible fracture with laceration wound at the buccal and submental region is promptly and rapidly carried out with minimal intervention by using closed reduction method gave good results in stability and function before definitive treatment.

References

1. Adiantoro, Seto, Alwin Kasim, and Faturrahman Faturrahman. "Management of Le Fort II fracture accompanied with blowout fracture of orbital base: a case report." *J Dentomaxillofacial Sci* 2.2 (2017): 143-6.
2. Dergin, G.; Emes. Y.; Aybar, B. Evaluation and Management of Mandibular Fracture. *Intech Open*. 1: pp 1-16. 2019
3. Dixon, Julia, et al. "Emergency department management of traumatic brain injuries: A resource tiered review." *African Journal of Emergency Medicine* (2020).
4. Dreizin, D.; Nam, A. F.; Tirada, N.; Levin, M. D.; Stein, D. M.; Bodanapally, U. K.; Mirvis, S. E.; Munera, F. Multidetector CT of Mandibular Fractures, Reductions and Complications: A Clinically Relevant Primer for The Radiologist. pp 1539. 2016
5. Esmaelinejad, Mohammad. "Maxillofacial fractures: from diagnosis to treatment." *Trauma Surgery*. IntechOpen, 2018.
6. Fujioka, M.; Hayashida, K.; Saijo, H. Split Fracture and Displacement of Mandibular Ligula Cortical Plate of Mandibula Symphysis Requires Fixation. 2015.
7. Jose, Anson, et al. "Management of maxillofacial trauma in emergency: An update of challenges and controversies." *Journal of emergencies, trauma, and shock* 9.2 (2016): 73.
8. Greenberg MS. Handbook of Neurosurgery. 7th edition. New York. Thieme;. 885 – 917. 2010
9. ODOÑO, Lauren T.; BRADY, Colin M.; URATA, Mark. Mandible fractures. In: *Facial trauma surgery*. Elsevier, 2020. p. 168-185.

10. Robert E. Lincoln. Practical Diagnosis and Management of Mandibular and Dentoalveolar Fracture in Facial Plastic, Reconstructive and Trauma Surgery. P.597-627. 2004
11. Sjamsudin, Endang, et al. Initial Treatment of Mandibular Fracture: Serial Case. International Journal of Science and Research (IJSR). 2018: 7.426