

Management of Unilateral TMJ Dislocated Facial Bone Fracture due to an rarely Industrial Accident

Fadly Rasyid¹, Endang Sjamsudin², Eka Marwansyah³

¹Resident of Oral and Maxillofacial Surgery, Faculty of Dentistry, Universitas Padjadjaran, Bandung, Indonesia

²Staff of Department of Oral and Maxillofacial Surgery, Faculty of Dentistry, Universitas Padjadjaran, Bandung, Indonesia

³Staff of Department of Oral and Maxillofacial Surgery, Faculty of Dentistry, Universitas Padjadjaran /RSUP Dr. Hasan Sadikin, Bandung, Indonesia

Received: 17-05-2023/Revised: 30-05-2023/Accepted: 20-06-2023

DOI: <https://doi.org/10.32553/ijmbs.v7i6.2717>

Corresponding author: Fadly Rasyid

Conflict of interest: No conflict of interest.

Abstract

Introduction: Traffic accidents commonly cause maxillofacial trauma but rarely industrial accidents. Treatment of multiple maxillofacial traumas needs comprehensive and immediate care to prevent further complications.

Objective: Management of a maxillofacial fracture accompanied by dislocation of the right temporomandibular joint due to a fall in a rice mill.

Case report: A 20-year-old male patient complained of bleeding and facial fractures due to a rice milling accident approximately one day before admission. The case diagnosis was multiple maxillofacial fractures with condyle dislocation. Emergency oral and maxillofacial surgery was performed immediately and quickly with minimal intervention on the upper jaw to prevent persistent cerebrospinal fluid leakage and prevent infection. Definitive treatment was soft tissue reconstruction, ORIF of the maxillary and mandibular fractures, and repositioning of the condyle dislocation.

Conclusion: Multiple facial bone fractures accompanied by TMJ dislocation can result in deformity and loss of facial function affecting the patient's social life. Immediate action and open reduction internal fixation (ORIF) procedure performed in this case were able to restore stomatognathic and facial function.

Keywords: Industrial accident, maxillofacial trauma, open reduction internal fixation, temporal mandibular joint dislocation

Introduction

Oromaxillofacial trauma relates to injury to the hard and soft tissues of the face or jaws caused by physical force, foreign objects, or burns. Any part of the face, such as the eye with its muscles, nerves, and blood vessels, may be injured, resulting in visual impairment, diplopia, shifting eyeball position, and fracture of the orbital bone

due to a decisive blow. While in the oral cavity can cause loose or loose teeth and soft tissue damage such as edema, contusion, abrasion, laceration, and avulsion.^{1,2-4}

Research conducted by Wusiman et al. 2020 explains that the incidence of maxillofacial trauma is related to gender and age, with a

significant cause of trauma in the young adult group.⁵ Explanations from other researchers Panigrahi et al., 2017, Salentijn et al. 2018 and Goldenberg et al. 2019 that the male gender has a high incidence rate of 79.5%, and based on epidemiological data, the age distribution of 21-50 years has a higher incidence.⁶⁻⁸ The most common causes of maxillofacial trauma were assault 15.0%, fall 11.5%, occupational injury 5.9%, and sports 0.4%. The most vulnerable part of the skeleton was the mandible 22.9% followed by the zygoma 7.1%.¹¹ Another study mentioned that traffic accidents are the most common etiological factor, and based on the injury, mandibular fractures are the most common.^{6,7} Frequent trigeminal nerve injuries and the frequency of nerve injuries in relation to mandibular fractures.^{9, 10}

The risk of maxillofacial injury is airway obstruction which is directly life-threatening and relates to the function of airway mechanisms and bleeding in the brain. Appropriate treatment procedures can promote better treatment success according to the management of maxillofacial trauma by Panigrahi et al. 2020. Trauma management has evolved dynamically over the past few decades, reducing mortality rates.^{6,7} Polytrauma patients face challenges in treating maxillofacial injuries due to their proximity to the brain, cervical spine, and airway.^{11,13} Critical injuries to the maxillofacial region may complicate the early management of trauma patients. In cases of maxillofacial injury, the normal airway breathing and circulation (ABC) management procedures are also altered or supplemented with other approaches. Comprehensive and prompt management of maxillofacial trauma will reduce the morbidity and mortality rate.^{6,9,14}

Maxillofacial trauma caused by falling in a rice mill is rarely reported. This article aims to report and discuss the management of maxillofacial trauma accompanied by dislocation of the right tmj due to a fall in a rice mill.

Case Report

A 20-year-old male patient presented with complaints of bleeding and facial fractures. One day before, he had an accident while working in a rice mill, then the patient slipped and fell into the rice milling machine. History of fainting (+), history of nausea and vomiting (-), bleeding from the mouth (+), bleeding from the nose (+), and bleeding from the ears (+). The patient was previously taken to a private hospital where wound cleansing, situational suturing, Ct-scan, and facial X-ray were performed, then referred to the Emergency Department of Hasan Sadikin Hospital. The patient had a history of psychiatric medication. The patient was taking quetiapine fumarate with a history of alcohol intoxication (-).

The primary survey obtained A: clear with C-spine control, B: symmetrical chest shape and movement, right Vesicular Breath Sound is the same as the left, breathing 20 times per minute, C: pulse 88 times per minute, D. GCS assessment 15 (E4M6V5), round pupils are corrected with a diameter of 3 mm, the left eye is the same as the right eye, and there is no paresis: GCS assessment 15 (E4M6V5), round isochor pupils with a diameter of 3 mm, the left eye is the same as the right eye, there is no light reflex disorder, and there is no paresis. The secondary survey showed lacerations on the head, abrasive wounds on the neck and under the mouth.

A general examination of the patient found positive skin turgor, facial asymmetry, edema, and hematoma on the left periorbita, inferior superior labial, mentale, and right cheek. Post situational suturing of frontal, temporoparietal sinistra, palpebra sinistra, and nasal region. Non-anemic on conjunctival examination and non-icteric sclera. A neck examination showed that the jugular venous pressure (JVP) was not elevated, and the submandibular lymph nodes were not palpable and painless. The thoracic examination was within normal limits. Lung, heart, abdomen, and liver examinations were within normal limits. Extremities are warm, and capillary filling time is less than 2 seconds.

Extraoral local status showed edema and hematoma of the left periorbital, inferior superior labii, right cheek, and chin (Fig. 1). Intra-oral examination revealed gum lacerations of regions 12-22 and 33-34 measuring 2x2 cm, irregular

edges, and bone base. The palate had a 2x1 cm laceration, irregular edges, and a bone base. Examination of the buccal mucosa, tongue, floor of the mouth, and tonsils were within normal limits (Fig. 2).

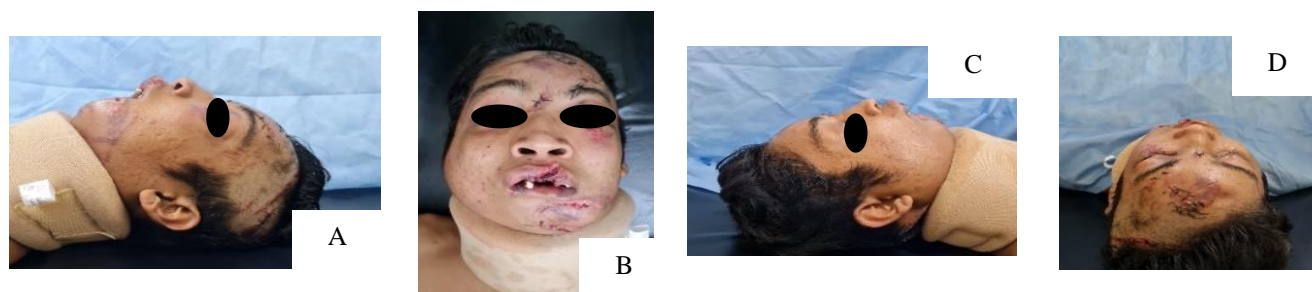

Figure 1: Extraoral clinical features. A) Left lateral aspect of the face, B). Anterior front aspect of the face, C). Exemplary lateral aspect of the face, D). The superior aspect of the face

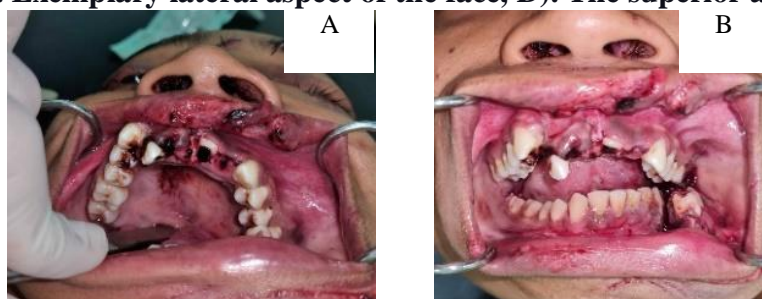


Figure 2: Intra oral clinical picture. A). Maxillary laceration, B). Overview of open bite mandibular maxillary occlusion

Hematological examination showed hemoglobin 12.5 g/dL (14-17.4 g/dL), hematocrit 36.8%, (41.5-50.4%), leucocyte counts 22.06 mm³ (4.40-11.30 mm³), erythrocytes 4.40 million/uL, (4, 50-5.90 million/uL), SGOT 136 u/L (15-37 u/L), SGPT 32 u/L within normal limits (0-55 u/L),

GDS 142 mg/dL (<140 mg/dL), Urea 43.6 mg/dL within normal limits (19-44 mg/dL), Creatinine 1 mg/dL normal (0.72-1.25 mg/dL). Covid-19 screening was performed with a rapid test with non-reactive results. Chest X-ray showed within normal limits (Fig. 3).

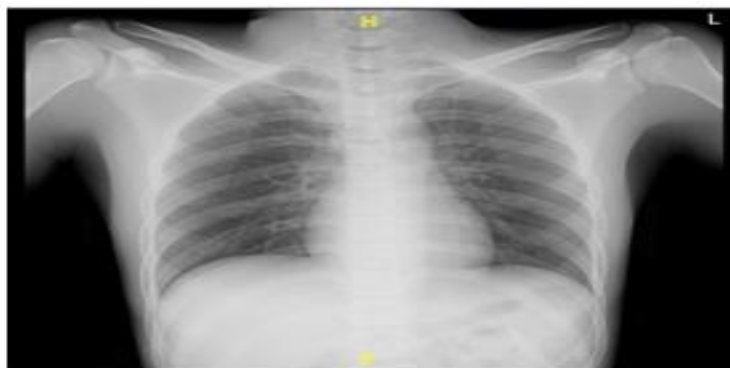

Figure 3: Chest X-ray

CT scan of the head showed discontinuity of the left maxillary bone, left zygomatic bone, right palate durum, and dentoalveolar with TMJ dislocation dextra, hematogenous, bilateral

ethmoidal, bilateral maxillary, right frontalis, and bilateral sphenoidal sinusitis, no intracranial hemorrhage (Fig. 4)

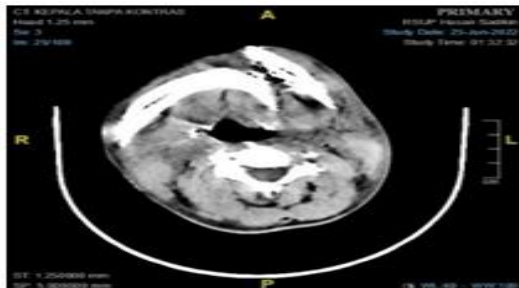


Figure 4: CT- Scan of the Head

3D facial CT scan showed discontinuities of the left maxillary bone, left zygomatic bone, right

palate durum, and dentoalveolar with right TMJ dislocation (Fig. 5).

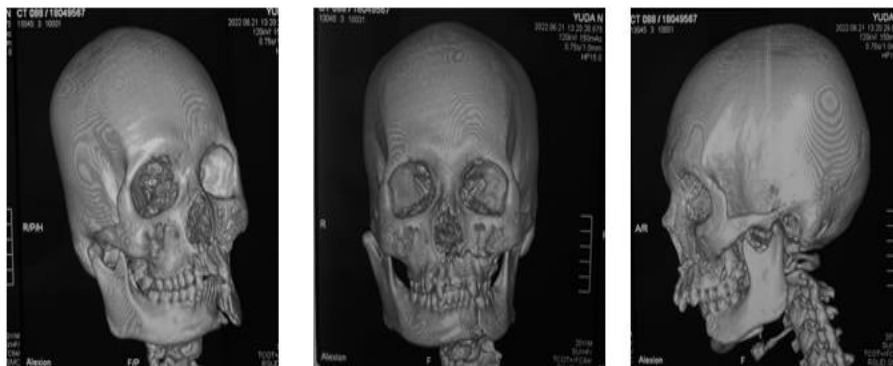


Figure 5: Gambar CT-Scan 3D

The diagnosis in this case was mild head injury, maxillary fracture sinistra, palate fracture type II, mandibular parasymphatic fracture sinistra, TMJ dislocation dextra, dentoalveolar fracture with avulsion of teeth 11,22, and intrusion of tooth 21, Vulnus lacerated regio labial superior, inferior, mentale, right occipital, gingiva of teeth 12-22 and 33-34 and palate.

Informed consent regarding all procedures and treatments that will be performed. Emergency measures taken by the neurosurgery department are observation of the patient's consciousness with GCS assessment and vital signs, 30-degree patient head position, oxygenation with nasal cannula 2-4 liters per minute, NaCl 0.9% infusion

1500 cc per day, and conservative non-operative treatment. While emergency measures from the Oral and Maxillofacial Surgery Department are in the form of oral wound care, tetragram injection, Ceftriaxone 1 gram antibiotic, Ketorolac 30 milligrams analgesic, the patient is admitted to the inpatient room.

After day 2, Open reduction internal fixation of the maxillofacial fracture was performed. The surgical procedure began with laceration debridement. Incisions were made through an intra-oral approach on the right. They left the maxilla and para-symphysis to identify the fracture fragments, install plate screws, and reposition the TMJ to obtain a normal position

and bring the fracture fragments closer. Insertion of quick-fix + IMF wire and simple wire (Ernst wiring mobile teeth ar 13-12 and eyelet wiring mandible regio 33-34 to bring fracture fragments closer) helped to reduce fracture fragments with guided occlusion. Straight plates and screws were placed with four holes, seven screws in the left para symphysis region, two pieces, as well as L plates with six holes, four screws in the maxillary sinistra region, and straight maxillary plates with

five holes, 12 screws three pieces in the maxillary anterior and sinistra regions. No plate was placed on the palate fracture because occlusion and stability had been achieved (Fig. 6).

The patient was observed in the inpatient ward for eight days. Oral hygiene was monitored, and eye and cheek area edema decreased daily. The patient was educated on a temporary liquid diet (Fig 7 and 8).

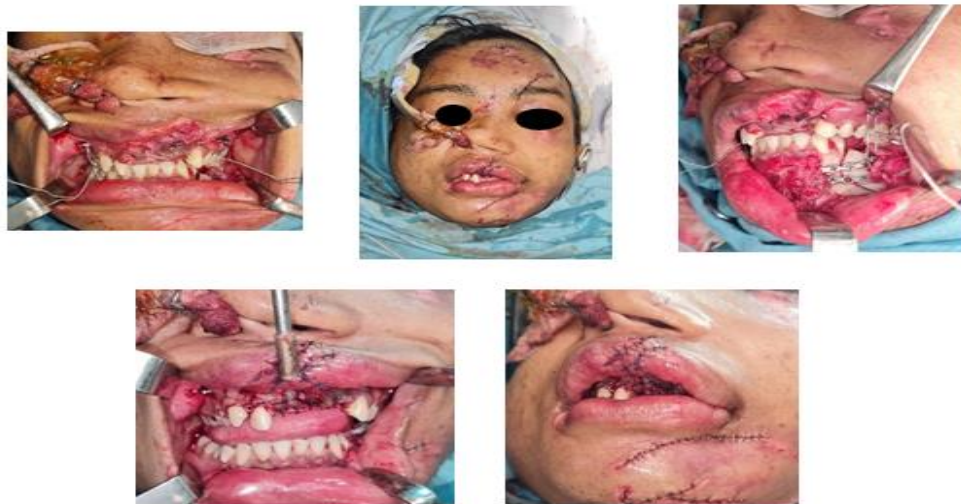

Figure 6: Intraoperative

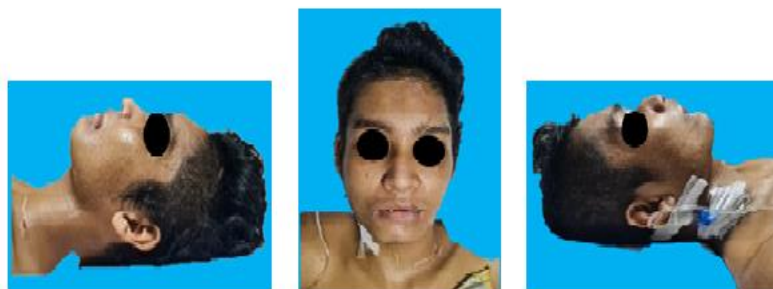

Figure 7: Post operative day 1-3

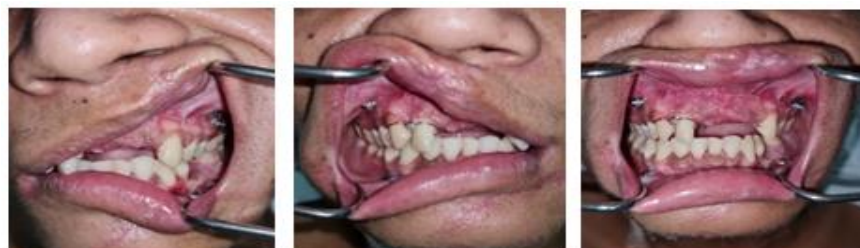

Figure 8: Post operative day 1 week

The patient was asked to check every week. The patient had no complaints, the right and left faces looked symmetrical, and the feeling of thickness in the cheeks was reduced. During the fourth week of control, the patient was checked for

maxillary and mandibular tooth contact occlusion. After that, the patient no longer complained of tooth contact, and the treatment was declared complete (Fig. 9).

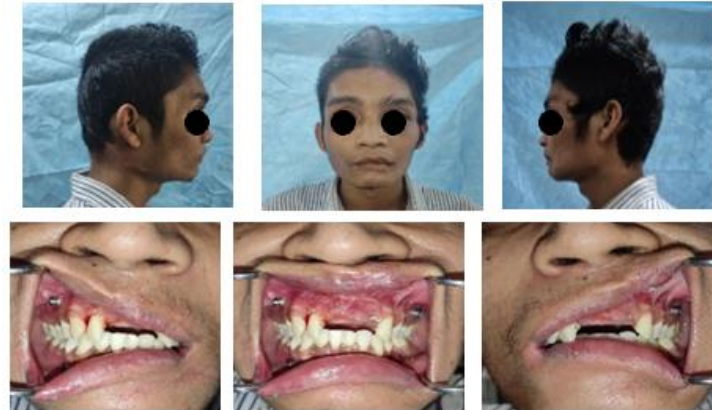

Figure 9: Post operative day 1 month

Discussion

Industrial accidents as a cause of maxillofacial trauma are around 2% by researcher Monteiro et al. 2019, and there are results up to 3% in research by Khan et al. 2022. The results of the study by Wusiman et al. 2020 were 4% in the sharp object trauma category. Subyakto et al. 2021 conducted research in Indonesia and found 2.02% in the category of workplace accidents.^{5,6,11,15}

Fractures can vary from simple fractures of the maxillary alveolar process to comminuted fractures of the entire mid-face area. The fracture pattern and distribution depend on the magnitude and direction of the force (frontal or lateral). This case is a multiple maxillofacial fractures with TMJ dislocation. The facial skeleton consists of four pairs of vertical and horizontal buttresses. Buttresses are thicker bony areas that support the functional units of the face (muscles, eyes, dental occlusion, airway) in an optimal relationship and determine the shape of the face by projecting the soft tissue sheath above it. Chen et al., 2011 found an association of TMJ dislocation with 60% trauma.^{11,12,16}

Complications of multiple maxillofacial fractures result in extensive bleeding and airway compromise due to displacement of fracture fragments, edema, and soft tissue swelling. Wound infection is less common than in open wounds of mandibular fractures. Infection from fractures that pass through the sinuses will not usually occur unless there is a previous obstruction. Le Fort II and III fractures of the cribriform region may also fracture, resulting in cerebrospinal fluid rhinorrhea. In addition, blindness may also occur due to hemorrhage in the dural membrane of the optic nerve. Late complications may include failure to fuse the fractured bones, incorrect fusion, lacrimal system obstruction, infraorbital anesthesia/hypoesthesia, dental devitalization, extraocular muscle imbalance, diplopia, and enoftalmus.^{6,10,15,17,18}

This patient underwent Open Reduction Internal Fixation (ORIF) using mini plates and screws for the maxilla and mandible and wire placement for the palatoalveolar fracture. ORIF is the gold standard in maxillofacial fracture management. Conservative management is performed when the fracture is stable, undisplaced, or asymptomatic, without occlusal disturbances or other functional problems. All management aims to restore occlusion function. TMJ reduction is performed

conventionally, as repositioning the mandibular fracture may involve repositioning the TMJ prior to fixation.^{9,18,19}

Temporomandibular joint dislocation is the detachment of the condyles from their normal position. The glenoid fossa is located in the squamous-temporal part of the skull base. It can be partial (subluxation), complete (luxation), bilateral or unilateral, acute, or prolonged chronic. In 60% of cases, the etiology of dislocation is due to trauma from falls, traffic accidents, domestic accidents, violence, and other causes such as excessive mouth opening during yawning, laughing, singing, and prolonged mouth opening.^{5,11,12,20,21}

TMJ dislocation may be associated with mandibular fracture. In this case, it was a lateral dislocation where the condylar head moved laterally and superiorly. It was palpated in the temporal space due to a violent impact on the mandibular symphysis. Treatment is by way of reduction of the hypocritical maneuver. However, contracture and shortening of the temporalis and masseter muscles will occur more than two weeks after the incident, making manual reduction difficult. Chronic and longstanding dislocation of the mandibular condyle due to forming a psudojoint with varying degrees of movement requires surgical treatment. Complications in chronic dislocations are limitations in opening or closing occlusion or malocclusion of the mandibular prognosis.^{9,18,20,22}

Conclusions

Multiple maxillofacial fractures accompanied by TMJ dislocation can result in deformity and loss of facial function affecting the patient's social life. The ORIF procedure performed in this case restored stomatognathic and facial function.

Reference

1. Sastrawan AD, Sjamsudin E, Faried A. Penatalaksanaan emergensi pada trauma oromaksilofasial disertai fraktur basis kranii anterior. *Majalah Kedokteran Gigi Indonesia*. 2017;3(2):111.
2. Dimitroulis G. Management of temporomandibular joint disorders: A surgeon's perspective. *Aust Dent J*. 2018; 63:S79–90.
3. Weinberg FM, Speksnijder CM, Forouzanfar T, Rosenberg AJWP. Articular soft tissue injuries associated with mandibular condyle fractures and the effects on oral function. *Int J Oral Maxillofac Surg*. 2019;48(6):746–58.
4. Wang D. Orthognathic surgery. Vol. 82, *Zhonghua yi xue za zhi*. 2017. 1702–1704 p.
5. Wusiman P, Maimaituerxun B, Guli, Saimaiti A, Moming A. Epidemiology and Pattern of Oral and Maxillofacial Trauma. *J Craniofac Surg*. 2020 Jul 1;31(5):e517–20.
6. Panigrahi B, Kumar Subudhi S, Lenka S, Biswas S, Trainee PG. Acute Management of Maxillofacial Trauma: A Review of Literature. Vol. 14, *Indian Journal of Forensic Medicine & Toxicology*.
7. Saigal S, Khan MM. Primary Assessment and Care in Maxillofacial Trauma. In: *Oral and Maxillofacial Surgery for the Clinician*. Springer Nature Singapore; 2021. p. 983–95.
8. Oberman B, Setabutr D, Goldenberg D. Traumatic dislocation of intact mandibular condyle into middle cranial fossa. *American Journal of Otolaryngology - Head and Neck Medicine and Surgery*. 2014 Mar;35(2):251–3.
9. Jose A, Nagori SA, Agarwal B, Bhutia O, Roychoudhury A. Management of maxillofacial trauma in emergency: An update of challenges and controversies. Vol. 9, *Journal of Emergencies, Trauma and Shock*. Medknow Publications; 2016. p. 73–80.
10. Al-Hassani A, Ahmad K, El-Menyar A, Abutaka A, Mekkodathil A, Peralta R, et al. Prevalence and patterns of maxillofacial trauma: a retrospective descriptive study. *European Journal of Trauma and Emergency Surgery*. 2022 Aug 1;48(4):2513–9.

11. Khan TU, Rahat S, Khan ZA, Shahid L, Banouri SS, Muhammad N. Etiology and pattern of maxillofacial trauma. *PLoS One*. 2022 Sep 1;17(9 September).
12. Abhinav RP, Selvarasu K, Maheswari G, Taltia A. The patterns and etiology of maxillofacial trauma in South India. *Ann Maxillofac Surg*. 2019 Jan 1;9(1):114–7.
13. Al-Hassani A, Ahmad K, El-Menyar A, Abutaka A, Mekkodathil A, Peralta R, et al. Prevalence and patterns of maxillofacial trauma: a retrospective descriptive study. *European Journal of Trauma and Emergency Surgery*. 2022 Aug 1;48(4):2513–9.
14. Maxillofacial trauma principles of management, priorities and basic techniques 1999.
15. Monteiro JLGC, de Arruda JAA, de Melo ARS, Barbosa RJV, Carneiro SC de AS, Vasconcelos BC do E. Updated Review of Traumatic Dislocation of the Mandibular Condyle Into the Middle Cranial Fossa. Vol. 77, *Journal of Oral and Maxillofacial Surgery*. W.B. Saunders; 2019. p. 132.e1-132.e16.
16. Chen I, Chang CM, Yuan-Chien Chen M, Chen KJ. Traumatic dislocation of the mandibular condyle into the middle cranial fossa treated by an intraoral approach. *Journal of the Formosan Medical Association*. 2019 Jul 1;118(7):1161–5.
17. Mohd Razi MR, Zamhari AK, Lee SW. Traumatic long-standing unilateral dislocation of TMJ - a case report. *Oral Surg*. 2016;9(1):35–9.
18. Renapurkar SK, Strauss RA. Temporomandibular Joint Trauma. Vol. 27, *Atlas of the Oral and Maxillofacial Surgery Clinics of North America*. W.B. Saunders; 2019. p. 99–106.
19. Kasma AS, Andi Tajrin, Hadira. Treatment of oromaxillofacial fracture in elderly: A literature review. *Makassar Dental Journal*. 2022 Aug 31;11(2):176–80.
20. Monteiro JLGC, de Arruda JAA, de Melo ARS, Barbosa RJV, Carneiro SC de AS, Vasconcelos BC do E. Updated Review of Traumatic Dislocation of the Mandibular Condyle Into the Middle Cranial Fossa. Vol. 77, *Journal of Oral and Maxillofacial Surgery*. W.B. Saunders; 2019. p. 132.e1-132.e16.
21. Manodh P, Prabhu Shankar D, Pradeep D, Santhosh R, Murugan A. Incidence and patterns of maxillofacial trauma—a retrospective analysis of 3611 patients—an update. *Oral Maxillofac Surg*. 2016 Dec 1;20(4):377–83.
22. Renapurkar SK, Strauss RA. Temporomandibular Joint Trauma. Vol. 27, *Atlas of the Oral and Maxillofacial Surgery Clinics of North America*. W.B. Saunders; 2019. p. 99–106.