

Oroantral Fistula: An Overview

Timotius Andi Kadrianto¹, Endang Sjamsudin²

¹Resident of Oral and Maxillofacial Surgery, Faculty of Dentistry, Universitas Padjadjaran, Bandung, Indonesia

²Staff of Department of Oral and Maxillofacial Surgery, Faculty of Dentistry, Universitas Padjadjaran, Bandung, Indonesia

Received: 05-05-2023 / Revised: 20-05-2023 / Accepted: 06-06-2023

DOI: <https://doi.org/10.32553/ijmbs.v7i6.2714>

Corresponding author: Timotius Andi Kadrianto

Conflict of interest: No conflict of interest.

Abstract

Oroantral fistula (OAF) is an abnormal connection between the oral cavity and the maxillary sinuses. This pathology develops when the oroantral communicant fails to close spontaneously; thus, it remains patent and epithelialized. If not treated immediately, this condition might be the passage for bacteria to enter the maxillary sinuses, causing infection, sinusitis, or delayed healing. Consideration of OAF therapy should consider the width of the defect, epithelialization, and whether or not there is an infection. This article aims to understand oroantral fistula and learn about the management of this case so that it can be applied scientifically in medical practice.

Keywords: Fistula, Oroantral, maxillary sinuses, oral cavity

Introduction

Oroantral fistula (OAF) is an abnormal condition with a connecting channel between the maxillary sinuses and the oral cavity.^{1,2} OAF is intended to denote channels lined by epithelium that can be filled by granulation tissue or sinus membrane polyposis and is often caused due to iatrogenic oroantral communication.² Another study describes OAF as an abnormal connection between the oral cavity and the maxillary sinuses. It develops when the oroantral communicant fails to close spontaneously and remains patent and epithelialized.³

Oroantral fistulas are more common in males than females.⁴ OAF is rare in children during tooth extraction due to permanent tooth buds and underdeveloped maxillary sinuses.⁵ Some rare causes of OAF include cysts on the upper jaw, which account for nearly 10%-15% of cases. In comparison, 5%–10% of these problems are related to benign or malignant tumors, and 2%–

5% are related to trauma.⁶ In another study, the overall incidence of simple and complex upper third molars extraction was reported at 5.1%. Previous studies reported second premolars as the highest risk for creating oroantral fistulas during extraction, unlike recent studies that reported molars having roots closest to the bottom of the sinuses.

The incidence of oroantral fistulas from the extraction of all posterior maxillary teeth varies from 0.31% to 3.8%. Complex extraction of the third molar of the upper jaw is reported to cause an incidence of 4.9% to 5%.⁵ If not treated promptly, OAF can act as a way for bacteria to enter the maxillary sinuses, causing infection, sinusitis, or delayed healing.⁷ Other studies showed that if oroantral fistula does not get immediate treatment, candida infection, chronic maxillary sinus infection of bacterial origin, osteomyelitis, and rhinosinusitis can occur.⁷

Wassmund's study reported sinusitis development in 60% of cases on the fourth day after the oroantral fistula. In comparison, Eneroth and Martensson et al. reported sinusitis rates of 50% on the third day after an oroantral fistula occurred. Surgical closure is strongly indicated in cases with larger oroantral fistulas and in patients with a history of sinus disease. Therefore, confirmation and early diagnosis of the oroantral fistula are mandatory to allow closure with successful surgical procedures.³ In order to prevent these complication, surgical closure of OAF within 48 hours is recommended.⁷

This article aims to understand oroantral fistula and learn about the management of this case so that it can be applied scientifically in medical practice.

II. Literature Review

1. Maxillary Sinus Anatomy

One of the organs in humans whose shape varies in each individual is the paranasal sinus. There

are four paranasal sinuses: maxillary sinus, frontal sinus, ethmoid sinus, and right and left sphenoid sinuses. The paranasal sinuses result from pneumatization of the head bones, thus forming cavities in the bones. Each sinus has an estuary (ostium) in the nasal cavity.^{7,8}

The maxillary sinuses, one of the first paranasal sinuses identified by the ancient Egyptians, have been well studied, especially the structure, anatomy of blood vessels, and their relationship to teeth.⁸ MS is pyramid-shaped and is the most prominent paranasal sinus. The anterior wall of MS is formed by the facial surface of the maxilla and internally grooved by the canalis sinuous (which houses the nerves and anterior superior alveolar vessels) (Figure 1). The anterior wall has three prominent landmarks, including:^{8,9}

1. Thin canine fossa
2. Infraorbital foramen located in the midsuperior region
3. Infraorbital groove

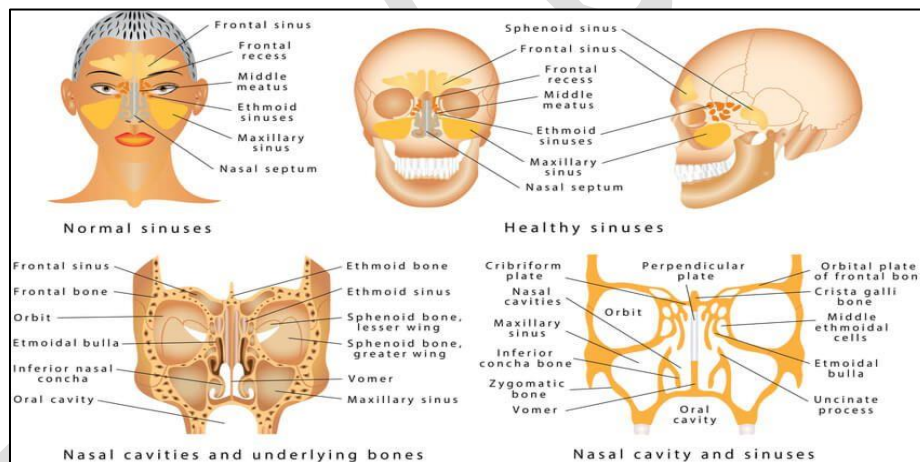


Figure 1: Maxillary sinus anatomy⁸

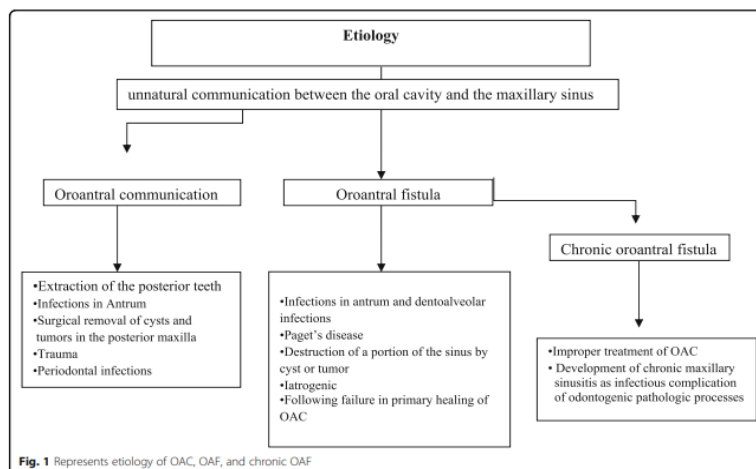
The infratemporal surface of the maxilla forms the posterior wall. It forms the anterior boundary of the pterygopalatine fossa. The superior wall is formed by a fragile triangular orbital floor, with infraorbital grooves running through it. The roof of the sine thickens towards the orbital margin, with an average thickness of 0.4 mm in the medial infraorbital channel and 0.5 mm laterally.^{8,10}

The vascular supply to the maxillary sinus originates mainly from the maxillary artery branches: the posterior superior alveolar artery, the infraorbital artery, and the posterior lateral nasal artery. The posterior superior alveolar artery (PSAA) can run along the medial wall of the sinuses. Infraorbital arteries pass through infraorbital grooves and channels, under the orbit, and finally through the infraorbital foramen on

the maxillary facial surface. PSAA and anastomosis of the infraorbital artery along the sinuses' anterolateral wall, supplying the nasal space's mucous membrane. Extraosseous anastomosis is often present between these two arteries. The posterior lateral nasal artery branches from the sphenopalatine artery and passes through the foramen of sphenopalatine to enter the nasal cavity and can be found within the medial wall of the sinuses. As it progresses anteriorly, the posterior lateral nasal artery begins to branch, supplying blood to the posterior and medial walls of the sinuses.^{8,9,10}

2. Etiology of oroantral fistula

Oroantral fistulas are usually associated with implant surgery, tooth extraction, infection, sinusitis, osteomyelitis, trauma, and iatrogenic complications (Figure 2). Another factor is that alveolar bone resorption due to periodontal disease can stop the stabilization of blood clots after tooth extraction. Sinusitis, antral polyps, antral herniation. However, most OAFs may be undiagnosed at the time of the event if these risk factors are unknown⁵



3. Medical History of Fistulas

Medical history identifies patients with a higher risk of causing complications during or after closure. Cardiovascular disease, diabetes, kidney failure, and hematological disorders can increase the risk of complications such as bleeding, infection, and delayed tissue healing.⁹ In patients with a history of trauma, removal can destroy the bone barrier between the oral cavity and the maxillary sinuses, giving rise to oroantral fistulas.¹⁰

The most common causes of oroantral communications are dental implant surgery and posterior maxillary tooth extraction.¹ Other diseases that cause oroantral fistulas are infections, iatrogenic injuries, inflammatory conditions, Paget's disease, and neoplasms. Other patients have had an old posterior maxillary tooth

extraction or posterior maxillary molar whose roots are close to the base of the sinuses. They came with radiographic signs of the molar root of the upper jaw, which is too large or close to the base of the sinuses. Older individuals have large rounded roots with significant bone expansion and possible fractures of the base of the sinuses. In addition, patients who experience loss of lamina dura in the posterior maxillary teeth to be extracted may have a higher chance of OAF.⁶

4. Symptoms and Clinical Signs

Air and fluids entering the nose and mouth are the main clinical findings after forming oroantral communication (OAC). Usually, patients complain of symptoms of unpleasant salty discharge into the mouth, bad smell in the mouth, reflux of fluids and food into the nose from the mouth, and air leakage that sometimes makes it

difficult to smoke. Patients also experience impaired voice resonance and speech problems if there are significant defects. Patients usually complain of difficulty sucking through straws and unilateral nasal secretions. Pain can appear in the malar region.³

The presence of one or more of the symptoms mentioned above can be a sign of OAC or fistula, while some patients may be asymptomatic if the defect is too small or covered by a large polyp.¹¹ Most oroantral fistulas go undetected and can heal spontaneously if less than 3-5 mm in diameter. If a larger OAC is not recognized and management is not performed for closure, then the OAC can evolve into an OAF. The literature also says sinusitis will occur if the OAC is not closed within 24-48 hours.¹²

5. Physical Examination

On clinical examination may be found:¹²

1. Bubbles of mucus or blood may be seen when the patient exerts pressure through closed nostrils (Valsalva maneuver).
2. The patient may feel oronasal regurgitation or leakage of oral fluid through the nose if it retains water in the mouth.
3. Unilateral epistaxis of the affected side may occur.
4. Close examination of the apex socket under direct light vision can show the sinuses' lining or the sinuses' opening.
5. OAC should be suspected if a portion of the antral floor attaches to the root tip after extraction

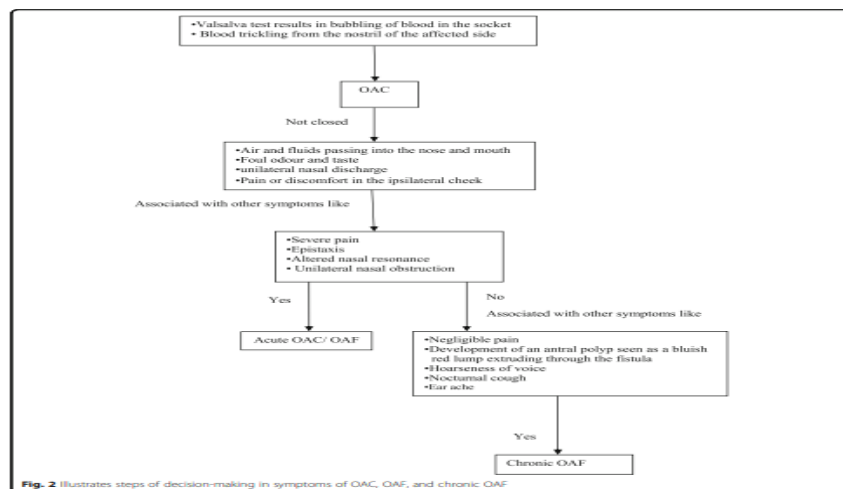


Figure 3: Clinical Signs, Physical Examination and Diagnosis Enforcement⁹

In the later stages, antral polyp formation occurs which is seen through intra-oral defects. However, some patients may be asymptomatic. Clinically, large fistulas are easily visible on examination. However, diagnosis of minor defects is made with a nasal blow test. The patient is asked to close his nostrils and blow lightly with his mouth open. The presence of an oroantral fistula will appear as a whistling sound when air passes through the fistula into the oral cavity. The presence of air bubbles, blood, or mucoid secretions around the hole can also be seen. The exit of air through the nostrils can be

tested by placing lumps of cotton near the hole. A mouth mirror placed on an oro-antral fistula causes mirror fog.^{3,9}

6. Supporting Examination

To ensure clinical findings, doctors must perform radiological examinations through panoramic radiography or computed tomography (CT). Dental tomography provides precise data on the perforation and its size if the defect is closed by polyposis or granulation tissue (figure 4).¹¹ Probing (inserting a probe into the antrum through a fistula) should not be performed.

Panoramic radiography accurately estimates the dimensions of bone defects in fistulas. Also, it shows the location of tooth roots, implants, or

foreign bodies that may have slipped into the antrum. Computed tomography can be done to rule out the presence of maxillary sinusitis.³

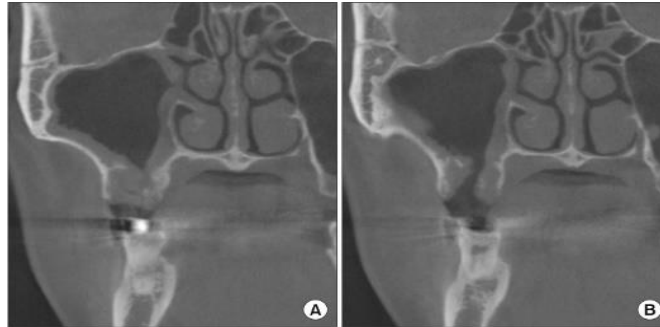


Figure 4: CT-Scan (a) connected tract (b) right maxillary sinus infection¹

7. Management

The right therapy choice should consider the defect's width, epithelialization, and whether or not there is an infection. Defects less than 3mm wide and without epithelialization can heal spontaneously without infection. However, if there is an infection, it must be cured before surgery to avoid drainage disorders. In OAC, that is wider than requires rotation and sliding flaps to perform closure. Various treatments for OAF have been recommended in the literature. Visscher et al. categorized surgical treatment

modalities for OAF closure into autogenous soft tissue, bone grafts, allograft, xenograft, synthetic materials, and other techniques.¹³

The principle in the management of oroantral fistulas is the first principle that the sinuses must be free from all types of infections with the availability of nasal drainage. The second principle is that closure must be tension free and based on soft tissue to have a rich vascularity flap over intact bone.⁶ The therapy choice algorithm can be seen in Figure 5 below.

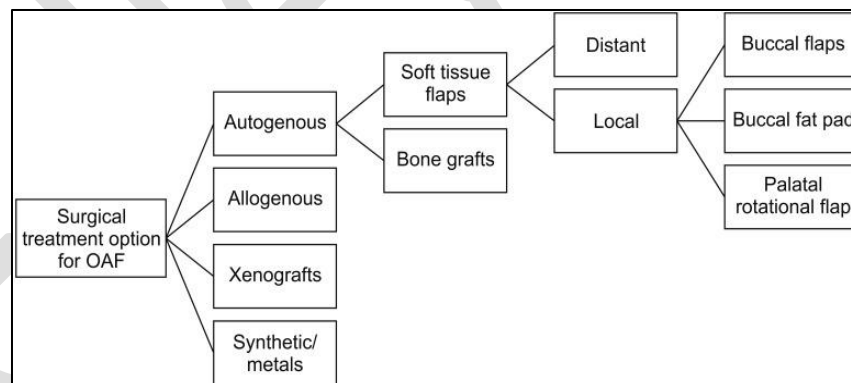


Figure 5: Surgical treatment option for OAF¹

When there are signs and symptoms of sinusitis, sinus treatment is carried out first. Some researchers recommend: Antibiotics: amoxicillin/clavulanic acid two times daily, clindamycin 300 mg 4 times daily, or

moxifloxacin 400 mg once daily for at least ten days combined with decongestants and sinus drainage with physiological serum via OAC.¹⁴ Management of sinusitis can be seen in Figure 6 below.

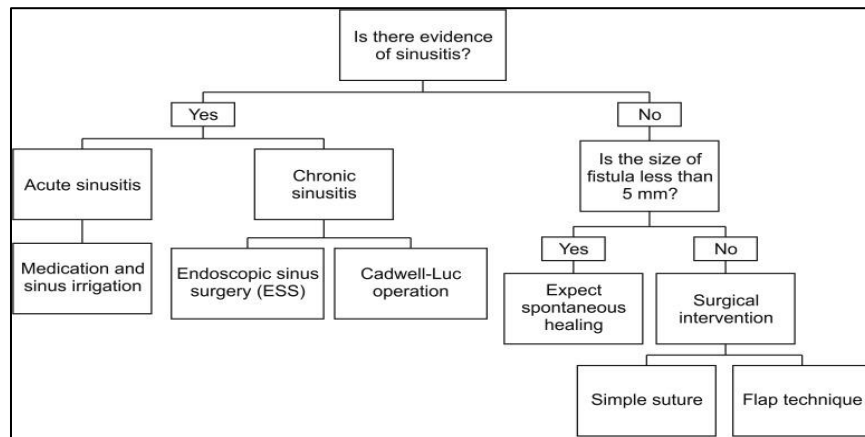


Figure 6: Management of Sinusitis in OAF¹

8. Perioperative care

Before surgery, the affected maxillary sinus should be irrigated through the fistula hole with normal saline with a solution containing iodine diluted using normal saline (1:1). This regimen should be given until the lavage liquid becomes clear and there is no exudate.³

9. Operative Techniques

Not all oroantral fistulas require surgical treatment. Defects which is less than 3 mm, tend to close naturally without any surgery. However, defect which is more than 3 mm requires surgical treatment. Two basic principles should be

followed and considered in the surgical treatment of OAF.¹

a. Buccal Flap

This technique can be used to close oroantral fistulas. This technique is suitable for small children and defects of medium volume.¹⁴ This technique consists of modifying the vestibular flap to avoid a decrease in the vestibular sulcus. After cutting the edge, two vertical incisions are made to provide the flap with dimensions suitable for the closure of antral communication. In this procedure, a broad-based trapezoidal mucoperiosteal flap is created and sutured over the defect (figure 7).⁴

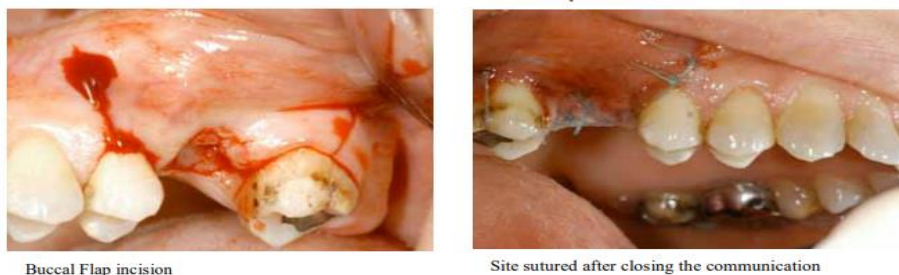


Figure 7: Left : Buccal flap incision; right : Suturing after OAF closure³

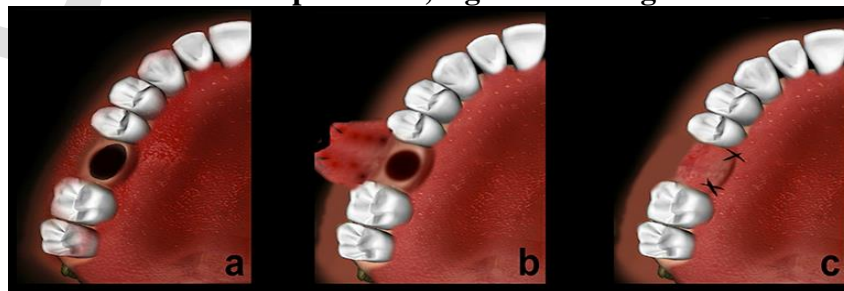


Figure 8: Buccal Flap Illustration¹¹

Its broad base guarantees an adequate blood supply resulting in a high success percentage (93%).¹⁵ Blood supply is sufficient. Thus, a high success rate has been reported in the literature concerning this technique.¹⁴ However, this flap technique also presents disadvantages, the risk of reduction in the depth of the buccal sulcus and postoperative pain and swelling. Loss of vestibular depth is a severe problem requiring additional vestibuloplasty in patients wearing removable dentures. The depth of the buccal sulcus may decrease after surgery, likely resulting in increased discomfort among patients using dentures. Some researchers have suggested that implantable overdentures could be an option to address this problem associated with a reduction in the depth of the buccal sulcus.^{14 15}

a. Palatal Flap

Ashley was the first to explain the OAF closure technique using a full-thickness palatal flap. The

epithelium is cut from the edges, incision of the palatal fibro-mucosa is performed to remove the flap having a posterior base, which is supplied by the major palatine artery. The anterior flap should be wide enough to exceed the diameter of the bone defect and long enough to allow lateral rotation (figure 9). Tension-free sewing should be done. However, palatal flaps can only be performed in cases of fistula closure in the premolar region. In the molar region, excessive tension can cause ischemia in the flap due to occlusion of the major palatine artery.³

The advantages of palatal flaps include high vascularity, thickness, and adequate tissue quality. The most severe disadvantage is flap necrosis, which can occur due to excessive flap rotation. Other disadvantages of this technique include exposed bone surfaces, pain, and surface irregularities that may develop due to postoperative secondary epithelialization.^{3,4 13}

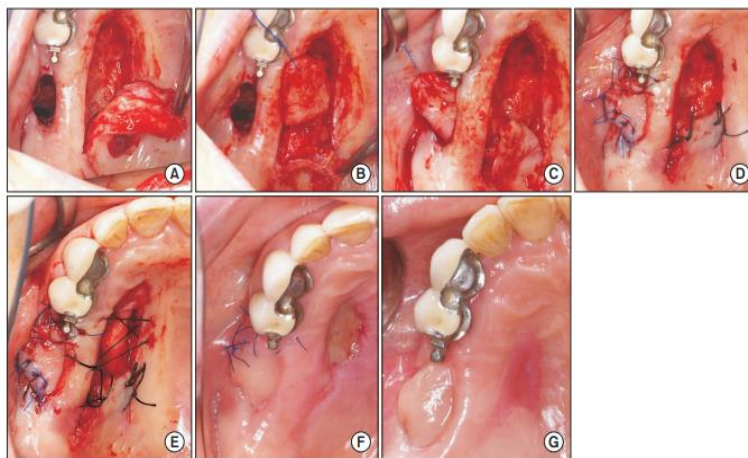


Figure 9: Palatal Flap³

b. Buccal Pad Of Flat Flap

A buccal fat pad is a form of lobed fat tissue wrapped by a thin fibrous capsule, qualifying as an alternative to OAF closure. The buccal fat pad obtains its blood supply from the buccal and temporal branches of the maxillary artery, the transverse branch of the superficial temporal artery, and branches of the facial artery. BFP retrieval can be performed by a vestibular incision in the maxillary tuberosity area, followed

by blunt dissection under the buccal flap periosteum and gentle traction of fat to the recipient site.¹

The advantage of this technique is that buccal pads provide an excellent epithelialization rate and low failure rate. The disadvantages of this technique are decreased vestibular height, necrosis, and the recurrence rate of fistulas, so it requires a second surgery to achieve closure.^{4,13}

c. Autogenous Bone Grafts

Proctor first proposed bone grafts taken from iliac crista to close large OACs in 1969. After placing the bone graft, soft tissue closure is performed with a Rehrmann buccal flap. In recent years demand has increased as alternative donor areas have been investigated, including bone grafts from the retromolar region, zygomatic processes, and chin.¹⁵ It was abandoned due to the additional costs and comorbidities associated with this technique. Haas et al. recommend using bone grafts with monoblock's for OAC closure.¹⁴

The disadvantages of this technique require a second surgical procedure for bone retrieval. This second procedure prolongs surgical time and improves patient morbidity, prolonged postoperative pain, and possible sensory impairment.¹⁵

d. Allogeneous Materials

Some studies have achieved closure of OAF with lyophilized fibrin glue. The preparation of lyophilized fibrin glue takes about 15 to 20 minutes. The lyophilized fibrin glue is then applied to the socket with a syringe and the collagen sheet. After that, the mouth's surface is covered with the remaining fibrin glue. After 2 hours, the glue has reached its maximum strength. The advantage of this technique is that the intraoral anatomy remains intact. The disadvantages of this technique are the small risk of transmission of viral hepatitis and the preparation time required for fibrin glue.¹⁵

e. Xenograft

Mitchell, Lamb, and Shaker et al. used lyophilized dermis porcine to close oroantral perforations. Shaker et al. placed buccal and

palatal flaps on top of pig collagen. Both groups reported good results. Collagen does not have to be removed because fibrous tissue eventually replaces it. Nevertheless, it still takes quite a long time to allow mucosal overgrowth in communication. Ogunsalu has described the new surgical management. Ogunsalu used Bio-Guide (pig collagen membrane) and Bio-Oss (bovine bone grafting) to close fistulas in 1 patient. The mucoperiosteal full-thickness flap is then removed, and a Bio-Oss–Bio-Guide sandwich is placed underneath. Then the flap is repositioned, resulting in primary closure. The healing went smoothly in this patient. According to researchers, radiographs showed bone healing from defects eight months after closure, allowing the placement of endosseous implants. The disadvantages of this technique are the need for a mucoperiosteal cover to cover the sandwich and a long time for the healing process. The advantage of this technique is that bone and soft closure can be done without surgery at the donor site.¹⁵

f. Synthetic Closure Synthetic Closure

Gold foil or gold plate for OAF closure is applied in place with edges on healthy bones. It acts as a bridge for the overgrowth of the sinus mucosa (Figure 11). The mucoperiosteal flaps, which are raised to expose the edges of the bones from the defect, are sewn on gold foil without attempting to perform primary closure. In general, gold foil peels off after six weeks. Solid hydroxyapatite has also been used to seal OAF.^{15,16}

The disadvantages of using gold are a rather expensive cost and a relatively long time for closure and complete healing. The advantages of using aluminum are its malleability, softness, and low cost compared to gold.^{15,16}



Figure 11: Placement of gold plate over fistula and flap was repositioned over the gold foil without tension¹⁶.

III. Discussion

Diagnosis determines the subsequent treatment of each patient. It is based on a comprehensive evaluation of the patient's dental examination and medical history.⁹ In some cases, a blow test through the nose or mouth does not give a positive result, especially when the fistula duct is filled with inflammation, thereby changing the mucous membrane of the nose. However, to confirm clinical findings, clinicians need to examine the location through panoramic radiography or computer tomography (CT) radiologically, in computed tomography (CT) or cone beam computed tomography (CBCT).¹¹ Oroantral fistulas may show an essential sinus discontinuity, sinus opacity, or communication between the oral cavity and sinuses. In addition, focal alveolar atrophy and associated periodontal disease can be observed.¹⁶

Periapical film or panoramic radiography can give you an idea of the size of bone defects from OAC and OAF. Periapical radiography provides detailed information about radiographic changes in bone. The maxilla and communicant sinuses can be visualized with occipitomental and panoramic radiography.⁹ Computed tomography (CT) scans and cone beam computed tomography (CBCT) are the gold standard radiological assessment modalities to rule out maxillary sinusitis.¹⁰

Recent studies reveal that oroantral fistulas should be closed within 24 hours. After this period, the sinuses' inflammation may occur through oral cavity contamination, so it is impossible to carry out the treatment effectively.

¹⁴ Symptoms associated with inflammation of the sinuses should be medically cured with antibiotics prior to closure (OAF) to avoid impaired drainage. Different authors say small fistulas heal spontaneously, whereas large fistulas rarely heal. Surgery is indicated if the fistula does not heal in time.¹⁶

Given the different interventions available to cover OAF, it is crucial to identify the best intervention techniques to help manage the patient. The choice of procedure is controversial.¹⁴ Most surgeons prefer buccal or palatal flaps if the soft tissue's primary suturing cannot correctly close the oroantral fistula. Others claim that palatal flaps are preferred because of their adequate blood supply. A review of the literature on the advantages of palatal flaps reveals that vascularization is abundant, has sufficient thickness, and is resistant to lacerations. Due to the continued need for implant rehabilitation, OAF bone closure is increasingly used in oroantral fistula closure.¹⁶

Closure of OAF with bone grafts by implant surgery in case of removal of sinuses. However, autogenous bone grafting has several drawbacks, including needing a second surgical procedure to remove the bone and concerns about donor morbidity. Therefore, other graft materials have been investigated for OAF closure. The mechanical properties, biological behavior, and biodegradation mechanisms vary for different graft materials. Unlike allografts or xenografts, alloplastic or synthetic materials naturally limit the risk of cross-transmitting pathogenic infections. Alloplastic materials are easy and

simple; However, their drawbacks include being time-consuming and cost-effective and requiring exfoliation, which may limit their use as an alternative surgical technique for OAF closure. More recently, using platelet-rich fibrin for OAF

closure is a simple, inexpensive, and possibly effective method to close OAF. However, it requires more evidence-based data. 16 The following figure is for consideration in OAF management (figure 12).^{14,15,17}

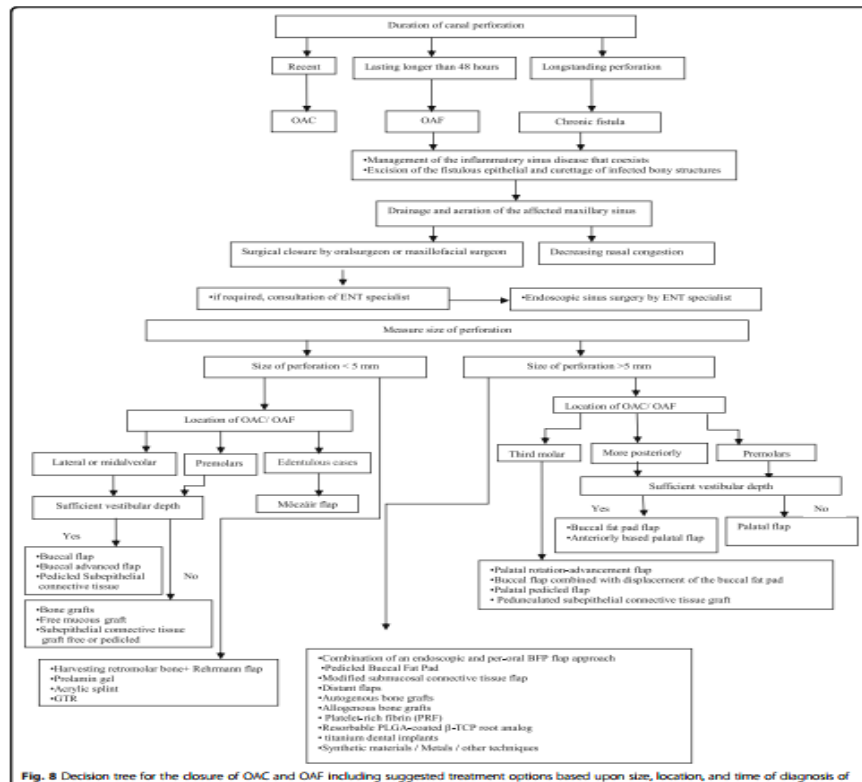


Fig. 8 Decision tree for the closure of OAC and OAF including suggested treatment options based upon size, location, and time of diagnosis of

Figure 12: Therapy Selection⁹

IV. Conclusion

Repairing oroantral fistulas is one of the most challenging problems in oral and maxillofacial surgery. In choosing a surgical approach to close the oroantral fistula, different criteria should be considered, such as the location of the defect, the size of the defect, the height of the alveolar ridge, vestibular depth, persistent defects, inflammation or sinus infection, and the patient's general health. OAF should be treated promptly by creating a barrier between the oral cavity and the maxillary sinuses to prevent maxillary sinusitis. Treatment modalities to correct oroantral defects include local or free soft tissue flaps, with or without autografts or alloplastic materials. Buccal flaps are suitable for the closure of small and mesial

fistulas; Palatal flaps are a viable option for correcting OAF, more likely for abnormalities in the premolar area. A buccal fat pad is suitable for large posterior OAF closure.

Currently, there is no best treatment or consensus regarding OAF. Each technique has advantages and disadvantages. The choice of method should be made on a case-by-case basis, considering all factors related to the action and the patient. According to Visscher et al., the ideal treatment for OAF is fast, safe, simple, and well-tolerated by patients at a low cost, resulting in good bone and mucosal healing.

References

1. Kwon MS, Lee BS, Choi BJ, et al. Closure of oroantral fistula: A review of local flap

- techniques. *J Korean Assoc Oral Maxillofac Surg.* 2020;46(1):58-65. doi:10.5125/jkaoms.2020.46.1.58
2. PAULY G, KASHYAP R, SHETTY R, KINI R, RAO P, R G. Oro-Antral Fistula: Radio-diagnostic lessons from a rare case. *Am J Diagnostic Imaging.* 2017;1(1):21. doi:10.5455/ajdi.20170616123139
 3. Khandelwal P, Hajira N. Management of oro-antral communication and fistula: various surgical options. *World journal of plastic surgery.* 2017 Jan;6(1):3.
 4. Borgonovo AE, Berardinelli FV, Favale M, Maiorana C. Surgical options in oroantral fistula treatment. *The open dentistry journal.* 2012;6:94.
 5. Benlance E, SAHEEB BD. Incidence and risk factors of oroantral perforation following tooth ex-traction among Nigerian population in a tertiary hospital: a ten-year retrospective study. *Iraqi Dental Journal.* 2019 Jun 6;41(1):1-7.
 6. Yilmaz S, Calikoglu EO, Kosan Z. for an Uncommon Neurosurgical Emergency in a Developing Country. *Niger J Clin Pract.* 2019;22:1070-1077.
 7. Shahrour R, Shah P, Withana T, Jung J, Syed AZ. Oroantral communication, its causes, complications, treatments and radiographic features: A pictorial review. *Imaging Science in Dentistry.* 2021 Sep;51(3):307.
 8. Iwanaga J, Wilson C, Lachkar S, Tomaszewski KA, Walocha JA, Tubbs RS. Clinical anatomy of the maxillary sinus: application to sinus floor augmentation. *Anatomy & cell biology.* 2019 Mar 1;52(1):17-24.
 9. Parvini P, Obreja K, Begic A, Schwarz F, Becker J, Sader R, Salti L. Decision-making in closure of oroantral communication and fistula. *International journal of implant dentistry.* 2019 Dec;5(1):1-1.
 10. Al-Juboori MJ, Al-Attas MA, Magno Filho LC. Treatment of chronic oroantral fistula with platelet-rich fibrin clot and collagen membrane: a case report. *Clinical, Cosmetic and Investigational Dentistry.* 2018 Nov 8:245-9.
 11. Dergin G, Emes Y, Delilbası C, Gurler G. Management of the Oroantral Fistula. *A Textbook of Advanced Oral and Maxillofacial Surgery.* 2016 Aug 31;3(2016):3367.
 12. Bonanthaya K, Panneerselvam E, Manuel S, Kumar VV, Rai A, editors. *Oral and Maxillofacial Surgery for the Clinician.* Springer Singapore; 2021.
 13. Kwon MS, Lee BS, Choi BJ, Lee JW, Ohe JY, Jung JH, Hwang BY, Kwon YD. Closure of oroantral fistula: a review of local flap techniques. *Journal of the Korean Association of Oral and Maxillofacial Surgeons.* 2020 Feb;46(1):58.
 14. Konate M, Sarfi D, El Bouhairi M, Benyahya I. Management of Oroantral Fistulae and Communications: Our Recommendations for Routine Practice. *Case Reports in Dentistry.* 2021 Dec 14;2021.
 15. Visscher SH, van Minnen B, Bos RR. Closure of oroantral communications: a review of the literature. *Journal of oral and maxillofacial surgery.* 2010 Jun 1;68(6):1384-91.
 16. Steiner M, Gould AR, Madion DC, Abraham MS, Loeser JG. Metal plates and foils for closure of oroantral fistulae. *Journal of oral and maxillofacial surgery.* 2008 Jul 1;66(7):1551-5.
 17. Parvini P, Obreja K, Sader R, Becker J, Schwarz F, Salti L. Surgical options in oroantral fistula management: a narrative review. *International Journal of Implant Dentistry.* 2018 Dec;4(1):1-3.