

## MANAGEMENT OF ODONTOGENIC INFECTION OF PRIMARY TEETH IN CHILD THAT EXTENDS TO THE SUBMANDIBULAR AND SUBMENTAL SPACES

Endang Sjamsudin<sup>1</sup>, Lucky Riawan<sup>2</sup>, Winarmo Priyanto<sup>3</sup>

<sup>1,2,3</sup> Department of Oral and Maxillofacial Surgery, Faculty of Dentistry, Universitas Padjadjaran / Hasan Sadikin Hospital, Bandung, West Java, Indonesia

**Article Info:** Received 15 June 2021; Accepted 03 August 2021

**DOI:** <https://doi.org/10.32553/ijmbs.v5i8.2051>

**Corresponding author:** Dr.Endang Sjamsudin, drg.Sp.BM

**Conflict of interest:** No conflict of interest.

### Abstract

Odontogenic infections are infections originating from the teeth or the supporting tissues of the teeth. This infection can spread to the alveolar processes, the deeper tissues of the face, oral cavity, head, and neck. Infections that spread to a child's facial area can progress rapidly, producing significant systemic symptoms, such as fever, malaise, dehydration, dysphagia, and respiratory distress. The purpose of this case report is to describe the management of odontogenic infection of primary teeth in child that extends to the submandibular and submental spaces. **Case Report:** A 5-year-old boy patient came to the Emergency Department of Hasan Sadikin Hospital Bandung with complaints of swelling in the right submental and submandibular for seven days. The patient complained of toothache, fever, and trismus. The diagnosis of this case was submandibular abscess extending to the submental area due to dental infection 85. Patient care includes administering Ceftraxone inj 325 mg IV, Metronidazole inf 170 mg IV, Paracetamol inf 195 mg IV, tooth extraction 85, drainage incision through and through the right mandibular to submental, and installation of a Penrose drain. **Conclusion:** Odontogenic infections in children can originate from primary teeth and can extend to the maxillofacial space. Prompt and appropriate treatment of severe odontogenic infections in children needs to be done to prevent further complications

**Keywords:** Submandibular abscess, submental, drainage incision, odontogenic infection, maxillofacial space

### Introduction

Odontogenic infections are infections originating from the teeth or the supporting tissues of the teeth. Odontogenic infections can occur when oral microbes become pathogenic after translocation of teeth or their supporting structures, resulting in deep caries, pulpitis, and periodontitis. This infection can spread to the alveolar processes, deeper tissues of the face, oral cavity, head, and neck.<sup>1,2</sup> Odontogenic infections are one of the most common infections in the oromaxillofacial area, especially in developing countries.<sup>2,3,4,5</sup> Infections that affected the maxillofacial area in various parts of the world range from 50-89%.<sup>6</sup> The results of the Peking study showed that around 57,5% of odontogenic infections spread to the maxillofacial space.<sup>7</sup>

The incidence of odontogenic infections by sex and age varies in different countries. One study showed that odontogenic infections in women (52.9%) and preschool children (58.2%).<sup>8</sup> Many studies have stated that caries are common in children and can be a source of infection.<sup>1,9</sup> Odontogenic infections are polymicrobial,<sup>10</sup> with aerobic and anaerobic bacteria such as alpha-hemolytic Streptococcus, Peptostreptococcus, Peptococcus, Eubacterium, Bacteroides (Prevotella) melaninogenicus, and Fusobacterium. Infections that spread to the child's facial area can progress rapidly, producing significant

systemic symptoms, such as fever, malaise, dehydration, dysphagia, and respiratory distress.<sup>4,9</sup>

The most common source of spread of odontogenic infection was periapical infection (60.3%), followed by pericoronitis (27.4%), from the mandible (95.9%), from the molars (97.3%). The space involved in the spread of odontogenic infection most often involves the submandibular<sup>4,9,10</sup> approximately 54.6%.<sup>7</sup> In children, the source of infection is generally the posterior deciduous teeth (84%). The teeth most commonly affected were the primary first molars (34%), followed by the primary second molars (31%).<sup>9</sup>

Clinical manifestations depending on the space involved include fever, pain, fatigue, swelling, malaise, odynophagia, dysphagia, dyspnea, otalgia, trismus.<sup>4,10,11</sup> Research in Peking, in children, the common symptom is pain (62.1%), intraoral swelling (37.9%), and spontaneous pus from the teeth and surrounding tissues (67.3%), with higher involvement of the right primary molars.<sup>8</sup> Severe and widespread odontogenic infection can cause complications such as airway obstruction, mediastinitis, necrotizing fasciitis, cavernous sinus thrombosis (CST), sepsis, thoracic empyema, cerebral abscess, and osteomyelitis, and can even cause death.<sup>3,6,7</sup> Therefore, severe infections need

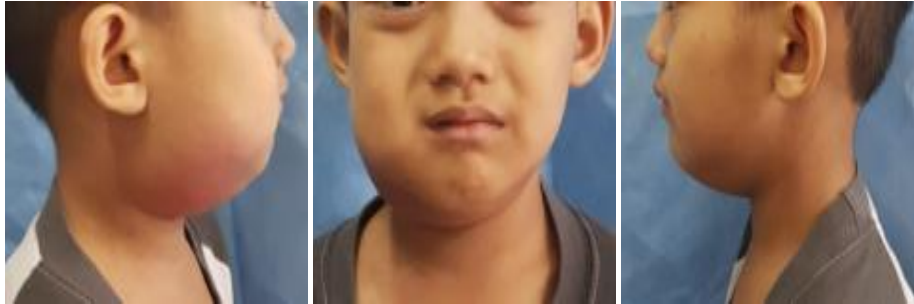immediate and appropriate treatment, such as antibiotics, analgesics, incision and drainage, and hospitalization.<sup>1,7,11</sup>

Assessment should focus on developing complications such as airway compromise, space involved, exact etiology of infection, and identification of symptoms of sepsis.<sup>3</sup> In children, unlike adults, the anatomic location of various infections is considered a valuable guide to diagnosis and management.<sup>9</sup> The main goal of treatment is to control and eliminate the causative agent and treat complications that occur, which require special care from a pediatrician and hospitalization.<sup>11</sup> This case report describes managing an

odontogenic infection in a child that extends to the submandibular and submental spaces—originating from a primary tooth infection.

### Case Report

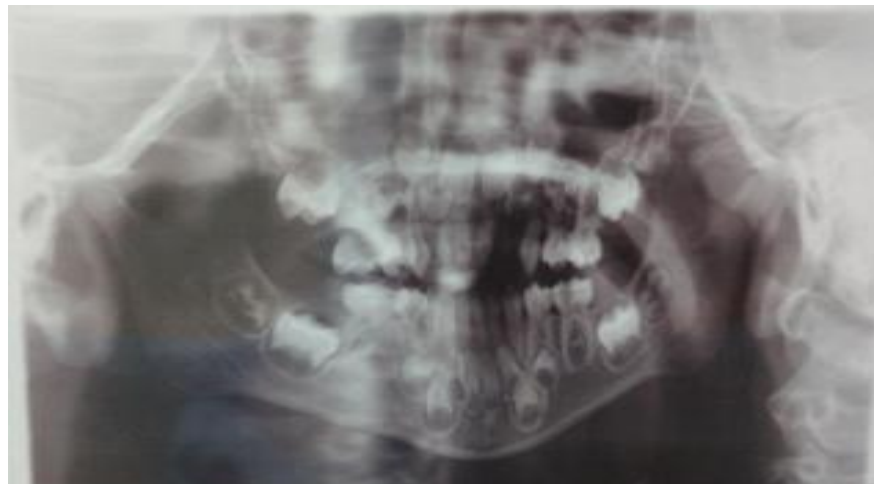A 5-year-old boy patient came to the Emergency Installation of Hasan Sadikin Hospital Bandung with complaints of swelling in the right lower jaw since seven days ago. The patient complained of swelling of the right lower jaw getting bigger and extending to the chin accompanied by pain, fever, and painful swallowing. Previously, the patient had toothache in the right lower jaw.



**Figure 1: Facial profile with swelling in the right cheek, submandibular and submental regions**

Examination of vital signs showed a Visual Analogue Scale (VAS) 3/10, compos mentis consciousness, pulse 106x/minute, temperature 38.1°C, respiration 30x/minute, and SpO<sub>2</sub> 98%. Extraoral examination of the face showed facial asymmetry, swelling of the right lower jaw that extended to the submental area with a size of 5x5x3 cm, reddish color, feverish temperature, localized, fluctuating, and painful palpation (Figure 1). Intraoral examination revealed generalized hyperemia of the gums and moderate

calculus in all regions. Odontogram showed tooth roots 51,52, 61, 62, media caries 54,55, 74, and tooth pulp necrosis 85. The patient's mouth opened about 2.5 cm. Routine blood laboratory examinations showed an increase in the number of white blood cells by 24,480 mm<sup>3</sup> and platelets by 476,000 mm<sup>3</sup> and a decrease in the levels of Serum Glutamic Pyruvic Transaminase (SGPT) 9 U/L and creatinine 0.42 mg/dL



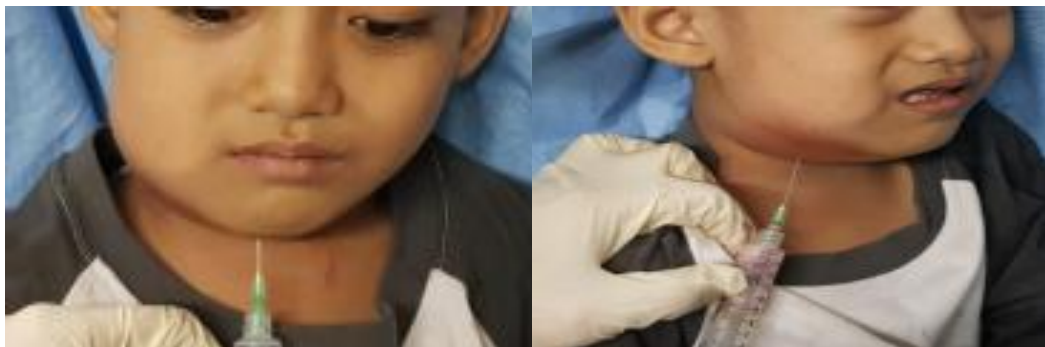**Figure 2: panoramic photo of jaw**

The results of the panoramic photo show a radiolucent image in the area of the root of tooth 85 (Figure 2). The diagnosis of this case was a submandibular abscess extending to the submental area due to infection of tooth 85. Patient care includes administration of Intravenous fluid

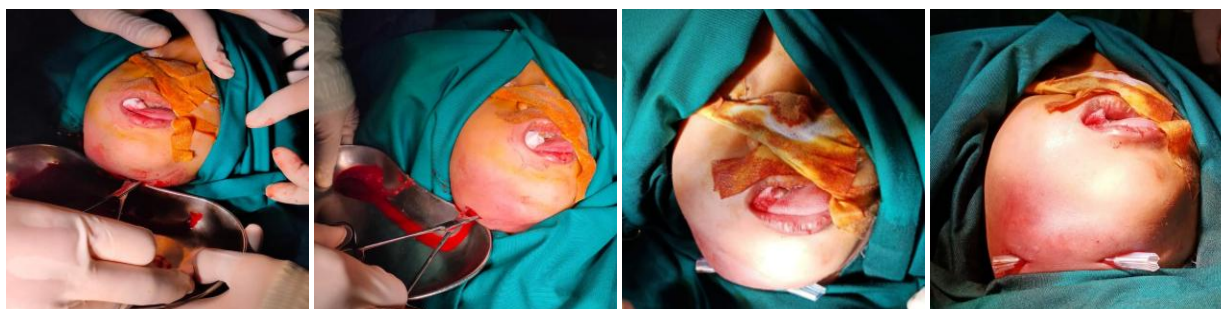
RL 46 drops/minute (micro drops), Regular diet, high protein, high calories 390 kcal/day. The patient was tapped for pus in the right lower jaw region and obtained ± two cc of pus and ± 0.5 cc of the submental area, then sent to the laboratory for bacterial culture. The patient was given

Ceftriaxone inj 325 mg IV, Metronidazole inf 170 mg IV, Paracetamol inf 195 mg IV. Subsequently, the patient was extracted from tooth 85. A through and through drainage incision in the right mandibular region to the submental

area was performed, and a Penrose drain and bandage were placed. Treatment was continued with intraoral spooling with 0.9% NaCl 2x1 a day, changing bandages 2x1 a day, changing extraoral Penrose drain every three days.



**Figure 3: Tapping pus in the submandibular and submental region**



**Figure 3: drainage incision and installation of a Penrose drain**

### Discussion

The diagnosis of this case was based on anamnesis, clinical examination, and radiographs. This infection originated from the teeth based on the history of the disease in the patient, which was preceded by the presence of carious teeth and pain. Infection from the teeth can spread to the surrounding tissues and extend to the maxillofacial space depending on the pathogenicity of the bacteria and the anatomical circumstances surrounding the teeth.<sup>1,2</sup> Many factors are responsible for spreading infection from the teeth to the maxillofacial space, such as decreased host defenses, increased bacterial resistance, nutritional status, patients, bacterial virulence, socioeconomic status, and local factors such as anatomical shape and patient hygiene.<sup>1</sup>

Odontogenic infection usually extends to involve the primary space in the maxillofacial area and then to the secondary space because it is connected between adjacent spaces. The infection spreads from one space to another.<sup>1,3,10</sup> The spread of infection of the mandibular teeth is generally to the submandibular space.<sup>3,9</sup> Enlarge enzymes that initially inoculate into the tissues more surrounding than the primary maxillofacial region to synthesize hyaluronidase, streptodornase, and streptokinase that result in degradation, and fibrin and connective tissue in the fascial space to initiate cellulitis, which can further cause abscesses to spread to the submandibular space caused by odontogenic infection of the lower second or third molars

with their apex located beneath the mylohyoid muscle, which then spreads rapidly to the sublingual and submandibular spaces.<sup>7,10</sup>

In this case, the source of infection was suspected to be primary teeth 85. The source of infection was generally the posterior primary teeth (84%). The mandibular posterior teeth were the most common source of infection.<sup>12</sup> The mandibular primary posterior teeth were more frequently affected than the posterior maxillary teeth (54.4%) than (45.6%). Extra-oral swelling occurred in 64% of patients. The upper face was affected more frequently than the lower face.<sup>9</sup> In this case, the clinical symptoms of swelling in the submental and submandibular. The spread of odontogenic infection to the submental and submandibular spaces is common and may be accompanied by trismus. Clinically, swelling occurs in the submandibular and submental areas with a firm and painful consistency. In addition, it can cause neck stiffness, trismus, odynophagia (pain when swallowing).<sup>4,9,10,11</sup> Common symptoms of widespread abscesses in teeth were pain (62.1%), intraoral swelling (37.9%), and spontaneous discharge of pus from the teeth or surrounding tissues (67.3%) with higher involvement of the right primary molars.

Odontogenic infections in children and their management can be challenging because of the complexity of the infection and children's behavioral problems. Oral health social status also plays a vital role in determining

preventive measures, dental care behavior, and clinical prognosis.<sup>13</sup> Early management and recognition of orofacial infections in children is necessary because of the possibility of developing the systemic disease.<sup>9</sup> Deep neck infections in children require more appropriate and effective treatment. Rapidly due to its rapidly progressive nature.<sup>14</sup> Delays in diagnosis and treatment can lead to life-threatening complications.<sup>15</sup>

Treatment of stable fascial space infection is incision and drainage or space decompression accompanied by broad-spectrum antibiotics and analgesics with pus collection for culture and sensitivity.<sup>1,5,9</sup> Specific antibiotics are given if culture and sensitivity results are available.<sup>1</sup> Empiric antibiotic therapy should be administered without waiting for the results of the pus culture while the patient is hospitalized. Empiric antibiotics should cover both aerobic and anaerobic, Gram-positive and Gram-negative bacteria. Second or third-generation cephalosporins as primary empiric antibiotic therapy, together with metronidazole or ornidazole, are usually used.<sup>5,7,13</sup> In this case, the patient has been given the antibiotics Ceftraxone inj 325 mg IV and Metronidazole inf 170 mg IV.

Indications for surgical incision and drainage, however, remain controversial (especially for cellulitis). Surgical exploration is necessary if there is a compromised airway, clinical signs of sepsis, or an inadequate response to antibiotic treatment within the first 48 hours.<sup>7,12</sup> In this case, treatment was initiated with a through and through drainage incision in the right mandibular region to the submental area. Pus roots can immediately flow out, and an aerobic atmosphere immediately occurs in the space. Several complications of severe odontogenic infections have been reported; such as airway obstruction, mediastinitis, necrotizing fasciitis, cavernous sinus thrombosis (CST), sepsis, thoracic empyema, cerebral abscess, and osteomyelitis.<sup>6, 7,13</sup> In this case, it did not cause severe complications because it was treated quickly to reduce and prevent widespread swelling that could cause airway obstruction. Administration of antibiotics is also appropriate according to the results of bacterial resistance culture and antibiotic sensitivity.

### Conclusion

Odontogenic infections in children can originate from the primary teeth and may extend to the maxillofacial space. Prompt and appropriate treatment of severe odontogenic infections in children needs to be done to prevent further complications but still pay attention to systemic conditions and maxillofacial anatomy. Education about maintaining dental and oral hygiene and health needs to be emphasized as a treatment protocol.

### Reference

1. Rout S, Gautam S, Shah AK. (2019), Temporal space infection secondary to recurrent buccal space infection from mandibular deciduous molar in 7-year-old child: a case report. *Journal of Chitwan Medical College.*; 9 (27): 70-73. JCMC
2. Veronez, B., Matos, F. P. de, Monnazzi, M. S., Sverzut, A. T., Sverzut, C. E., & Trivellato, A. E. (2014). Maxillofacial infection. A retrospective evaluation of eight years. *Brazilian Journal of Oral Sciences*, 13(2), 98–103. <https://doi.org/10.1590/1677-3225v13n2a04>
3. Bali, R., Sharma, P., Gaba, S., Kaur, A., & Ghanghas, P. (2015). A review of complications of odontogenic infections. *National Journal of Maxillofacial Surgery*, 6(2), 136. <https://doi.org/10.4103/0975-5950.183867>
4. Kumar, S., Ambastha, R., & Thakur, R. P. (2020). An observational study to determine the presenting features and associated etiologic factors for deep neck space infection among 0-12 year's old children. *European Journal of Molecular & Clinical Medicine (EJMCM)*, 7(11)
5. Sjamsudin, E., Manurung, B., Arumsari, A., & Maulina, T. (2020). The management of septic shock and Ludwig's angina: A case report of a life-threatening condition. *SAGE Open Medical Case Reports*, 8, 2050313X2093090. <https://doi.org/10.1177/2050313x20930909>
6. Mathew, G. C., Ranganathan, L. K., Gandhi, S., Jacob, M. E., Singh, I., Solanki, M., & Bither, S. (2012). Odontogenic maxillofacial space infections at a tertiary care center in North India: a five-year retrospective study. *International journal of infectious diseases : IJID : official publication of the International Society for Infectious Diseases*, 16(4), e296–e302. <https://doi.org/10.1016/j.ijid.2011.12.014>
7. Han, X., An, J., Zhang, Y., Gong, X., & He, Y. (2016). Risk factors for life-threatening complications of maxillofacial space infection. *Journal of Craniofacial Surgery*, 27(2), 385–390. <https://doi.org/10.1097/SCS.0000000000002416>
8. Lim, S. W., Lee, W. S., Mani, S. A., & Kadir, K. (2020). Management of odontogenic infection in paediatric patients: a retrospective clinical study. *European archives of paediatric dentistry: official journal of the European Academy of Paediatric Dentistry*, 21(1), 145–154. <https://doi.org/10.1007/s40368-019-00466-0>
9. Al-Malik, M., & Al-Sarheed, M. (2017). Pattern of management of oro-facial infection in children: A retrospective. *Saudi journal of biological sciences*, 24(6), 1375–1379. <https://doi.org/10.1016/j.sjbs.2016.03.004>
10. Alimin, N. H., & Syamsuddin, E. (2017). Emergency management of Ludwig's angina: a case report. *Journal of Dentomaxillofacial Science*, 2(3), 201. <https://doi.org/10.15562/jdmfs.v2i3.517>
11. Crescente, C. G., De Facchin, M. S., & Rodríguez, A. M. A. (2018). Medical-dental considerations in the care of children with facial cellulitis of odontogenic origin. A disease of interest for

- pediatricians and pediatric dentists. *Archivos Argentinos de Pediatría*, 116(4), e548–e553. <https://doi.org/10.5546/aap.2018.eng.e548>
12. Rana K, Rathore PK, Wadhwa V, Kumar S. (2013). Deep Neck Infections: Continuing Burden in Developing World. *Int J Phonosurg Laryngol*;3(1):6-9.
  13. Khanal, B., & Dulal, S. (2020). Assessment of clinical pattern and management of maxillofacial space infection in children visiting a tertiary health care centre in kavre, nepal. *J Nepal Dent Assoc*, 20(31), 68–72.
  14. Okoje, V. N., Omeje, K. U., Okafor, E., Adeyemo, Y. I., Abubaccar, J., Roberts, C., & Samateh, A. L. (2018). Oro-facial fascial space infection in a paediatric gambian population: A review of 93 cases. *Journal of the West African College of Surgeons*, 8(4), 1–23.
  15. Raghani, M. J., & Raghani, N. (2015). Bilateral deep neck space infection in pediatric patients: Review of literature and report of a case. *Journal of Indian Society of Pedodontics and Preventive Dentistry*, 33(1), 61–65. <https://doi.org/10.4103/0970-4388.149009>