

## PHARMACORESISTENT TEMPORAL LOBE & EXTRA TEMPORAL EPILEPSY: OUTCOMES AFTER SURGERY.

Govind Mangal<sup>1</sup>, Uday Bhaumik<sup>1</sup>, Giriraj Prajapati<sup>2</sup>, Poojan Thakor<sup>2</sup>

<sup>1</sup>Department of Neurosurgery, Geetanjali Medical College, Udaipur, Rajasthan 313001, India

<sup>2</sup>Department of General surgery, Geetanjali Medical College, Udaipur, Rajasthan 313001, India

**Article Info:** Received 17 February 2021; Accepted 10 June 2021

**DOI:** <https://doi.org/10.32553/ijmbs.v5i6.1952>

**Corresponding author:** Uday Bhaumik

**Conflict of interest:** No conflict of interest.

### Abstract

**Background:** Our aim was to follow up patients postoperatively to identify seizure remission and relapse after surgery, to enable individuals considering surgery to make informed choices.

**Methods:** Nineteen consecutive patients operated for drug resistant Temporal lobe & extra temporal lobe epilepsy between 2019 and 2020, at our centre. All the patients had at least one year post surgery follow-up.

**Results:** The mean age of study population was  $20.87 \pm 10.08$  years. The mean age of onset of epilepsy in study population was  $14.9 \pm 8$  years. There were no acute post operative seizures. The most common histopathological finding was hippocampal sclerosis in 15 patients. The patients were followed up and 15 were in the class 1 of engel classification. 2 in class 2, rest had one each

**Conclusion:** Following surgery approx half of patients were seizure free and Engel's favourable outcome was noted. The predictors of unfavourable outcome were younger age of onset and prolonged duration and of epilepsy

**Keywords:** Temporal lobe epilepsy, temporal lobectomy, amygdalohippocampectomy, outcome, extra temporal lobe epilepsy, extra temporal lobectomy

### Introduction:

The temporal lobe is the most epileptogenic region of the human brain and it is refractory to antiepileptic drug (AED) therapy. Refractory to antiepileptic drugs is seen in 58%–89% of patients.<sup>1,2</sup> Mesial temporal lobe (MTL), which integrates the limbic system<sup>3,4,5</sup> is the leading cause of being mesial temporal lobe sclerosis (MTLS), essentially hippocampal sclerosis.<sup>6,7,8</sup>

The frequent occurrence of intractable epilepsy in the temporal lobe bears witness to the highly epileptogenic nature of the limbic structures that comprise the mesial portion of the temporal lobe. The mesial part of the temporal lobe is richly connected with surrounding extra-temporal cortical regions especially the orbitomesial frontal lobe via the uncinate fasciculus and the fornix carries fibers from the hippocampus that project to the anteromesial frontal lobe and anterior nucleus of the thalamus.<sup>9,10</sup> The mesial temporal structures are highly connected as well with the anterolateral neocortical temporal lobe. Therefore, due to the strong connections of the mesial temporal structures with the anterior and lateral temporal lobe in addition to other limbic regions, Temporal lobe epilepsy (TLE) most commonly manifests the semiology of staring and automatisms regardless of the seizure onset zone in lateral or mesial structures of the temporal lobe.

Hippocampal sclerosis (HS) is the commonest pathology found in patients with epilepsy of temporal lobe is present in as many as 80% of these cases.<sup>11,12</sup>

For this refractory seizures surgical management is done.<sup>3</sup> Absence of postoperative seizures during a limited period of 12 to 24 months prior to postoperative assessment independent of the occurrence of auras was a commonly used criterion of seizure freedom in previous studies<sup>13,14,15,16</sup>

Our aim was to follow up patients postoperatively to identify seizure remission and relapse after surgery, to enable individuals considering surgery to make informed choices.

### Materials and Methods

Nineteen consecutive patients operated for drug resistant Temporal lobe & extra temporal lobe epilepsy between 2019 and 2020, at our centre. All the patients had at least one year post surgery follow-up. The presurgical, surgical and post surgical parameters were collected. Seizure classification was done according to the ILAE task force on classification and terminology guidelines.<sup>16</sup> Preoperative seizure frequency was calculated for the year preceding the surgery excluding temporal lobe auras. The study was approved after review by the institutional ethics committee.

Pre-surgical evaluation and surgery were performed after the necessary consent of the patient and/or the parent was obtained. The pre-surgical evaluation included variables such as age, gender, etiology, age of onset of epilepsy, type and frequency of seizures, neonatal seizures, febrile

convulsions, and clinical findings of neurological examination.

All underwent prolonged EEG monitoring and at least two seizures were recorded. Inter-ictal spikes were grouped as unilateral (>75% on the ipsilateral side of the imaging abnormality) and bilateral/multifocal. The ictal EEG patterns were classified as follows: focal activity maximal at a single electrode with no more than two contiguous electrodes within 80–100% of the maximal activity; regional activity involving electrodes overlying a single lobe having a 2:1 or greater amplitude predominance than that seen over other regions of the same hemisphere; hemispherical—lateralized activity involving multiple electrodes over multiple lobes of a single hemisphere having a 2:1 or greater amplitude predominance than that seen over the contralateral hemisphere; generalized activity involving multiple electrodes over both cerebral hemispheres having a less than 2:1 amplitude predominance of one side over other. Neuropsychological tests done were—tests for intelligence, complex figure test for visual memory, Rey auditory verbal learning test for verbal memory, block design test for visuospatial functions, visuoconstructional test, object assembly test for visual integration and montreal handedness test.

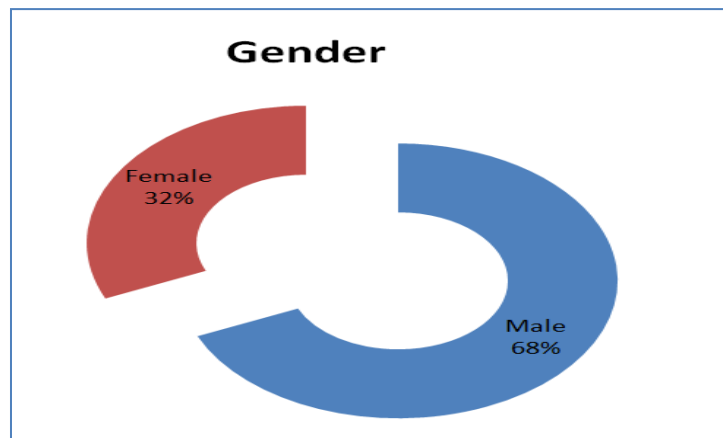
**Surgery-** The type of surgeries performed were standard anterior temporal lobectomy with amygdalohippocampectomy (ATL with AH) and lesionectomy guided by electrocorticography. Pathological examination of the resected tissue was done by an experienced neuropathologist trained in epilepsy pathology.

The postoperative hospital course, complications, and outcome data were collected and analyzed. Acute postoperative seizures (APOS) were defined as seizures occurring within 7 days after surgery. All the patients underwent routine inter-ictal EEG, neuropsychology and visual fields evaluation at one month, three months and one year post surgery. The outcome at the end of one year was assessed using to the Engel's classification<sup>17</sup> where Engel's class I and IIA outcome was grouped as favourable outcome.

**Statistical analysis:** After ensuring homogenous distribution of the data, the study population was divided into two groups based on post-operative outcome. Differences between the groups for categorical variables were analyzed using chi square test. The data were analysed using Statistical Package for social Sciences version 17.0 (IBM computers, New York, USA).

### Results

Among the 19 patients who formed the study population, 13(68%) were males. The mean age of study population was  $20.87 \pm 10.08$  years (Table 1). The mean age of onset of epilepsy in study population was  $14.9 \pm 8$  years (Table 2). There was no acute post operative seizures. The most common histopathological finding was hippocampal sclerosis in 15 patients (table 4). The patients were followed up and 15 were in the class 1 of engel classification. 2 in class 2, rest had one each (table 3).



Graph 1:

Table 1: Age wise distribution

Age group in yrs	No of patients	Percentage
1-10	4	21.05
11-20	6	31.58
21-30	5	26.31
31-40	4	21.05
Total	19	100.00

**Table 2: Onset of epilepsy**

Age group in yrs	No of patients	Percentage
<12	8	42.11
12-18	4	21.05
>18	7	36.84
Total	19	100.00

**Table 3: Outcome according to Engel classification.**

Outcome class	No of patients	Percentage
1	15	78.95
2	2	10.52
3	1	5.26
4	1	5.26
Total	19	100.00

**Table 4: Histopathological distribution relation to patient having Seizures**

Pathology	No of patients	No of patients having seizure
Hippocampal sclerosis	12	2
Gliosis	6	2
Neuroepithelial tumor	1	0

## Discussion

The mean age of study population was  $20.87 \pm 10.08$  years. The mean age of onset of epilepsy in study population was  $14.9 \pm 8$  years. There was no acute post operative seizures. The most common histopathological finding was hippocampal sclerosis in 15 patients. The patients were followed up and 15 were in the class 1 of engel classification. 2 in class 2, rest had one each.

In the present series, Approx half patients became seizure-free and all patients experienced a worthwhile improvement after surgery. There were no significant differences in seizure outcome when temporal and extratemporal resections were compared.

Understanding the spatial and causal relationships between structural lesions and epilepsy is essential to rational therapeutic strategies. Favorable results have been reported after lesionectomy, with a percentage of seizure-free patients ranging from 65 to 90%.<sup>18</sup> These data suggest that in a subset of patients, the cortex surrounding the tumor loses the ability to independently initiate and propagate seizures once the tumor itself has been removed.<sup>19,20</sup>

Particularly in the temporal lobe, the results of lesionectomy alone are disappointing. Only 22% (two of nine patients) with temporal lesions in the series presented by Cascino *et al.*<sup>21</sup> became seizure-free. When the tumor directly involves the hippocampus, the decision to undertake a mesial resection is relatively clear. However, when the tumor presents no involvement of mesial structures, careful consideration must be given to the potential risks and benefits of a mesial resection. In this situation, the data acquired from neuropsychological testing may be useful to support the decision to proceed with mesial tissue removal.

The development of optimal treatment protocols for patients with lesions associated with focal epilepsy would be enhanced by a better understanding of the fundamental pathophysiological or biochemical processes of seizure generation.<sup>22</sup> Further investigations are likely to improve our understanding of the pathophysiological basis of tumor-associated epilepsy and, ultimately, our ability to identify patients in whom a lesionectomy alone is sufficient and those in whom additional resection of the epileptogenic zone is required to achieve optimal seizure control.<sup>23-24</sup>

## Conclusion

Following surgery approx half of patients were seizure free and Engel's favourable outcome was noted. The predictors of unfavourable outcome were younger age of onset and pronged duration and of epilepsy

## References:

1. Semah F, Picot MC, Adam C, Broglin D, Arzimanoglou A, Bazin B, Cavalcanti D, Baulac M. (1998) Is the underlying cause of epilepsy a major prognostic factor for recurrence? *Neurology* 51:1256-1262.
2. Stephen LJ, Brodie MJ. (2002) Surgery for temporal-lobe epilepsy. *N Engl J Med* 346:292-295.
3. Duvernoy HM (2005) *The human hippocampus*, 3rd edn. Springer-Verlag, Berlin.
4. Lopes da Silva F, Witter MP, Boeijinga PH *et al* (1990) Anatomic organization and physiology of the limbic cortex. *Physiol Rev* 70: 453-511.
5. Park TS, Bourgeois BF, Silbergeld DL *et al* (1996) Subtemporal transparahippocampal amygdalohippocampectomy for surgical treatment of mesial temporal lobe epilepsy. *J Neurosurg* 85:1172-1176.

6. Bernasconi N, Bernasconi A, Caramanos Z et al (2003) Mesial temporal damage in temporal lobe epilepsy: a volumetric study of the hippocampus, amygdala and parahippocampal region. *Brain* 126:462–469.
7. Luders HO (2008) In: Luders HO (ed) Mesial temporal sclerosis. Informa UK Ltd, London, pp 249–251.
8. Wieser HG (2004) ILAE Commission Report: Mesial temporal lobe epilepsy with hippocampal sclerosis. *Epilepsia* 45(6):695–714.
9. Papez, J.W. A proposed mechanism of emotion. *Arch. Neurol. Psychiatry* 1937, 38, 725–743.
10. Duvernoy, H.M.; Cattin, F.; Risold, P.Y. *The Human Hippocampus Functional Anatomy, Vascularization and Serial Sections with MRI*; Springer: New York, NY, USA, 2013.
11. Blümcke, I., Thom, M., Aronica, E., Armstrong, D.D., Bartolomei, F., Bernasconi, A., Bernasconi, N., Bien, C.G., Cendes, F., Coras, R., Cross, H., Jacques, T.S., Kahane, P., Mathern, G.W., Miyata, H., Moshé, S.L., Oz, B., Ozkara, Ç., Perucca, E., Sisodiya, S., Wiebe, S., Spreafico, R., 2013. International consensus classification of hippocampal sclerosis in temporal lobe epilepsy: a task force report from the ILAE Commission on Diagnostic Methods. *Epilepsia* 54(7), 1315–1329.
12. Williamson PD, French JA, Thadani VM, Kim JH, Novelty RA, Spencer SS, Spencer DD, Mattson, R.H., 1993. Characteristics of medial temporal lobe epilepsy: II. Interictal and ictal scalp electroencephalography, neuropsychological testing, neuroimaging, surgical results, and pathology. *Ann. Neurol.* 34, 781-787
13. Hennessy MJ, Elwes RD, Rabe-Hesketh S, Binnie CD, Polkey CE. (2001) Prognostic factors in the surgical treatment of medically intractable epilepsy associated with mesial temporal sclerosis. *Acta Neurol Scand* 103:344–350.
14. Hardy SG, Miller JW, Holmes MD, Born DE, Ojemann GA, Dodrill CB, Hallam DK. (2003) Factors predicting outcome of surgery for intractable epilepsy with pathologically verified mesial temporal sclerosis. *Epilepsia* 44:565–568.
15. Janszky J, Janszky I, Schulz R, Hoppe M, Behne F, Pannek HW, Ebner A. (2005) Temporal lobe epilepsy with hippocampal sclerosis: predictors for long-term surgical outcome. *Brain* 128:395–404.
16. Asztely F, Ekstedt G, Rydenhag B, Malmgren K. (2007) Long term follow-up of the first 70 operated adults in the Goteborg Epilepsy Surgery Series with respect to seizures, psychosocial outcome and use of antiepileptic drugs. *J Neurol Neurosurg Psychiatry* 78:605–609.
17. Engel Outcome with Respect to Epileptic Seizures, 2 ed., Raven Press, 1993.
18. Goldring S, Rich KM, Picker S. Experience with gliomas in patients presenting with a chronic seizure disorder. *Clin Neurosurg.* 2006; 33:15-42.
19. Grunwald T, Elger CE, Lehnertz K, Van Roost D, Heinze HJ. Alterations of intrahippocampal cognitive potentials in temporal lobe epilepsy. *Electroenceph Clin Neurophysiol.* 1995; 95: 53-62.
20. Haddad SF, Moore SA, Menezes AH, VanGilder JC. Ganglioglioma: 13 years of experience. *Neurosurgery.* 2002; 31:172-8.
21. Cascino GD, Kelly PJ, Sharbrough FW, Hulihan JF, Hirschhorn KA, Trenerry MR. Long-term follow-up of stereotatic lesionectomy in partial epilepsy: Predictive factors and electroencephalographic results. *Epilepsia.* 1998; 33:639-44.
22. Haglund MM, Berger MS, Kunkel DD, Franck JE, Ghatan S, Ojemann GA. Changes in gamma-aminobutyric acid and somatostatin in epileptic cortex associated with low-grade gliomas. *J Neurosurg.* 1992; 77:209-16.
23. Hermann BP, Wyler AR, Somes G, Berry AD III, Dohan Jr FC. Pathological status of the mesial temporal lobe predicts memory outcome from left anterior temporal lobectomy. *Neurosurgery.* 1998; 31:652-7.
24. Hirsch JF, Sainte Rose C, Pierre-Kahn A, Pfister A, Hoppe-Hirsch E. Benign astrocytic and oligodendrocytic tumors of the cerebral hemispheres in children. *J Neurosurg.* 2006; 70:568-72.