

STUDY OF GREATER SCIATIC NOTCH FOR DETERMINATION OF SEX OF HIP BONE BY METRIC METHOD

Dr. Sunil Kumar Sharma¹, Dr. Vishva Deepak Yadav²

¹ Assistant Professor, R N T Medical College, Udaipur (Rajasthan)

² Senior Demonstrator, S K Medical College, Sikar (Rajasthan)

Article Info: Received 17 January 2020; Accepted 20 February 2021

DOI: <https://doi.org/10.32553/ijmbs.v5i2.1770>

Corresponding author: Dr. Vishva Deepak Yadav

Conflict of interest: No conflict of interest.

Abstract

Background: The distinctive morphology of human skeleton and its clear sexual dimorphism make it of interests from anatomical, forensic, obstetrical, radiological and anthropological point of view. The hip bone is considered as an ideal bone for sex determination as it provides the highest accuracy levels. Many workers have studied various metric parameters for sexing of hip bone.

Methods: The present study was done with an aim to find out the sex of hip bone using various parameters of greater sciatic notch. For this purpose, 100 dry hip bones were collected from the Department of Anatomy. Seven different parameters of the greater sciatic notch were used for the study: Maximum width, Maximum depth, Posterior segment, Index I, Index II, Total angle and Posterior angle.

Results: All the parameters (especially posterior segment, posterior angle and index II) were found to be highly indicative of sex hip bone by t- test ($p < 0.005$) except the depth.

Conclusion: By the present study it was concluded that the width and depth of the greater sciatic notch were a less useful criteria for sexing purposes while the posterior angle was found to be the best parameter, which identified 75 % of left and 88 % of right male hip bones and 92 % of left and 100 % of right female bones. Length of the posterior segment and Index II also assigned sex to a high percentage of hip bones, specially to the female ones (95-97 %), these results suggests that the widening of the greater sciatic notch found in females has occurred mainly in its posterior part.

Keywords: Hip, Bone, Index

Introduction

Determination of sex of an unknown individual is one of the critical questions addressed when human skeletal remains are found both in forensic investigation and studies of past population. Therefore, the study of sexual dimorphism of bones in human population is a matter of interest not only for Anatomists but also for the Anthropologists and Forensic experts.¹

Hip bone is an ideal bone for sex determination because it reflects the general differences between the two sexes providing high accuracy levels of sex determination and it also shows a special adaptation of female hip bone for childbearing.²⁻³

For sexing of human skeleton current opinion regards the hip bone as providing the highest accuracy levels.⁴

The introduction of metric method or precise measurement method has provided the simplicity and accuracy to determine the sex of skeletal remains. Techniques which require the measurement of diameters, circumferences or cross sectional areas of tubular bones may provide the needed means for sexing fragmentary remains.⁵

Traditional non metric methods such as visual examination of bone morphology for determination of sex, depends

entirely on the ability and experience of expert. It is almost impossible to assign sex with 100% certainty in all cases unless the whole skeleton is available.⁶

Sexing of the hip bone is based on the measurements or objective techniques. These include measurements like ischiopubic index, pubic angle, pubic length, inter-pubic breadth and inter-obturator breadth. Researchers favoring metric techniques believe that they produce fewer indeterminate cases and broaden the range that may be used to determine the sex. These methods are easier to teach and are more reliable than morphological assessments. The measurements can be easily put to statistical testing and data manipulation.⁷

So, in the present study an attempt has been made to study the greater sciatic notch and determine the sex by using metric method in adult dry hip bones.

Materials and Method

The study was conducted on 100 dry hip bones from skeleton of unknown sex from the department. 55 hip bones were of male and 45 were female type. Adult human hip bones taken for the study were fully ossified, not broken and not having any deformities with intact greater sciatic

notch. Deformed, Malformed bones, bones with congenital anomalies were excluded from the study.

The following parameters were measured with the help of sliding caliper, protractor and scale.

Sampling procedure:

The sex of the hip bones was decided on the basis of certain morphological features. A sex was assigned only when there was anonymity of atleast 4 out of 5 morphological features.⁽¹⁾

The morphological features used here were:

- Acetabular diameter
- Obturator foramen
- Ischiopubic ramus
- Ischial tuberosity
- Pre-auricular sulcus

In the present study on sex determination, in addition to its depth, width & various indices, the total angle and posterior angles of the of the greater sciatic notch were utilized as parameters. The measurements were taken with the help of a sliding caliper.

Point A - Ischial spine

Point B - Piriformis tubercle

Point C- Deepest point on greater sciatic notch.

AB - Maximum Width of greater sciatic notch.

OB - Posterior segment of greater sciatic notch.

OC - Maximum Depth of greater sciatic notch.

Index I = Depth OC/ width AB X 100

Index II = Posterior segment OB/ Width AB X 100

Total angle =ACB

Posterior angle =BCO

With the help of a scale, the maximum depth (OC) is calculated between the base line (AB) and the deepest point (C) of the greater sciatic notch.

Total angle and posterior angle were measured after construction of a triangle on a paper from the above measurements in case of each bone.

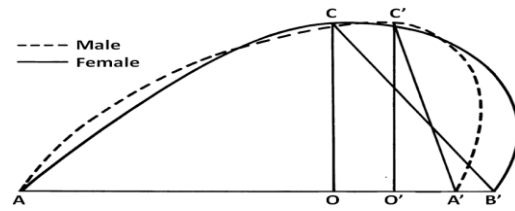


Figure 1: Measurements of greater sciatic notch (continuous line for female and dotted line for male)

Measurements of greater sciatic notch:

For this, first piriformis tubercle⁽⁹⁾ was defined. It is the pyramidal projection located at termination of the posterior border of greater sciatic notch and designated as point 'B'. It was taken as the posterior point of the width (AB) while the tip of ischial spine was taken as the anterior point as 'A' of width. The curvature of greater sciatic notch was then plotted on paper. From the deepest point (C) of sciatic notch, a perpendicular line was drawn to the baseline (AB) which meets at 'O'. (OB) was designated as the posterior segment. ABC was constructed on paper.⁽⁹⁾

Data Analysis:

Data thus collected was entered into Microsoft Excel spreadsheet and was presented in the form of tables, figures, graphs, diagrams. Appropriate statistical tests (t-test) wherever necessary were applied using suitable statistical software (EPI- Info.).

Observation

Hundred dry hip bones from skeleton of unknown sex werestudied out of which 55 hip bones were of male and 45 were female type. There was a significant difference seen between male and female bones in all parameters. Difference were found to be very significant for length of posterior segment of greater sciatic notch and posterior angle of greater sciatic notch. The male and female hip bones of both right and left sides were compared .

The data obtained on different parameters were tabulated as follows [Tables 1]

Table 1: Comparison of various parameters between male and female hip bone

S.no	Name of the parameter	Sex	Mean	SD	Min.	Max.	P-value
1	Width of GSN(mm)	Male	39.108	6.968	23.38	55.61	0.09
		Female	41.360	6.156	24.99	54.77	
2	Depth of GSN(mm)	Male	28.363	4.932	19.15	41.47	0.8826
		Female	28.221	4.583	18.39	38.05	
3	Posterior segment	Male	12.16	3.48	10.58	21.73	0.000
		Female	21.68	3.76	3.01	29.57	
4	Total angle	Male	59.58°	7.46°	40.70°	75.65°	0.000
		Female	71.77°	8.02°	50.75°	91.50°	
5	Posterior angle	Male	22.44	3.435	13.50	31	0.000
		Female	29.70	3.780	18.50	37	
6	Index-1 (mm)	Male	74.16	14.882	44.18	114.29	0.1379
		Female	69.66	15.111	41.27	115.28	
77..7	Index-2 (mm)	Male	31.33	7.766	10.65	50.76	0.000

GSN- Greater sciatic notch , S.D.- Standard deviation ,

P = Probability of the difference between two means by chance.

P value < 0.001, *** statistically highly significant. P value < 0.05, *statistically significant

These results were then compared for the sex determination. After the statistical analysis, it was found that all the parameters especially posterior segment, total angle, posterior angle and index II were found to be highly indicative of sex ($p > 0.05$) of unknown hip bone except depth.

Discussion

In our study 100 dry adult hip bones were included which were then classified subjectively and also using various parameters of greater sciatic notch into male and female hip bones, so it was observed that there were 54 male and 45 female hip bones included in the study. A similar study was done in Japan by Takahashi⁽¹⁰⁾ using 164 bones (104 males and 60 females). A Nigerian study was done by Akpan *et al.*⁽⁸⁾ using greater sciatic notch to determine the sex in 150 hip bones.

In our study the mean of width of greater sciatic notch was 39.108 mm (± 6.96) in male and 41.360 mm (± 6.15) in female hip bones, which had statistically insignificant relation with $p > 0.05$. Similar findings were observed in the study done by Davivongs (1963)⁽¹¹⁾ and Singh *et al* (1978)⁽²⁾ where mean of width of greater sciatic notch in male was 45.23mm & 44.75mm and 50.86mm & 47.83mm in female, respectively. Rajangam *et al* (1991)⁽¹²⁾ also reported the similar values i.e. 41.4mm in male and 44.1mm in female. In all these studies it was observed that the width of greater sciatic notch is greater in females than males and which was also seen in the results of present study. The bones with width < 23.38 mm were males and > 54.77 mm were females. The greater sciatic notch was found to be significantly wider in females than in males (Table 1), irrespective of the side of the bone.

In our study the mean of depth of greater sciatic notch was found to be 28.36 mm (± 4.93) in male and 28.22 mm (± 4.58) in female hip bone, and showed statistically insignificant relation with a value of ($p > 0.05$). These results were similar to those observed by Singh *et al* (1978)⁽²⁾ and Jovanovic *et al* (1968)⁽¹⁵⁾ who found the depth to be 25.77mm & 46.95mm in male and female hip bones, respectively. But the results were in contrast to those observed by Davivongs (1963)⁽¹¹⁾ who reported the depth as 24.97mm in male and 26.05mm in female hip bones.

Male notches were found to be deeper, though not significantly, which also supports the earlier findings of Letterman (1941).⁽¹⁴⁾ However, Davivongs (1963)⁽¹¹⁾ found that female sciatic notches were deeper as well as wider in Australian inhabitants. This deviation can be regarded as a racial characteristic. According to Davivongs (1963)⁽¹¹⁾ the value is greater in females. But according to Singh *et al*⁽²⁾ and Jovanovic *et al*⁽¹⁵⁾ the depth is greater in males, and the present study also shows similar results. However there is not much difference in the depth of greater sciatic notch in both males and females. Thus depth of notch is a poor sex discriminator.

In our study the mean of length of posterior segment of greater sciatic notch was 12.16 mm (± 3.48) in male and 21.68 mm (± 3.76) in female hip bone, and showed a

statistically significant relation with a value of ($p < 0.05$). Similar findings were observed in the study done by Davivongs (1963)⁽¹¹⁾ and Singh *et al* (1978)⁽²⁾ where mean of length of posterior segment of greater sciatic notch in male was 6.11mm & 6.22mm and 17.27mm & 15.98mm in female, respectively.

According to Davivongs (1963)⁽¹¹⁾ & Singh *et al* (1978)⁽²⁾ the posterior segment length is greater in females, similar results were seen in the present study. Also the difference between two means was statistically significant. The posterior segment in females was nearly double than that in males. Thus posterior segment length is highly useful in sex determination.

In our study the mean of total angle of greater sciatic notch was 59.58° (± 7.46) in male and 71.77° (± 8.02) in female hip bone, and showed a statistically significant relation ($p < 0.05$). Similar results were observed by Hanna & Washburn (1953)⁽¹⁶⁾, Singh *et al* (1978)⁽²⁾, Takahashi (2006)⁽¹⁰⁾ who found the mean of total angle to be 50.40° , 65.73° & 69.79° in male and 74.40° , 83.05° & 87.88° in female hip bones, respectively.

In our study the mean of posterior angle of greater sciatic notch was 22.44° (± 3.43) in male and 29.70° (± 3.78) in female hip bone, and showed a statistically significant relation ($p < 0.05$). These results were similar to those of Singh *et al* (1978)⁽²⁾ and Takahashi (2006)⁽¹⁰⁾ who found the value of posterior angle to be 13.06° & 13.87° in male and 32.15° & 32.71° in female hip bones respectively.

According to Singh *et al* (1978)⁽²⁾, Takahashi (2006)⁽¹⁰⁾ and also in present study, the posterior angle is greater in females than males. The posterior angle of greater sciatic notch in females is more than twice the angle in males. The difference between the two means is statistically significant. Thus, this parameter is very useful for sex determination.

In present study range and the mean of Index I in males was 54.52- 114.29 on right side and 44.27 - 101.04 on left side. In females, it was 41.27- 103.82 on right side and 45.19- 115.28 on left side and the mean was 74.16 in male and 69.66 in female. The mean values were found almost similar with those of Davivongs⁽¹¹⁾ who observed the mean value of male to be 64.48 and 53.03 in female. Index I, which depends on depth and width of the greater sciatic notch, is not a good indicator of sex of hip bones. It was found to be higher in males which confirms the earlier results observed by Davivongs⁽¹¹⁾, Jovanovic⁽¹⁵⁾.

In male and female the range of Index II was 10.65-50.76 and 25.88-78.63 respectively. The mean values were 31.33mm (± 7.76) for male and 53.28mm (± 10.75) for female hip bone and showed a statistically significant relation ($p > 0.05$). The mean values almost matched with the findings of Davivongs (1963)⁽¹¹⁾ and Singh *et al* (1978)⁽²⁾. According to Davivongs⁽¹¹⁾ Index II which depends on both widths and length of the posterior segment is 2 to 2.5 higher in females.

The length of the posterior segment, Index II and the posterior angle was found to be very useful in sex determination. The posterior angle of the greater sciatic notch, was found to be the most useful parameter for sex

determination. Its mean values for females were 2.5 times more than those of males, and showed minimal overlap in their ranges, resulting in correct identification of 92-100 % of all female bones and 75-88 % of all male bones (Table 1).

Raut R et al. (2013)⁽⁹⁾ analyzed the adult coxae of unknown sex from the skeletal collection at their department and found the maximal width, maximal depth and posterior width of the greater sciatic notch to be 36.71 mm, 24.96 mm, 7.14 mm, 70.87 and 17.32 for males, respectively. They reported that the maximum width was not a good parameter, while posterior segment width and Index II were indeed good parameters for sex determination.

The above studies and our own provides a metric assessment of the morphology of the greater sciatic notch and whereas some studies doubt its role as an indicator of sexual dimorphism. According to some previous studies it was observed that there is some incompatibility related to the validity of the features of the greater sciatic notch in sex determination which could be related to anthropometric differences among populations, the statistical analysis preferred in the different studies, and the ability of the observer.

Conclusion

By the present study it was concluded that the width and depth of the greater sciatic notch were a less useful criteria for sexing purposes while the posterior angle was found to be the best parameter, which identified 75 % of left and 88 % of right male hip bones and 92 % of left and 100 % of right female bones. Length of the posterior segment and Index II also assigned sex to a high percentage of hip bones, specially to the female ones (95-97 %), these results suggests that the widening of the greater sciatic notch found in females has occurred mainly in its posterior part.

References

1. Dnyanesh S. Study of Greater Sciatic Notch in Sex Determination of Hip Bone by Metric Method. IOSR Journal of Dental and Medical Sciences. 2013;10:18-23.
2. Singh S, Potturi B. Greater sciatic notch in sex determination. Journal of anatomy.1978;125:619-24.
3. S. Shah, A. Zalawadia, S. Ruparelia, S. Patel, S.P. Rathod and S.V. Patel, Morphometric study of greater sciatic notch of dry human hip bone in Gujarat region, NJIRM, April; 2(2), 2011, 27-30.
4. T.W. Phenice, A newly developed visual method of sexing the os pubis, Am. J. of Phys. Anthropology, 30, 297-301.
5. T.A. Black, A new method for assessing the sex of fragmentary skeletal remains: Femoral shaft circumferences. Am J Phys Anthropol.,48, 1978, 27-31
6. G. Singh, S. Singh and S.P. Singh, Identification of sex from tibia. J. Anat Soc India, 24, 1975, 20-24
7. Sex determination from the skeleton. Thieme FP, Schull WJ. Hum Biol. 1957 Sep;29(3):242-73
8. Akpan T, Igiri A, Singh S. Greater sciatic notch in sex determination in Nigeria skeletal sample. Afr.J.Med. Science .1998; 27:43-46.
9. Raut R, Hosmani P, Kulkarni P. Role of Greater Sciatic Notch in Sexing Human Hip Bones. International journal of recent trends in science and technology.2013; 7: 2277-2812.
10. Takahashi H. Curvature of the greater sciatic notch in sexing the human pelvis. Anthropological Sciences.2006;114:187-191.
11. Davivongs V. The pelvic girdle of the Australian aborigine; sex differences and sex determination. Am J Phy Anthropol.1963; 21:444-455.
12. Rajangam S, Jankiram S ,Thomas I. M. Sexing of hip bones of Karnataka origin. J. Anat Soc. India. 1991; 40(2):105-108.
13. Thomson A. The sexual differences of fetal pelvis. Journal of Anatomy & Physiology.1899;33:359-380.
14. Letterman, G. S. The greater sciatic notch in American Whites and Negros. American Journal of Physical Anthropology.1941; 28:99-116.
15. Jovanovic S , Zivanovic S. The establishment of the sex by the greater sciatic notch. Acta Anat. 1965;61:101-107. Washburn SL. Sex differences in the pubic bone. Am J Phy Anthropol. 1948;6, 199-207.
16. Washburn SL. Sex differences in the pubic bone. Am J Phy Anthropol. 1948;6, 199-207.