

EVOLUTION IN BREAST IMAGING

Dr. Sushil J. Sikchi

Department of Radiology, Dr. Punjabrao Deshmukh Memorial Medical College Amravati India

Article Info: Received 19 December 2020; Accepted 17 January 2021

DOI: <https://doi.org/10.32553/ijmbs.v5i1.1606>

Corresponding author: Dr. Sushil J. Sikchi

Conflict of interest: No conflict of interest.

Abstract

Evolution in breast imaging has dramatically changed and upgraded by wide variety of technologic advances from the early days of direct-exposure film mammography to xeromammography to screen-film mammography to the current era of full-field digital mammography and digital breast tomosynthesis. In early 1950 Mammography has been introduced along with the breast self examination. After two decades thermography and ultrasound examination has been added in the breast imaging. From year 1990 to 2000 drastic technological advances, organized screening with BI-RAD classification introduced by American College of Radiology Breast Imaging Reporting and Data System have helped to shape the specialty of breast imaging. With the development of digital mammography and tomosynthesis in 2020, breast ultrasonography and breast magnetic resonance imaging, both complementary to mammography, has set new standard in diagnostic accuracy of breast lesions. This paper gives a quick insight to the development of breast imaging and reviews the evolution of breast imaging starting from a historical perspective and progressing to the present day.

Keywords: Mammography screening, tomosynthesis ,Digital mammography.

Introduction

Turn the head back and look into the early 19th century, when it was difficult to diagnose early breast lesion clinically. Then the era of imaging started after the invention of x-ray. It's wonderful to observe the whole journey of breast imaging starting from simple radiography of breast to digital mammography to 3D mammography. This evolution in breast imaging has rationalized the easy and early diagnosis of breast cancer and reduced the mortality in women. It is fascinating to see how the new imaging modalities evolved over the course of time and that drastically changed the diagnostic accuracy in breast imaging.

Evolution of Breast Imaging Techniques

After 18 years of the discovery of X-Ray, A German Surgeon Dr. Albert Salomon of Berlin began a study of 3000 Mastectomies and wondered if by using these newly discovered rays he could correlate known cancerous tissues of breast specimen to radiographs taken of the same breast. He used radiography of mastectomy specimens to demonstrate the spread of tumor to the axillary lymph nodes and discovered microcalcification on the image of specimens with known breast pathology. Salomon also showed that highly infiltrating carcinoma could be radiographically distinguished from circumscribed carcinoma. In 1913, he wrote 'roentgen photographs of excised breast specimens give a demonstrable overview of the form and spread of cancerous tumor'.

In 1930, Stafford Warren, MD., published his successful application of preoperative breast radiograph to help predict

malignant and benign disease in 119 patients with a histopathological diagnosis (61 benign, 58 malignant). Warren obtained breast roentgenograms by using the same fluoroscopic equipment used to image other body parts and presented a simple but detailed technique in his report. Interpretations seemed more challenging as he used a cumbersome stereoscopic viewing technique. He noted that radiographic interpretation often predicted malignancy better than the clinical evaluation. In his series of 119 patients there were only misclassifications for an amazing accuracy of 93%.

In 1934, Lockwood reported on the value of the breast radiograph showing radiologic, Pathologic correlation.

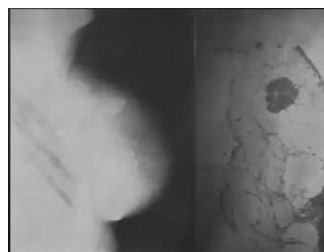

Figure 1: Lockwood H. The value of Breast Radiography. Radiology 1934-23(2)-202-207

Novel technique such as contrast injection were attempted during this period but the interest waned due to the relative complications.

In 1949, in several Spanish articles Raul Leborgne of Uruguay, reported finding radiographically visible microcalcification in 30% of breast cancers. Expanding on his findings in 1951, article and 1953 English book, Leborgne revitalized interest in the mammography. He

recognized the importance of breast compression for improving the image quality. Leborgne used non screen film a target film distance of 60cm, 20-30kvp and 5mAs for each centimeter of compressed breast thickness and he obtained coned, compression spot mammograms of areas of interest. He was the first to report the significant association of radiographically detectable micro-calcification which may be seen in extensive as well as incipient lesions and breast carcinoma. Leborgne also described the radiographic differences between the benign and malignant calcifications.

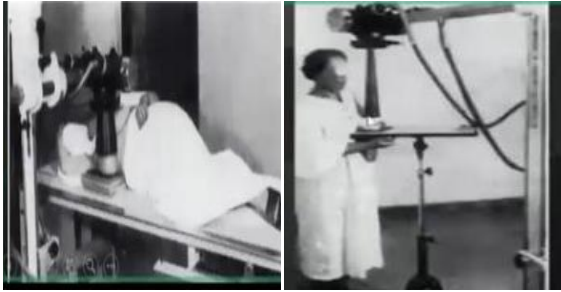


Figure 2: Compression spot Mammography

In 1960, Robert el Egan described of a standardised direct exposure mammographic technique and report on 1000 cases at MD Anderson, in which mammography was found to be useful for depicting unsuspected cancers and for decreasing the number of mastectomies for benign disease. Egan's mammography was performed with a ceiling mounted general purpose X-ray tube powered by a special generator capable of lower KV exposures 40KVP relative – to general radiography.

Described positioning technique to get the nipple in profile and avoid folds or overlapping structures direct exposure film, little or no compression applied. The images were low in contrast. Exposure times were relatively long and approximately 5 to 6 seconds but he developed a standardized technique that was reproducible and transferable to other practices was also instrumental in training a critical mass of Radiologists who were able to reproduce his results.

From 1963 to 1966 Philips Strax, Louise Venet and Sam Shapiro under the health insurance plan of New York organized the first randomised controlled trial of periodic screening with physical examination and mammography to determine whether it could reduce breast cancer mortality. The five year followup results showed that compared with the control group the mortality rate was reduced by almost 1/3rd for the women who underwent screening mammograph.

The decrease in mortality remained at a significant level through 18 years of followup. The health insurance plan trial provided the foundation and scientific basis for the subsequent worldwide success of screening mammography.

In late 1960, Strax became the first person to develop a successfully operate a self contained mobile unit for breast cancer screening with mammography.

The encouraging result of HIP study prompted the national cancer institute and the American Cancer Society to launch their large multiinstitutional Breast Cancer detection demonstration project screening study. The HIP study showed a benefit for screening Mammography using 1960 techniques- direct exposure film and no substantial breast compression. The breast cancer detection demonstration project using the improved mammography technique of the 1970s would ultimately suggest even greater benefit of screening mammography with similar survival demonstrated in women aged 40-49, 50-59 and 60-69 years. Multiple subsequent randomized control trials have since shown significant breast cancer mortality reduction from screening mammography.

In 1968 to 1996, data from 2 county Swedish trial supported the contention that breast cancer is localized to the breast for the variable period of time before the development of systemic disease.

- Time to diagnosis is critical, earlier the better
- Cancers less than 1cm have a 12 year survival rate of 95%
- Node negative breast cancer less than 1.5cm have a 12 year survival rate of 94%
- RCT starting at the age 40 years have shown 20% to 40% reduction in breast cancer mortality rate in screened groups compared to controls.
- It is accepted that Breast cancer grow more rapidly in premenopausal women. so screening mammography every 2 years is recommended starting at age 40 years.
- Accuracy of mammography is about 85% and is by far the best screening modality available.

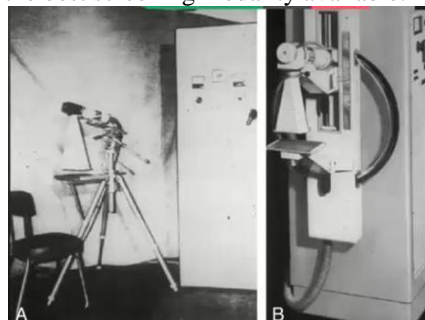


Figure 3: First Mammography Machine

Xero Radiography

This technology gained in popularity during the 1970's due to the efforts of John Wolfe MD., who worked closely with the Xerox corporation to improve the xerographic process for imaging the breast. Given the wide latitude and age enhancement inherent in the technology xero mammography was well suited for imaging the breast.

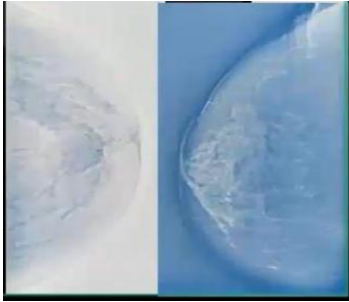


Figure 4: Xero Radiography

Disadvantages – Paper jams and non uniform toners, Lack of continuing innovations , and relatively high radiation dose lead to the replacement of xero mammography by screen film mammography.

The ‘Screen’ of film screen mammography

Until the early 1970 acceptable diagnostic quality in mammograms required hand processing or use of a slow mechanical processor .To reduce radiation and exposure time J.L. Price and P. D. Buttler in 1970 experimented with a high definition intensifying screen and industrial film held in intimate contact with in an air evacuated polyethylene envelope.

In 1973 Dupont became the first company to market a dedicated screen film mammography system and a device to create a vacume to hold the screen and film tightly together. Eastman Kodak followed with its own screen film mammography unit and introduced the vacume cassette of mammography. Development of screen film mammography and uniform thickness breast compression was a major advancement. Screen film techniques use a more columnated X-ray beam to make the exposure, allowed faster imaging time, reduced dose, and somewhat increased contrast.Around this time compression devices were developed with capability for uniform thickness compression of the breast. Applying uniform thickness compression also spread out the breast tissue more effectively permitting better visualization. The combination of shorter exposute time and stabilization of the breast afforded by compression yielded less image degradation due to motion blurr. Screen film mammography eventually completely replaced direct exposure film mammography and xero mammography.

In 1974, the oblique mammographic view was introduced as an efficient single view method of screening. The oblique view allowed more breast tissues to be included in the image field, in particular the posterior tissues in the axillary tail of the breast. The oblique view was shown to be superior to the mediolateral view for breast cancer detection. Although the oblique view showed more breast tissue than the lateral view, two views were ultimately found to be better than a single view.

Triangulation and Magnified views

Muffins rise (Medial) and Lead Sinks (Lateral) also were taught to trainees to predict whether a medial or lateral lesion on the craniocaudal view would triangulate to the upper and lower breast on the 90% lateral projection. The addition of single mammogram to conventional views in 216 biopsy proven cases was shown to improve diagnostic accuracy by 40%.

Standardised reporting and outcome

Along the high quality imaging ,accurate interpretation and clear communication of findings and recommendation to referring clinician was necessary to ensure the success of mammographic screening . Around the same time as the development of the mammography accreditation program, The American college of Radiology began its breast imaging reporting and data system (BI-RADS) initiative in response to request from referring clinician to standardize reporting of mammography in 1993. BI-RADS was the structure reporting language for imaging and contains three important components.

- a) A lexicon of descriptors
 - b) A reporting structure to include final assessment categories and management recommendations
 - c) A framework for data collection and auditing
- BI-RADs has now gone through 5 editions now involves mammography, breast ultrasonography, and breast magnetic resonance(MR) Imaging. And now includes standardized auditing approaches for all three .

Disadvantages of FSM

- Limited dynamic range
- Noise due to film granularity
- Longer acquisition time
- May need to be repeated
- More radiation for the patient
- Film is the sole medium for the acquisition display and storage.
- Film processing cost and need for the delicate maintainance
- No post processing options
- Difficult in dense breasts

Digital Mammography

As in screen film mammography the three criteria are coupled into each other as recording, displaying and archieving of images has to be done simultaneously and, that is a major limitation. Compared to this in digital mammography decoupling of recording, displaying and archieving has been done separately. There is opportunity to optimse each task independently. Image acquisition, display and archiving are separated.

FFDM comes with the features like Wide dynamic range,Lower dose(-20%), Higher KVP(+3KVP),Better for

dense breasts, Imaging detectors can be used as AEC Detector, Use of MO/MO, MO/Rh, Rh/Rh, W/Rh and W/Ag targets, Image latitude and contrast of structure is much greater than Film Screen Mammography Noise is less as there is no film. Dose is less as there is no need for antiscattered grid, Ability to correct under and overexposure of film without having to repeat mammograms, Transmittal of images over phone lines or a network for remote consultation with other physician – Telereporting.

Scintillating phosphor on an array of amorphous Silicon photodiodes using thin film transistors flat panel technology is first introduced by GE.

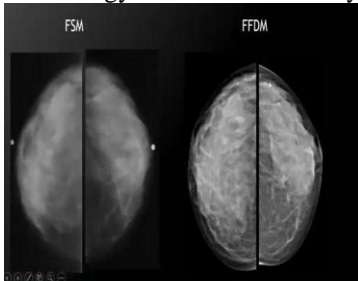


Figure 5: FSM/ FFDM

Advantage of Digital Mammography

- Improved contrast between dense and non dense breast tissue.
- Faster image acquisition
- Shorter examination time
- Easier image storage
- Physician manipulation of breast images for more accurate detection of breast cancer.
- Teleradiology

The development of digital breast imaging does not constitute an end point but rather represent the beginning of new era for mammography; an era in which the digital platform serve as the basis for the development of innovative radiographic methods of imaging the breast innovation that were not possible on the analog platform

Digital Breast Tomosynthesis

- The compressed breast tissue is imaged in a quasi-3 dimensional manner by performing a series of low dose radiographic exposures and using the resultant projection image dataset to reconstruct cross sectional in plane images in standard mammographic views.
- Reduces the *summation* of overlapping breast tissues which can mimic breast cancer and provide improved detail of non calcified mammographic finding scene in breast cancer.
- Assist in lesion localization and determining mammographic extent of disease in women with known or suspected breast cancer.

- Improved characterization of findings , including normal structures and breast cancer.
- Object seen in the specific plane of each section in the stake of reconstructed images are in focus, while objects in planes above or below or out of focus.
- The amount of blurring of a given object is proportional to its distance from the currently displayed plane and the object size.
- Radiologist scroll through the images individually and manipulate the section thickness to as thin a 1mm interval.
- Images can also be grouped as a slab to further evaluate anatomic or pathologic finding.
- Combination mode imaging -2D full field digital mammography and DBT are performed in the same examination during the same breast compression.
- DBT projection images are acquired first followed by standard mammographic images obtained in neutral perpendicular position with no change in breast compression.



Figure 6: Tomosynthesis Equipment

ADVANTAGES

- Effective localization of single view abnormalities
- Reduction in breast cancer screening recall rates
- Improved sensitivity and specificity with use of DBT.
- can acquire images in standard mammographic orientation
- Can also be performed with spot compression used to obtain implant displaced views.

Contrast Enhanced Mammography.

- Contrast enhanced mammography- has the potential to detect early stage breast malignancy by detecting signs of Angiogenesis and to monitor the effect of anti Angiogenesis drug therapy.
- Common method of performing contrast enhanced mammography

In Dual energy contrast enhanced digital subtraction mammography two images are taken at different energy levels and subtracted from one another. Substraction increases the visibility of contrast agent.

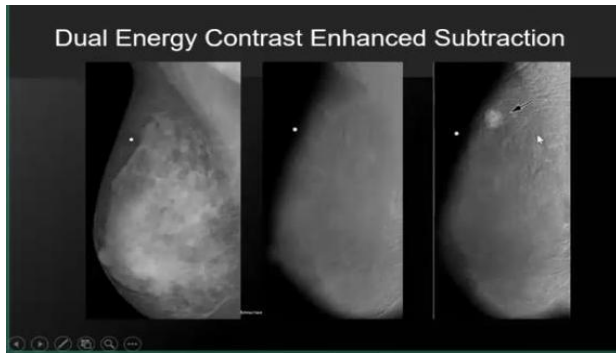


Figure 7: Dual Energy Contrast Enhanced Subtraction

Full field digital mammography / ultrasound fusion

Prototype systems being developed high resolution whole breast ultrasound images coregister with the digital mammograms. Fusion system acquires both images during same compression and allows comparison between two image modalities.

In short: Timeline of breast imaging

1950	Breast self examination+Mammography
1960	Breast self examination + Mammography
1970	BSE + Mammography + Thermography+Ultrasound
1980	BSE+Mammography+Better US
1990	BSE+Mammography +US +MRI
2000	Digital mammography +US+MRI
2020	Digital Mammography+US+MRI+MR Spectroscopy +Tomosynthesis+PEM+BSG

Conclusion

Current breast imaging modalities play a vital role in assisting clinicians in primary screening of cancer in the diagnosis and characterization of lesions, staging and restaging treatment selection and treatment progress monitoring. In this paper we have discussed the evolution of various modalities in breast imaging since its inception in 1950 till date.

It is evident from the material discussed in this paper that no single modality is completely useful in all areas of diagnosis of breast lesion, but after the advent of digital mammography and 3D-Mammography which has drastically improved the specificity and sensitivity in diagnosis of various pathologies in breast. Along with the HD ultrasonography has improved the diagnostic capability to nearly 95 to 98%. Gradual development and research in mammography technology over a time has updated the diagnostic accuracy in breast cancer detection. Currently research on modality development is moving towards the molecular level. This type of imaging will help in understanding the nature of growth and development which in turn might lead us closure to finding the possible cure for this disease.

References

- Warren SL. A roentgenologic study of the breast. *Am J Roentgenol Radium Ther.* 1930;24:113–124.
- Lockwood H. The value of breast radiography. *Radiology* 1934;23(2):202–207.
- Vyborny CJ, Schmidt RA. Mammography as a radiographic examination: an overview. *Radio Graphics* 1989;9(4):723–764.
- Strax P, Venet L, Shapiro S. Value of mammography in reduction of mortality from breast cancer in mass screening. *Am J Roentgenol Radium Ther Nucl Med* 1973; 117(3):686–689. Figure 21 Figure 21: Right (a) mediolateral oblique conventional digital mammogram, (b) dual-energy contrast-enhanced mammogram, and (c) sagittal MR image show infiltrating ductal carcinoma (arrow) of the right breast in 43-year old woman (fig 1 from reference 191). BREAST IMAGING: Evolution of Breast Imaging Joe and Sickles S40 radiology.rsna.org n *Radiology: Volume 273: Number 2 (Suppl)—November 2014.*
- Smart CR. Highlights of the evidence of benefit for women aged 40–49 years from the 14-year follow-up of the Breast Cancer Detection Demonstration Project. *Cancer* 1994;74(1 suppl):296–300.
- Larsson LG, Andersson I, Bjurstram N, et al. Updated overview of the Swedish Randomized Trials on Breast Cancer Screening with Mammography: age group 40–49 at randomization. *J Natl Cancer Inst Monogr* 1997 (22):57–61.
- Lundgren B, Jakobsson S. Single view mammography: a simple and efficient approach to breast cancer screening. *Cancer* 1976;38(3):1124–1129. 28. Bassett LW, Gold RH. Breast radiography using the oblique projection. *Radiology* 1983;149(2):585–587.
- Pearson KL, Sickles EA, Frankel SD, Leung JW. Efficacy of step-oblique mammography for confirmation and localization of densities seen on only one standard mammographic view. *AJR Am J Roentgenol* 2000;174(3):745–752.
- Sickles EA. Combining spot-compression and other special views to maximize mammographic information. *Radiology* 1989;173(2):571.
- Kopans DB. Standardized mammography reporting. *Radiol Clin North Am* 1992;30(1):257–264.
- Pisano ED, Yaffe MJ. Digital mammography. *Radiology* 2005;234(2):353–362.
- Pisano ED, Zuley M, Baum JK, Marques HS. Issues to consider in converting to digital mammography. *Radiol Clin North Am* 2007;45(5):813–830, vi.
- Avrin D, Morin R, Piraino D, et al. Storage, transmission, and retrieval of digital mammography, including recommendations on image compression. *J Am Coll Radiol* 2006;3(8):609–614.

14. Pisano ED, Gatsonis CA, Yaffe MJ, et al. American College of Radiology Imaging Network digital mammographic imaging screening trial: objectives and methodology. *Radiology* 2005;236(2):404–412.
15. Pisano ED, Hendrick RE, Yaffe MJ, et al. Diagnostic accuracy of digital versus film mammography: exploratory analysis of selected population subgroups in DMIST. *Radiology* 2008;246(2):376–383.
16. Taylor KJ, Merritt C, Piccoli C, et al. Ultrasound as a complement to mammography and breast examination to characterize breast masses. *Ultrasound Med Biol* 2002;28(1):19–26.
17. Berg WA, Blume JD, Cormack JB, et al. Combined screening with ultrasound and mammography vs mammography alone in women at elevated risk of breast cancer. *JAMA* 2008;299(18):2151–2163.
18. Orel SG, Schnall MD. MR imaging of the breast for the detection, diagnosis, and staging of breast cancer. *Radiology* 2001;220(1): 13–30.
19. Lee CH, Dershaw DD, Kopans D, et al. Breast cancer screening with imaging: recommendations from the Society of Breast Imaging and the ACR on the use of mammography, breast MRI, breast ultrasound, and other technologies for the detection of clinically occult breast cancer. *J Am Coll Radiol* 2010;7(1):18–27.
20. Kopans DB, Lindfors K, McCarthy KA, Meyer JE. Spring hookwire breast lesion localizer: use with rigid-compression mammographic systems. *Radiology* 1985;157(2):537–538.
21. Friedewald SM, Rafferty EA, Rose SL, et al. Breast cancer screening using tomosynthesis in combination with digital mammography. *JAMA* 2014;311 (24): 2499–2507.
22. Rafferty EA, Park JM, Philpotts LE, et al. Assessing radiologist performance using combined digital mammography and breast tomosynthesis compared with digital mammography alone: results of a multicenter, multireader trial. *Radiology* 2013;266(1): 104–113.
23. Jochelson M. Contrast-enhanced digital mammography. *Radiol Clin North Am* 2014; 52(3): 609–616.
24. Pisano ED, Gatsonis C, Yaffe M et al. *N Engl J. Med.* 2006 Oct.26;355(17)1840 Diagnostic performance of Digital vs Film Mammography for breast cancer screening .