

## SILVER TRAUMA- A TRUE CHALLENGING ENTITY

D. Chowdhury

Specialty Registrar in Emergency Medicine  
United Kingdom

**Article Info:** Received 28 November 2020; Accepted 25 December 2020

**DOI:** <https://doi.org/10.32553/ijmbs.v4i12.1585>

**Corresponding author:** D. Chowdhury (<https://orcid.org/0000-0002-4064-2257>)

**Conflict of interest:** No conflict of interest.

### Introduction:

Historically trauma has been identified as the leading cause of death in the younger under 40's population<sup>(1)</sup>. However, with an aging population there is a higher incidence of trauma sustained in the elderly population. Silver trauma is defined as elderly patient of retirement age or over the age of 65 years. This has been taken into consideration when trauma guidelines have been incorporated. To name a few examples, the CCSR (Canadian C-spine rule) includes the at-risk population as those  $\geq 65$  years of age in the context of potential cervical spine injury. In various major trauma trial tools, the  $>65$  years of age group are considered to be a high risk of deterioration group. Through clinical practice clinicians have noted that in this group of patients' injuries can be missed which would be detrimental to the overall outcome of these patients.

Through this article I aim to highlight the main issues that make the initial management of the elderly trauma patient at times challenging. Furthermore, suggestion for potential management strategies will also be highlighted.

### Cervical Spine Immobilisation

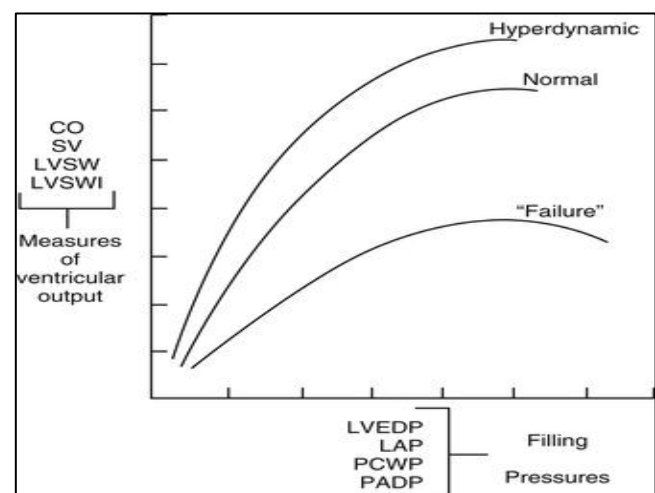
There is still ongoing debate about the use of hard collar as part of triple immobilisation in patients with suspected C-spine injuries. The classic teaching from ATLS principles endorse the use of hard collar as part of C-spine immobilisation, however in cases of traumatic brain injury this could be detrimental in the control of intracranial pressure. Readers would agree that placing a hard collar in an acutely agitated patient would do more harm as excess hyper-extension could potentially precipitate a central cord syndrome in patients with pre-existing degenerative disorders of the C-spine. There has to be a calculated risk taking between the use of head blocks and tape versus the use of triple immobilisation. Having a dedicated healthcare professional providing constant reassurance to the elderly patient would be ideal, however with high volumes of trauma influx this is often not plausible.

The routine means of triple immobilisation in the standard neutral/horizontal plane may not be appropriate for all elderly patients due to underlying degenerative changes in the cervical spine<sup>(2)</sup>. If a C-spine fracture has been identified, all efforts should be made to ensure that further

neurological injury is avoided whilst talking into consideration the patient's natural neck position.

### Altered physiology and reserves

Early recognition of altered physiology in the setting of elderly trauma can be difficult to detect due to various underlying factors. The elderly patient may not mount a physiological tachycardia from haemorrhage due to the presence of beta-blockers. If there is significant pre-existing left ventricular systolic dysfunction, following a period of uncontrolled haemorrhage the cardiac output will no longer be sustained. This is highlighted in the following diagram<sup>(3)</sup>



**Figure 1:** The relationship between ventricular output and filling pressures

In patients with pre-existing LV systolic impairment, any further detrimental metabolic insult such as acidosis will have a negative inotropic effect which will further compromise the cardiac output. The importance of maintaining adequate perfusion cannot be over emphasised and early recognition is paramount. Normotension in a patient known to have pre-existing hypertension is also a worrying physiological parameter. The relatively inexperienced clinician may not appreciate this and could potentially lead to delays in definitive management and lead to poorer outcomes. To aid the clinician, measurements such as IVC collapsibility index and shock index can be used to detect hypovolaemic states secondary to traumatic haemorrhage.

## Pain management

Pain has both physiological and psychological components. The pain following hip fractures has been linked to altered physiological states leading to the development of delirium<sup>(4)</sup>, depression and sleep disturbance, thereby highlighting the importance of effective management from admission through to rehabilitation. With the ageing population, the prevalence of cognitive impairment in the population will also rise, with this the co-existing morbidities will also rise. With this the incidence of polypharmacy, the effective analgesia that can be provided in addition to the regular prescribed analgesia is somewhat limited<sup>(5)</sup>.

Achieving adequate analgesia without compromising cardiorespiratory function can pose a true management challenge. This has led to the increased use of nerve blocks for a wide variety of injuries. Emergency physicians as part of their training in the United Kingdom have to demonstrate competencies in performing such procedures. Early involvement of critical care teams to optimise the patient's analgesic requirement would possibly lead to better outcomes.

## Potential management strategies

The elderly trauma patient needs a multidisciplinary approach from the outset to maximise the functional outcomes. In many units across the United Kingdom there is early involvement of the ortho-geriatrician once the acute management of neck of femur fractures has been addressed. This early involvement can potentially be translated in clinical practice in the elderly patients suffering other forms of trauma. The one size fits all plan is not likely to benefit all elderly patients as the tolerance to rehabilitation varies between individuals and is dependent on the underlying comorbidities.

The admitting teams need to be thorough in their clinical approach and have a low threshold for imaging as deemed necessary. A vast majority of silver trauma patients are the walking wounded with the presentation of head injury. There are often additional injuries than the isolated head injury that needs to be investigated and managed accordingly. When factoring in the possibility of underlying cognitive impairment, this becomes even more challenging. This does not necessarily mean that all elderly trauma patients need to have major trauma CT scans prior to being assessed. The basics of history and examination findings need to be meticulously documented and through repeated

observation any deterioration detected and acted upon expediently.

It is not infrequently that patients on the major trauma ward are primarily looked after by the acute surgical specialities with input from the critical care teams to optimise pain management. The role of the geriatrician cannot be overemphasized. The elderly injured patient is likely to have multiple co-morbidities with polypharmacy also present. Earlier correction and optimisation of the physiological derangements through careful consideration would improve patient outcomes<sup>(6)</sup>. It is often the underlying co-morbidities that lead to a poor outcome than from the physiological and anatomical insult from the primary injury

*Key Words: Major Trauma, Elderly patient, Outcomes*

## Conclusion

A multidisciplinary approach is required to manage the elderly trauma patient to optimise outcomes. The admitting clinician needs to appreciate that this is at risk of deterioration group and preventive measures need to be undertaken to mitigate such circumstances. The early involvement of the acute care of the elderly physician would be instrumental in being beneficial to the patient's journey to recovery.

## References

1. Green S, Miles K. The Burden of Disease and Illness in the UK London. UK: Department of Health; 2007
2. Rao PJ, Phan K, Mobbs RJ, Wilson D, Ball J. Cervical spine immobilization in the elderly population. *J Spine Surg.* 2016Mar;2(1):41-6. doi:10.21037/jss.2016.02.02. PMID: 27683694; PMCID: PMC5039838.
3. <https://aneskey.com/cardiovascular-anatomy-physiology-pathophysiology-and-anesthesia-management/>
4. The management of chronic pain in older persons: AGS panel on chronic pain in older persons: American geriatrics society. *J Am Geriatr Soc* 1998; 46:635-51.
5. Chowdhury D. Comparing the effectiveness of fascia iliaca block with standard analgesia in neck of femur fractures in a district general hospital emergency department— a prospective study with review of literature. *J Emerg Crit Care Med* 2019
6. Murali M, Bolton L, Bhaktal S. 77 Silver trauma pathway: a new gold standard in elderly trauma care *BMJ Leader* 2018;2: A32.2.