

NEUROSONOGRAPHY SPECTRUM OF HYPOXIC ISCHEMIC ENCEPHALOPATHY

Dr. Sunil Jakhar¹, Dr. Bineeta Singh Parihar², Dr. Anu Bhandari³, Dr. Kuldeep Mendiratta⁴, Dr. Meenu Bagarhatta⁵

Assistant Professor¹, Junior Resident², Professor³, Professor⁴, Professor and Head of Department⁵

Department of Radiodiagnosis, SMS Medical College and Attached Group of Hospitals

Article Info: Received 10 July 2020; Accepted 05 August 2020

DOI: <https://doi.org/10.32553/ijmbs.v4i8.1335>

Corresponding author: Dr. Sunil Jakhar

Conflict of interest: No conflict of interest.

Abstract

Introduction: Neonatal hypoxic-ischemic encephalopathy (HIE) is a very catastrophic condition that may result in severe neurologic deficits or even death. Neuroimaging with transcranial ultrasound (US) is a valuable tool in the workup of patients with HIE. The pattern of brain injury depends on the severity and duration of hypoxia and degree of brain maturation.¹

Aim: To study imaging spectrum of various stages of HIE

Objective: To determine severity of HIE on basis of Neuro-sonography.

Settings and Design: The study was conducted at J K Lone Paediatric hospital attached to SMS hospital. It is a Prospective study.

Materials and Method: Pre term neonates having some history of hypoxia antenatally or perinatally like placental abruption, low Apgar at delivery, seizures coming to JK Lone Paediatric Hospital attached to SMS hospital referred to Dept of Radiodiagnosis for evaluation of HIE were scanned using Transcranial ultrasound it included grayscale on Hitachi machine.

Results- Different grades of HIE changes were witnessed. Out of 33 cases:

5 neonates were sonographically normal, 3 showed grade 1 GMH, 3 showed grade 2 GMH, 4 showed grade 3 GMH and 4 showed grade 4. 3 neonates showed grade 1 PVL, 2 grade 2 PVL, 4 showed grade 3 PVL, 5 showed grade 4 PVL. In doppler findings of ACA, it was noted the RI (resistive index) was on the higher side.

Conclusion: Neurosonography and doppler is very helpful non-invasive tool to detect early changes of HIE and assess severity and progression of hypoxic brain injury.

Keywords: HIE, hypoxic brain injury, germinal matrix haemorrhage and periventricular leucomalacia

Introduction

Neonatal hypoxic-ischemic encephalopathy (HIE) is a devastating condition that may result in death or severe neurologic deficits in children. The changes are either due to hemodynamic changes i.e. Germinal matrix haemorrhage (GMH) or due to hypoxia or hypoperfusion i.e. Periventricular leukomalacia (PVL). Neuroimaging with transcranial ultrasound (US) is a valuable tool in the workup of patients with HIE. Severity and duration of hypoxia and degree of brain maturation determines brain injury patterns.

In grading for GMH there are 4 grades: Grade 1 refers to the haemorrhage restricted to subependymal region/germinal matrix which is seen in the caudothalamic groove. Grade 2 refers to extension into normal sized ventricles and typically filling less than 50% of the volume of the ventricle. Grade 3 refers to extension into dilated ventricles. Grade 4 refers to grade III with parenchymal haemorrhage. Grading system for GMH-IVH was proposed by Papile et al⁴

In grading of PVL there are 4 grades: Grade 1 refers to areas of increased periventricular echogenicity without any cyst formation persisting for more than 7 days. Grade 2 refers to the echogenicity has resolved into small periventricular cysts. Grade 3 refers to areas of increased periventricular echogenicity that develop into extensive periventricular cysts in the occipital and frontoparietal region. Grade 4 refers to areas of increased periventricular echogenicity in the deep white matter developing into extensive subcortical cysts.

Materials and Method

Pre term neonates coming to JK Lone Paediatric Hospital attached to SMS hospital referred to Department of Radiodiagnosis for evaluation of HIE were scanned using Transcranial ultrasound.

Neonates having some history of hypoxia antenatally or perinatally like placental abruption, low Apgar at delivery, or seizures are included.

Neonates whose vitals were unstable, on ventilator and those parents who were non consenting were excluded.

Result:

Different grades of HIE changes were witnessed. In this study 33 cases were taken and out of those 33 cases , 5(15%) neonates were sonographically normal, 3(9%) showed grade 1 GMH, 3(9%) showed grade 2 GMH, 4(12%) showed grade 3 GMH and 4(12%) showed grade 4 . 3(9%) neonates showed grade 1 PVL, 2(6%) showed grade 2 PVL, 4(12%) showed grade 3 PVL, 5(15%) showed grade 4 PVL.

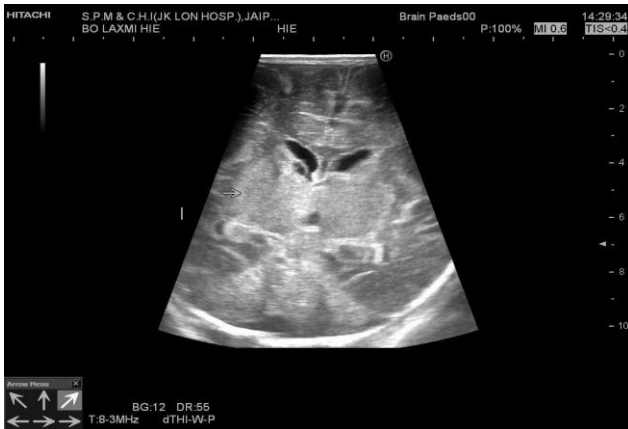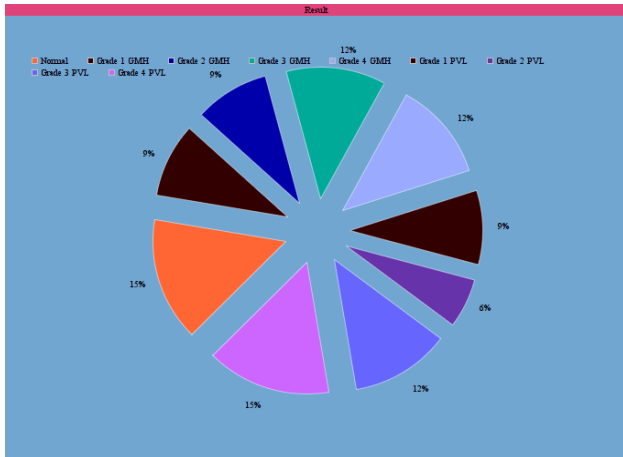


Figure 1: Haemorrhage seen in Lt. caudothalamic groove(coronal image) – Grade 1 GMH

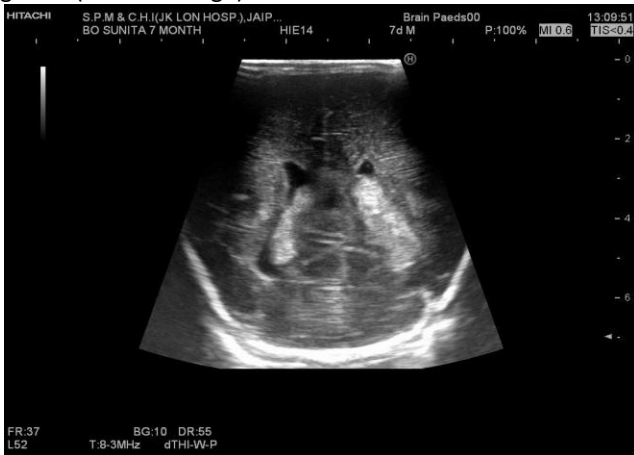

Figure 2: Haemorrhage seen in intraventricular region. Grade 2 GMH

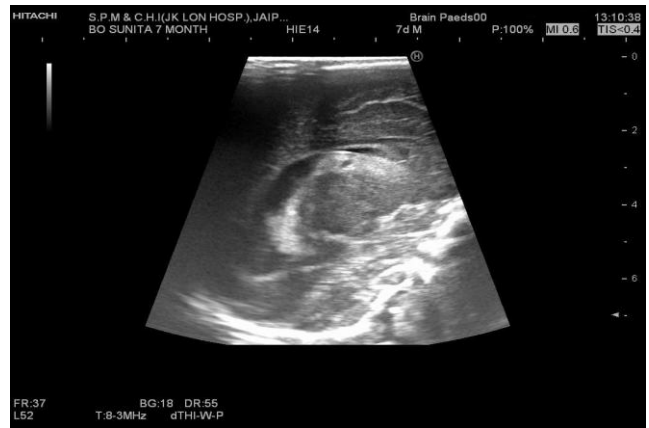

Figure 3: Sagittal section shows IVH. Grade 2 GMH

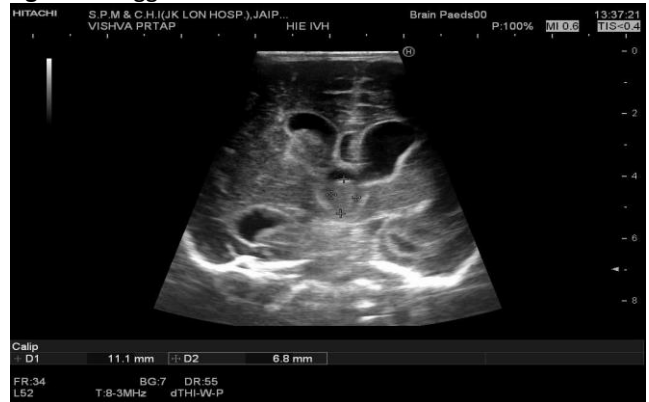

Figure 4: Image IVH with dilated ventricle. Grade 3 GMH

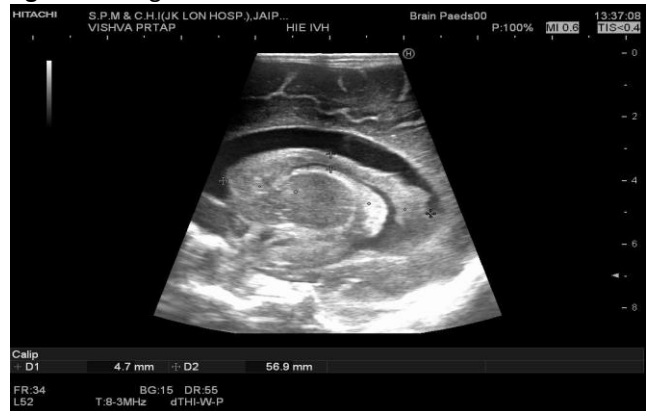

Figure 5: sagittal image .Grade 3 GMH

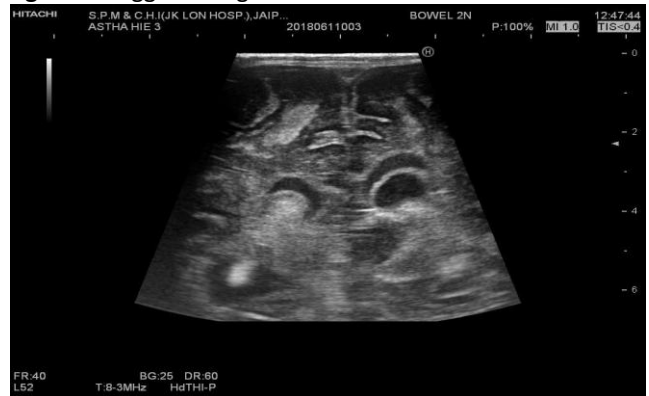

Figure 6: Intraparenchymal Haemorrhage noted. Grade 4 GMH

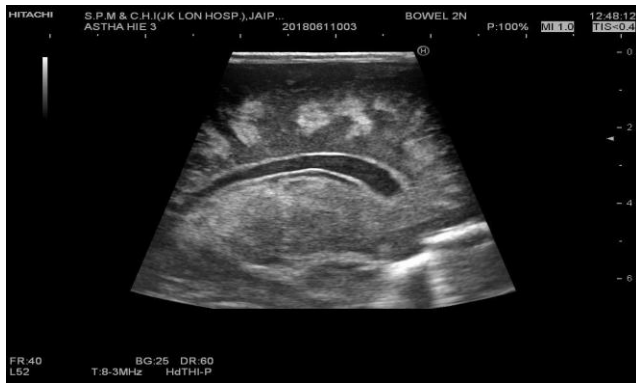

Figure 7: Sagittal image for Intraparenchymal Haemorrhage . Grade 4 GMH

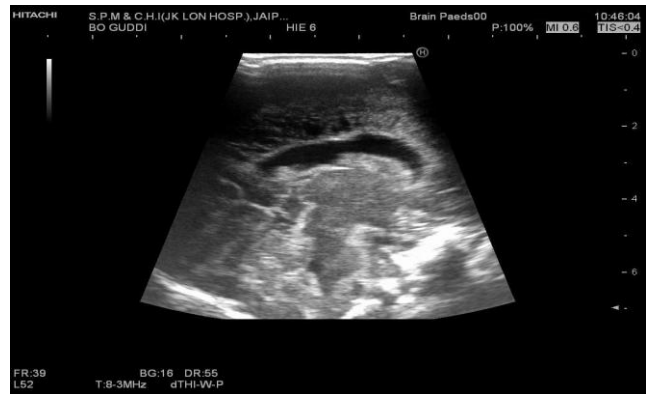

Figure 11: Sagittal image showing Extensive periventricular cysts. Grade 3 PVL

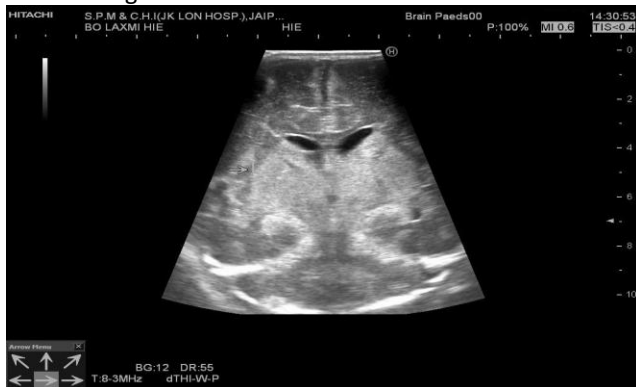

Figure 8: Increased periventricular echogenicity. Grade 1 PVL

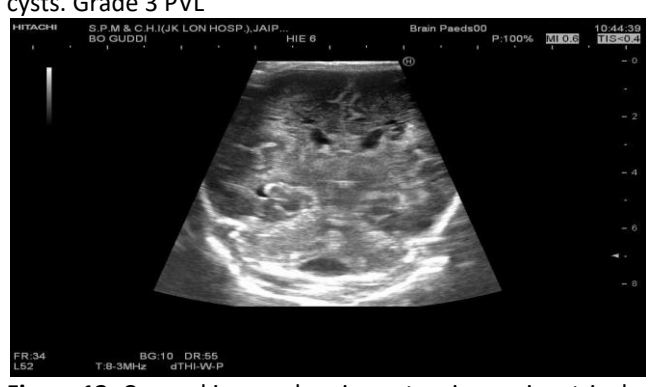

Figure 12: Coronal image showing extensive periventricular cysts. Grade 3 PVL

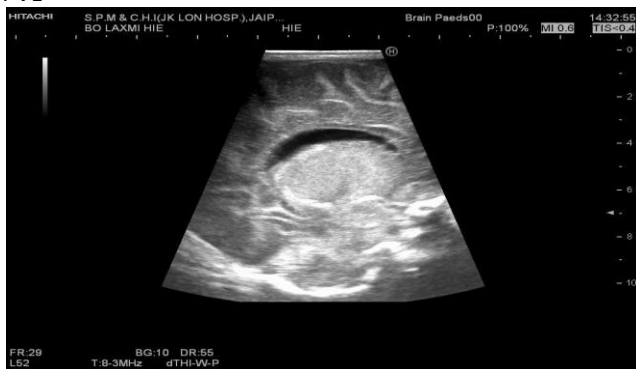

Figure 9: Sagittal Image for increased periventricular echogenicity. Grade 1 PVL

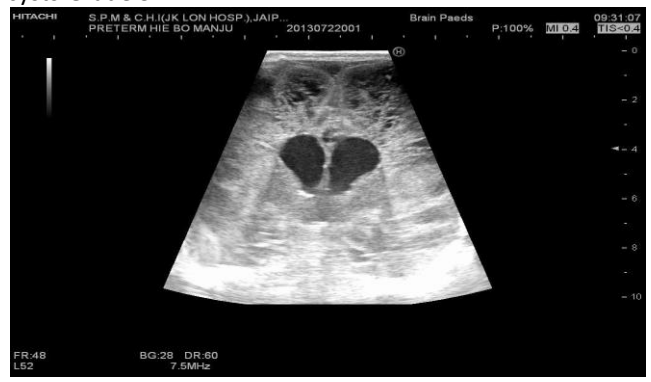


Figure 13: Coronal image showing extensive subcortical cysts. Grade 4 PVL

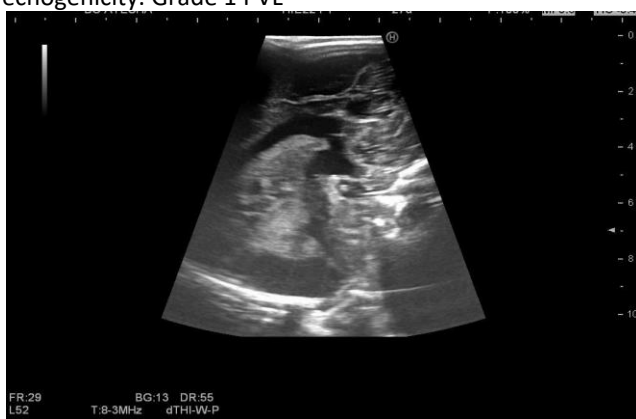
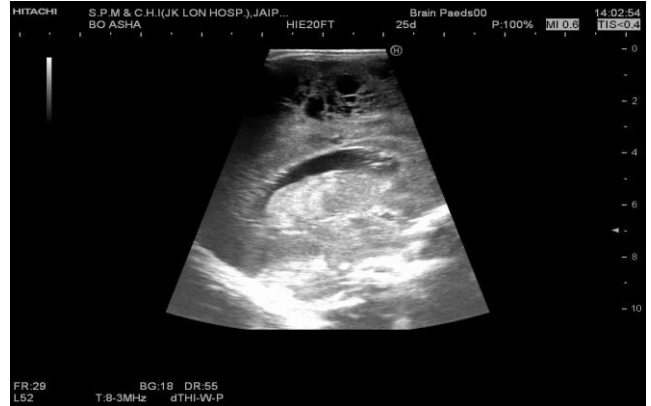
Figure 10: Periventricular cyst noted . Grade 2 PVL



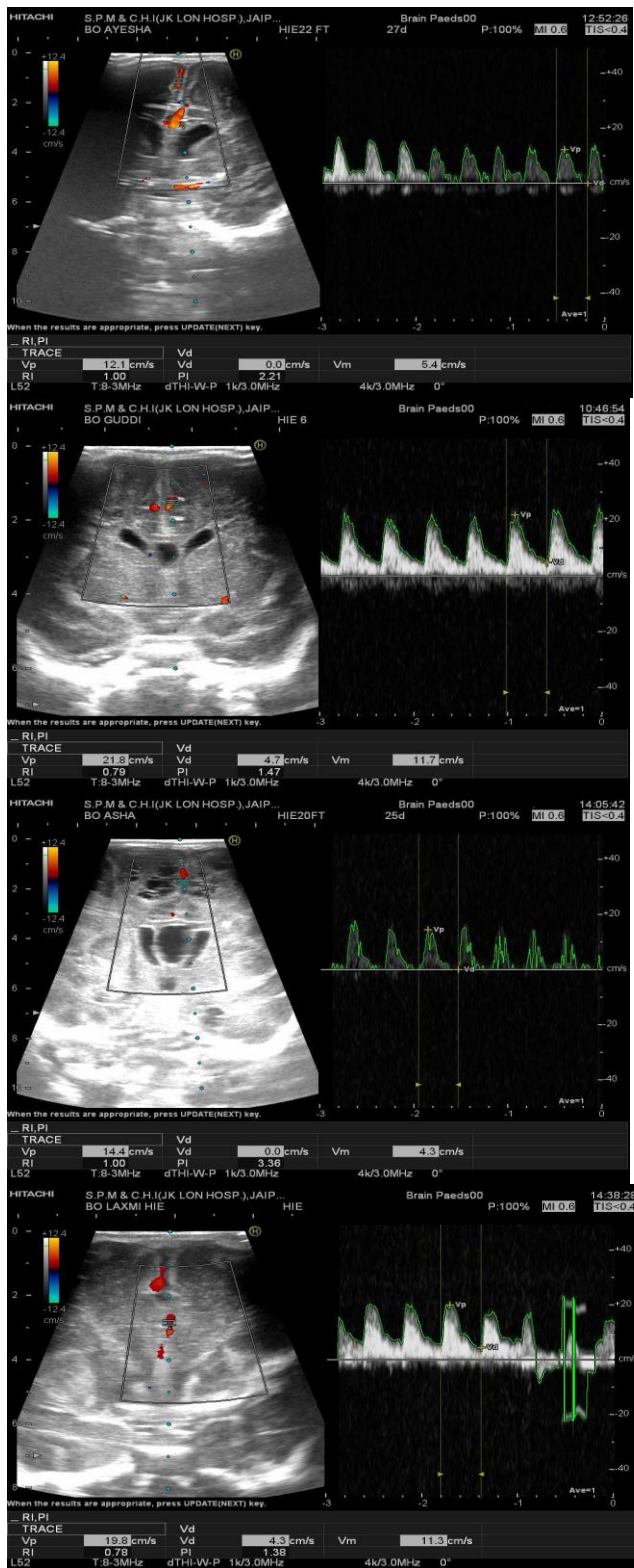


Figure 14: Saggital image showing extensive subcortical cysts. Grade 4 PVL

Discussion:

Hypoxic-ischemic encephalopathy is the most important cause of neurological morbidity and mortality in preterm neonates.

Hill et al. showed the possibility of diagnosing periventricular leukomalacia (PVL) in the newborn period using cranial sonography. Since then, knowledge about sequence of events appearing in sonograms has been available. In the acute phase, increased echogenicity of the periventricular white matter can be noted, which occurs within 24 to 48 hours after a hypoxic-ischemic incident. The affected periventricular white matter is usually as bright as or lighter than the choroid plexus, as opposed to a normal periventricular halo, which is less bright than the choroid plexus. Two to 4 weeks later, cysts may appear in the hyperechogenic areas. Eventually, the cysts dissolve with the development of ventricular enlargement.²

De Vries et al described spectrum of leukomalacia³

Conclusion: - Neurosonography and doppler is very helpful non-invasive tool to detect early changes of HIE and assess severity and progression of hypoxic brain injury.

References:

1. Neonatal Hypoxic-ischemic Encephalopathy: A Radiological Review Shahina Bano, Vikas Chaudhary, Umesh Chandra GargaJ Pediatr Neurosci. 2017 Jan-Mar; 56-58
2. Hill A, Melson GL, Clark HB, Volpe JJ. Haemorrhagic periventricular leukomalacia: diagnosis by real time ultrasound and correlation with autopsy findings. Paediatrics 1982; 69:282-284.
3. De Vries LS, Eken P, Dubowitz LMS. The spectrum of leukomalacia using cranial ultrasound. Behav Brain Res 1992;49:1-6
4. Papile, L. A., Burstein, J., Burstein, R. & Koffler, H. Incidence and evolution of subependymal and intraventricular haemorrhage: a study of infants with birth weights less than 1,500 gm. J. Pediatr. 92, 529-534 (1978)