

## F.N.A.C. AS DIAGNOSTIC TOOL OF PAROTID TUMORS AND ASSOCIATED PITFALLS IN CORRELATION WITH HISTOPATHOLOGY

Dr. Bhawana Pant<sup>1</sup>, Dr. Sanjay Gaur<sup>2</sup>, Dr. Prabhat Pant<sup>3</sup>

<sup>1</sup>Associate Professor, ENT, GDMC Dehradun

<sup>2</sup>Associate Professor, Pharmacology, GDMC, Dehradun

<sup>3</sup>Assistant Professor, Pathology, GMC, Haldwani

**Article Info:** Received 02 January 2020; Accepted 28 January 2020

**DOI:** <https://doi.org/10.32553/ijmbs.v4i1.1153>

**Corresponding author:** Dr. Sanjay Gaur

**Conflict of interest:** No conflict of interest.

### Abstract

F.N.A.C has been used for ages as a safe and economical tool for fast preoperative diagnosis of parotid tumors. It has certain pitfall which sometimes leads to misdiagnosis and consequently it may have affect on treatment of the tumors. Keeping in view of the diverse classification of parotid tumors' information from cytology should be combined with radiology as well as clinical diagnosis.

**Aim:** To discuss some cases where there was discrepancy between cytological diagnosis and histopathological result and also suggest measures to improve the efficacy of F.N.A.C.

**Material and methods:** The study includes 50 cases of parotid tumours who presented to the department of ENT at Government medical college Haldwani which is a tertiary referral centre during 2009 to 2016. Only adult patients were included and inflammatory swelling were excluded from the study. All patients evaluated Contrast enhanced computerized tomography(CECT) and Magnetic resonance imaging (MRI) followed by Fine needle aspiration cytology .Preoperative diagnosis was made upon the findings of the above investigations and different types of parotid surgeries were done. . Final diagnosis was made on histopathological examination.

**Result :**The most common tumour came out to be pleomorphic adenoma (23 cases-46%) followed by mucoepidermoid carcinoma(12cases-24%). In ten cases there was no clear cut association between cytological diagnosis and final histopathological diagnosis.

**Conclusion:** FNAC is highly sensitive and specific technique for diagnosis of many salivary gland swellings. FNAC can be used preoperatively to avoid unnecessary surgery and biopsy. Details of clinical information and radiologic features may help the pathologist to arrive at the appropriate diagnosis and reduce false interpretation. Pitfalls may also occur with improper technique of FNAC which can be overcome by proper caution.

### Introduction

Parotid gland tumors are interesting in a way because of variable clinical presentation, radiological dilemma at times and variable cytological pictures. These factors are very important for a surgeon when preoperative work up is being done. FNAC plays an important role though at times controversial in cases of benign tumours like pleomorphic adenoma. Problem can be on both levels ie. sampling error as well as interpretation at the level of cytopathologist. There are several benign malignant look alike tumours such as basal cell adenoma and adenoid cystic carcinoma that can be confused on FNAC.<sup>1</sup> These cases can finally be addressed by histopathology report of the entire specimen. This study included parotid tumours over a period of five years which were studied for clinical presentation, cytology picture and histopathological profile. Pit falls and

shortcomings of FNAC in preoperative diagnosis of parotid tumours is also discussed.

### Material and methods :

The study includes 50 cases of parotid tumours who presented to the department of ENT at Government medical college Haldwani which is a tertiary referral centre. The duration of study includes patients presenting during 2009 to 2016. Only adult patients were included and inflammatory swelling were excluded from the study. All patients who were suspected to have tumours were evaluated with radiological tools like Contrast enhanced computerized tomography(CECT) and Magnetic resonance imaging (MRI). It was followed by Fine needle aspiration cytology.( FNAC).Preoperative diagnosis was made upon the findings of the above investigations and different types of parotid surgeries were done. Nature of surgery was

also changed according to the intraoperative findings. Final diagnosis was made on histopathological examination. Postoperative radiotherapy or chemotherapy was decided on the basis of final histopathological diagnosis. Association between preoperative FNAC finding and final histopathological diagnosis was seen.. Cases in which there was no association between cytological and histopathological diagnosis were discussed.

**Result and observation:** Out of 50 patients included in the study male to female ratio was 2:3.F.N.A.C. was performed in all cases and repeat procedure was done in 10 patients. FNAC results were divided into following categories eg pleomorphic adenoma,mucoepidermoid carcinoma, warthin 's tumour,adenocystic carcinoma,lymphoma etc.as shown in table no.1.

**Case (1)- A case of Warthin's tumor was diagnosed as low grade mucoepidermoid carcinoma on cytology.** A 63 years old male patient presented with right parotid gland mass. On cytology, smears were paucicellular& showed few groups and clusters as well as singly dispersed mucinophages along with very occasional small groups, clusters, small sheets of squamous epithelial cells & intermediate cells against a background containing abundant mucoid / proteinaceous material with numerous singly dispersed lymphoid cells. This patient was diagnosed as low grade mucoepidermoid carcinoma on cytology. However histopathological examination revealed features of warthin's tumour. This case seems to be a case of selective sampling on cytology. Multiple sampling is important to overcome problem of misdiagnosis due to selective sampling. Improper diagnosis may lead to dilemma as treatment of warthin tumour is entirely different from mucoepidermoid carcinoma.

**Case (2) - A case of high grade mucoepidermoid carcinoma was diagnosed as poorly differentiated carcinoma on cytology.** A 41 years old female patient presented with right parotid gland mass. On cytology smears were cellular & showed numerous groups, clusters & syncytial aggregates as well as singly dispersed atypical epithelial cells displaying high N:C ratio, moderate amount of dense basophilic cytoplasm, moderate to high nuclear pleomorphism, against hemorrhagic background suggestive of poorly differentiated carcinoma . On histopathological examination sections showed anastomosing irregular solid islands , nests & sheets of malignant epithelial cells displaying squamoid differentiation & divided by fibrous stroma with focal areas of coagulative necrosis.

**Case (3) - A case of Epithelial myoepithelial carcinoma was diagnosed as pleomorphic adenoma on cytology.** 60 years old female patients presented with left parotid gland mass. On cytology smears were moderately cellular and because of the fibrillar stromal component and uniform epithelial

cells lead to the diagnosis of pleomorphic adenoma. On histopathological examination sections showed tubule, papillary & cribriform islands & solid sheets lined by central cuboidal to low columnar epithelial cells & outer myoepithelial cells. Perineural and lymphovascular invasion were present conforming diagnosis of epithelial myoepithelial carcinoma .

**Case (4) - A case of malignant epithelial tumor Carcinoma ex pleomorphic adenoma was diagnosed as high grade mucoepidermoid carcinoma on cytology.** 59 years old male patients presented with nodular, painless, firm to hard mass over right parotid gland for last 6 years. Cytology smears showed numerous atypical epithelial cells on a mucohemorrhagic background displaying high N:C ratio, moderate amount of dense basophilic cytoplasm, moderate to high nuclear pleomorphism etc.. Few cells having finely vacuolated cytoplasm (???) mucinophages lead to the diagnosis of high grade mucoepidermoid carcinoma. On histology sections showed singly scattered & few small to large islands & sheets of atypical pleomorphic epithelial cells displaying squamoid differentiation infiltrated in stroma, at places showing areas of necrosis. Adjacent parenchyma showed features of pleomorphic adenoma.

**Case (5) - A case of chronic sialadenitis was diagnosed as pleomorphic adenoma with cystic changes on cytology.** A 53 years old male patients presents with nodular, painless, firm to hard mass over right parotid gland from last one year. On cytology smears showed few small cohesive groups, clusters & sheets of benign ductal epithelial cells & acinar cells along with few fibro-myxoid & dirty fibro-collagenous stromal tissue fragments against a hemorrhagic background containing scattered small lymphocytes, polymorphs & cystic macrophages leading to this diagnosis. On histology sections showed diffuse infiltration of salivary gland parenchyma by mononuclear & reactive lymphoid cells with acinar cell atrophy. At places focal areas of fibrosis, hyalinization & myxoid degeneration were also seen.

**Case (6) - A 19 years old male patient who was a case of acinar cell carcinoma was diagnosed as benign cystic lesion on cytology.** On histology tumor mass composed of neoplastic acinar cells forming solid cystic pattern with few large cystic spaces containing eosinophilic material & interspersed lymphoid aggregates. This case was under diagnosed as benign cystic lesion due to selective sampling, age of patient, history of short duration, paucity of cellular component & presence of background mucoid material on cytology .

**Case (7) A case of low grade mucoepidermoid carcinoma in a 63 years old female was diagnosed as mucous retention cyst on cytology.** On aspiration 2.0 ml fluid was aspirated & swelling slightly regressed in size after

aspiration. On cytology numerous groups / clusters and singly scattered mucinophages were seen against a mucoid background containing few sheets of squamous epithelial cells. No atypical or malignant cells were seen leading to the diagnosis of mucous retention test. On histology tumor comprises of mucin filled small to large cystic spaces & glandular structures lined by single layer of mucous cells with pale basophilic cytoplasm along with solid epithelial nests. This case was misdiagnosed due to selective sampling on cytology, so multiple sampling is important to overcome this problem.

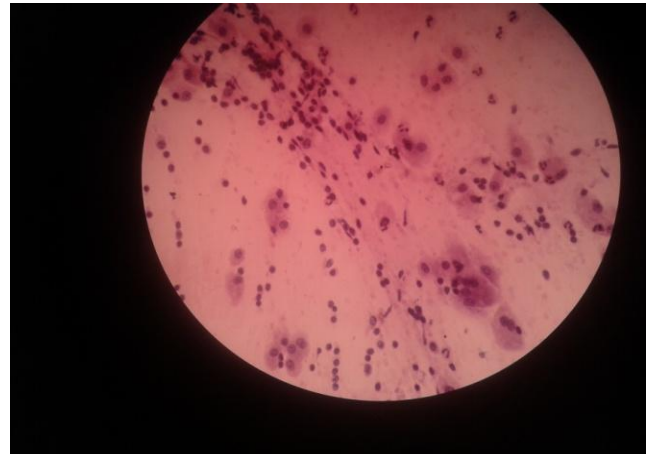
**Case (8)** A case of adenoid cystic carcinoma was diagnosed as basal cell adenoma on cytology because of presence of hyaline globules in a 56 years old male who presented with asymptomatic lump over right parotid region for last 3 years. On cytology few small groups, clusters of small uniform ductal epithelial cells (?) basaloid cell with scant cytoplasm. On histology sections showed solid sheets, cribriform nests or islands & tubules comprising of small bland myoepithelial cells with scant cytoplasm & round to oval angular nuclei surrounded by hyalinised stroma.

**Case (9)**-A case of salivary duct carcinoma was diagnosed as poorly differentiated carcinoma, possibly adenocarcinoma on cytology. A 65 years male patient with left parotid gland mass for last 6 months revealed moderately cellular smears showing groups, clusters, papillaroid fragments & small sheets as well as singly scattered atypical epithelial cells displaying high N:C ratio, coarse granular chromatin etc.. Histopathological picture showed infiltrative tumor mass composed of neoplastic cells displaying abundant eosinophilic cytoplasm, large pleomorphic vesicular nuclei & prominent multiple nucleoli arranged in solid, cribriform & papillary -cystic pattern with vascular & perineural invasion.

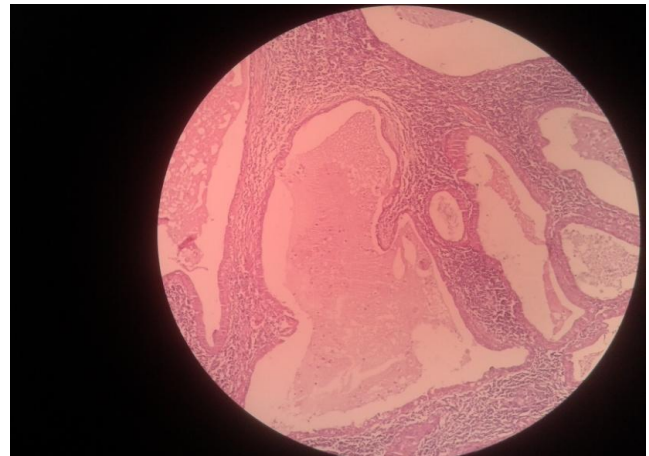
**Case (10)**-A 52 years male patient of Non Hodgkin's lymphoma was diagnosed as chronic sialadenitis on cytology. He had asymptomatic right submandibular gland mass for last 2 years, now gradually increasing in size. Smears were cellular and showed very occasional small groups and clusters of benign ductal epithelial cells against a background containing polymorphous population of mature and transformed reactive lymphoid cells. Histopathological examination revealed extensive heterogeneous proliferation of atypical lymphoid cell with formation of germinal centers at places, replacing the lobular architecture of salivary gland leading to diagnosis of Non hodgkin's lymphoma.

**Table 1:** Showing various types of tumour encountered in the study.

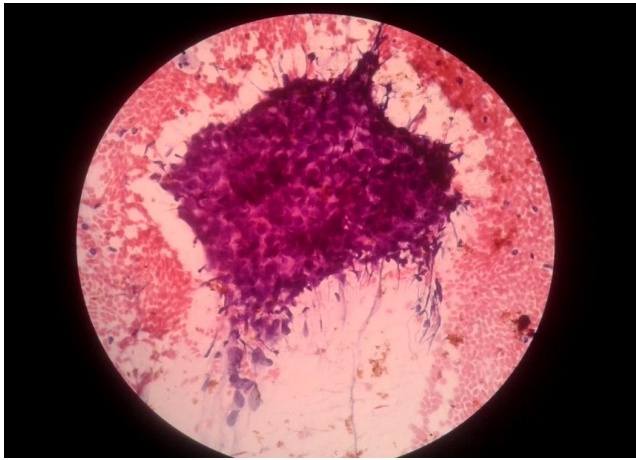
S NO.	Type of tumour	No. of cases
1	Pleomorphic adenoma	23 (46%)
2	Mucoepidermoid carcinoma	12 (24%)
3	Warthin's tumour	4 (8%)
4	Basal cell adenoma	3(6%)
5	Acinic cell carcinoma	1 (2%)
6	Adenocystic carcinoma	3(6%)
7	Lymphoepithelial cyst	2 (4%)
8	Metastatic from other site	1(2%)
9	Hemangioma	1(2%)



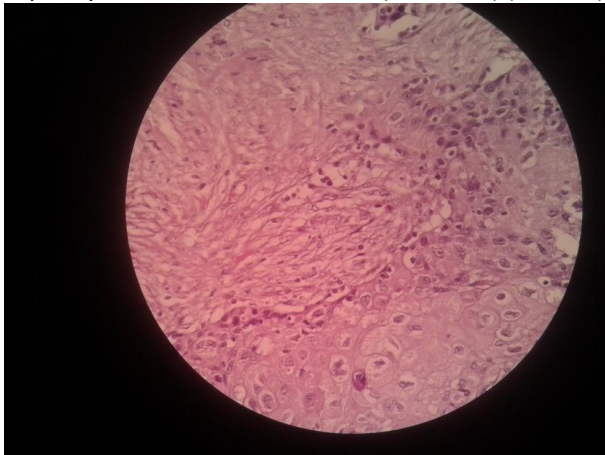
**Figure 1:** Cytology picture of patient was paucicellular and showing few groups or singly dispersed mucinophages against mucoid background suggestive of low grademucoepidermoid carcinoma (HE X400) (CASE-1)



**Figure 2:** Histology picture of same patient showing cystic spaces usually containing a homogenous eosinophilic material, at places forming papillaroid projections lined by double cell layer of atypical epithelial cells with oncocytic changes resting on a dense lymphoid stoma sometime bearing germinal centers suggestive of Warthin's tumour (H & E X400) (CASE-1)



**Figure 3:** Cytology picture showing groups, clusters & syncytial aggregates of malignant cells on haemorrhagic background. Due to poor cellularity, poor differentiation of cells and hemorrhagic background this case was diagnosed as poorly differentiated carcinoma. (PAP X400) (CASE -2)



**Figure 4:** Histology picture of same patient showing anastomosing irregular solid islands, nests & sheets of malignant epithelial cells displaying squamoid differentiation leading to the diagnosis of High grade mucoepidermoid carcinoma –(H & E X400) (CASE -2)

#### Discussion:

Among all human organs, salivary glands offer the largest variety of different histologic types and subtypes of primary neoplasms, most of them arising in the parotid glands.<sup>2</sup> Therefore, it becomes more important to know detailed anatomy and pathologic processes affecting these glands while considering the management of these tumors.<sup>3</sup> Most important factor for choosing the appropriate surgical approach for primary tumor of the salivary glands is not only the preoperative differentiation between a benign or malignant lesion but also the determination of the exact histologic subtype among benign or malignant lesions. Histopathologic grading of malignancies is also useful in the assessment of biologic aggressiveness, response to therapy, and prognosis.<sup>4</sup> The grade of a neoplasm is usually expressed in either numeric

terms (1, 2, 3) or descriptively (well, moderately, or poorly differentiated). The distinction of some low-grade carcinomas from an inflammatory-based sialadenitis may rely on the finding of daughter cyst proliferations from a seemingly hyperplastic duct.<sup>5</sup> Thorvaldson et al concluded that while all mucoepidermoid carcinoma were locally invasive and could recur after surgical removal but it was seen that distant metastasis and death were unlikely in patients with grade 1 and grade 2 while grade 3 carcinomas were fatal in majority of the cases.<sup>6</sup> Robert K Goode et al concluded in his study that features associated with metastasis or death were more advanced age, tumor size, and preoperative symptoms. Histopathologic features that correlated with poor outcome were cystic component less than 20%, 4 or more mitotic figures per 10 high-power fields, neural involvement, necrosis, and anaplasia.<sup>7</sup> Fine-needle aspiration cytology (FNAC) proved to be a useful and reliable tool in the preoperative diagnosis of salivary gland masses when performed by a radiologist or a clinician.<sup>7</sup> In contrast, Das et al<sup>8</sup> reported, in a study of 712 patients, a diagnostic accuracy reaching only from 80% to 91.1%.

Some researchers also believe that a risk of FNAC might be a possible spread of tumor cells, which can lead to a higher likelihood of local recurrence, especially in pleomorphic adenomas and malignant lesions.<sup>9</sup> Basim M et al had a ten year experience of dealing with Fine-needle aspiration of 154 parotid masses and doing histologic correlation while working at university of Texas M.D Anderson Cancer center. A place like this where majority of patients had either a previous history of malignancy or a high clinical likelihood of malignancy, the use of FNA may be approached from a different perspective. They suggested five major indications for obtaining an FNA of the parotid gland as part of the diagnostic workup<sup>10</sup>: 1) to rule out inflammatory lesions; 2) to identify systemic diseases such as reticuloendothelial tumors; 3) to rule out direct invasion of the gland or metastases (although resection of metastases may be performed when the primary tumor was in the head and neck region); 4) to evaluate unresectable lesions and tumors in patients who present as poor surgical candidates; and 5) to evaluate lesions when the probability of a neoplasm is low, such as in children.

C.R. Habermann, et al performed a study of primary parotid gland tumours using Diffusion-Weighted Echo-Planar MR Imaging and concluded that pleomorphic adenomas were also distinguishable from all other entities, except for myoepithelial adenomas. Although both are benign in nature but from surgery point of view pleomorphic adenomas have a risk of malignant transformation (carcinoma ex pleomorphic adenoma) and the surgical approach has to be much more aggressive due to the high

risk of recurrence (eg, lateral or complete parotid resection) with a higher risk of facial nerve injury<sup>11,12</sup>. Otherwise, myoepithelial adenomas have an explicitly lower risk of malignant transformation or recurrences and can, therefore, be resected more conservatively. Use of a combined clinical/radiologic/cytologic "triple test" approach is advocated to minimize false-negative and false-positive FNA diagnoses of parotid masses.<sup>13,14,15</sup>

### Conclusion:

Finally, we can say that knowledge of cytological overlaps and pitfalls of salivary glands FNAC should always be considered. Details of clinical information and radiologic features may help the pathologist to arrive at the appropriate diagnosis and reduce false interpretation. FNAC is highly sensitive and specific technique for diagnosis of many salivary gland swellings. FNAC can be used preoperatively to avoid unnecessary surgery and biopsy. Caution should be taken in reporting of cystic and inflammatory lesions. Selective sampling, poor differentiation of cells, low cellularity of smears due to mucoid material (in cystic lesions) or hemorrhagic aspirate (in vascular tumours) and squamous metaplasia which may be over diagnosed may lead to disparity between cytology and histopathological finding. Multiple sampling from different parts of swelling enhances diagnostic accuracy. It is compulsory and wise conjunction with thorough clinical history, physical examination and other radiological tools like ultrasonography and MRI if required. Some lesions are well-known sources of False-positive or false-negative diagnoses.

### References

1. Boccato P, Altavilla G, Blandamura S. Fine-needle aspiration biopsy of salivary gland lesions: a reappraisal of pitfalls and problems. *Acta Cytol* 1998;42:888–98
2. Seifert G. *Histological Typing of Salivary Gland Tumors. 2nd ed Berlin, Germany: Springer-Verlag;1991 :24–54*
3. Swoboda H, Franz P. Salivary gland tumors: clinical aspects and therapy [in German]. *Radiologe* 1994;34:232–38
4. Evans HL. Mucoepidermoid carcinoma of salivary glands: a study of 69 cases with special attention to histologic grading. *Am J Clin Pathol* 1984;81:696-701.
5. Spiro RH, Huvos AG, Berk R, Strong EW. Mucoepidermoid carcinoma of salivary gland origin. A clinicopathologic study of 367 cases. *Am J Surg* 1978;136:461-8.
6. Vincent L. M. Vander Poorten, Alfonsus J. M. Balm, Frans J. M. Hilgers, I. Bing Tan, Ronald B. Keus and Augustinus A. M. Hart, Stage as major long term outcome predictor in minor salivary gland carcinoma, *Cancer*, 89, 6, (1195-1204), (2000).
7. Robert K. Goode .Paul L. Auclair , Gary L. Ellis Mucoepidermoid carcinoma of the major salivary gland :Clinical and histopathologic analysis of 234 cases with evaluation of grading criteria Volume 82, Issue 7, 1 April 1998: 1217-1224
8. Das DK, Petkar MA, Al-Mane NM, et al. Role of fine needle aspiration cytology in the diagnosis of swellings in the salivary gland regions: a study of 712 cases. *Med Princ Pract* 2004;13:95–106
9. Wong DS, Li GK. The role of fine-needle aspiration cytology in the management of parotid tumors: a critical clinical appraisal. *Head Neck* 2000;22:469–73
10. Basim M. Al-Khafaji M.B., Ch.B. Blake R. Nestok M.D. Ruth L. Katz M.D. Fine-needle aspiration of 154 parotid masses with histologic correlation\* Ten-year experience at the University of Texas M. D. Anderson Cancer Center *Cancer cytopathology/volume 84, issue 3*
11. C.R. Habermann, C. Arndt, J. Graessner, L. Diestel, K.U. Petersen, F. Reitmeier, J.O. Ussmueller, G. Adam and M. Jaehne *American Journal of Neuroradiology* March 2009, 30 (3) 591-596
12. Prades JM, Oletski A, Faye MB, et al. Parotid gland masses: diagnostic value of MR imaging with histopathologic correlations *Morphologie* 2007;91:44–51
13. Ljung BME, Hanafee W. CT scanning and aspiration cytology in the management of parotid lesions. *Rev Laryngol Otol Rhinol (Bord)* 1984; 105 (1): 21-4.
14. Owen EERTC, Banerjee AK, Prichard AJN, Hudson EA, Kark AE. Role of fine-needle aspiration cytology and computed tomography in the diagnosis of parotid swellings. *Br J Surg* 1989; 76: 1273-4.
15. Batsakis JG, Sneige N, El-Naggar AK. Fine-needle aspiration of salivary glands: its utility and tissue effects. *Ann Otol Rhinol Laryngol* 1992; 101: 185-8.