

## FINDING A SIMPLIFIED CLINICAL SCORE FOR DIAGNOSIS AND TREATMENT OF ENDOMETRIOSIS WITHOUT CHOCOLATE CYST

Bagchi Bishista<sup>1</sup>, Chatterjee Siddhartha<sup>2</sup>, Chatterjee Arpan<sup>3</sup>

<sup>1</sup>Clinical Associate, Calcutta Fertility Mission, 21 Bondel Road, Kolkata

<sup>2</sup>Director, Calcutta Fertility Mission, 21 Bondel Road, Kolkata

<sup>3</sup>Specialist consultant, ESI Hospital, Kolkata

**Article Info:** Received 18 March 2020; Accepted 28 April 2020

**DOI:** <https://doi.org/10.32553/ijmbs.v4i4.1096>

**Corresponding author:** Dr. Siddhartha Chatterjee

**Conflict of interest:** No conflict of interest.

### Abstract

**Introduction:** This study has been proposed to evaluate the feasibility of trans-vaginal and trans-abdominal ultrasonography (USG) in screening of endometriosis.

**Methods:** This was a retrospective observational study in which women with clinical symptoms, features and family history of endometriosis were included. Women with diagnosed endometriosis on treatment, with chocolate cyst or adenomyosis were excluded. The ultrasound features in patients with suspected endometriosis were correlated with the laparoscopy findings and a new scoring system has been introduced to facilitate the management of the disease. **Results:** 2080 patients were examined clinically either by per-vaginal or by per-rectal examination (in adolescents, unmarried patients) and the findings were noted and ultrasound was performed. 489 of these women had undergone laparoscopy. Combined clinical score of 1-3 is associated with USG score 1. The visualisation shows that combined clinical score of 7-9 is associated with laparoscopy score 4 and combined clinical score of 1-3 is associated with laparoscopy score 2. Combined clinical score 10-12 is highly differentiated statistically. **Conclusion:** Clinical symptoms, signs along with USG findings have been seen to be quite helpful to screen endometriotic cases and thereby they should be followed up closely to detect its presence. In extremely doubtful cases laparoscopy should be performed for detection of the foresaid disease. It is very important to note that the clinical score and USG score corresponds to a large extent to laparoscopy score as mentioned in the results.

**Keywords:** endometriosis, trans-vaginal, trans-abdominal, ultrasonography, clinical score, laparoscopy

### List of abbreviations

USG – Ultrasonography

MRI –Magnetic Resonance Imaging

POD- Pouch of Douglas

VAS- Visual Analogue Scale

TVS- Trans-vaginal ultrasonography

TRUS- Trans-rectal ultrasonography

USL- utero-sacral ligament

### Introduction

Endometriosis is a debilitating chronic inflammatory disease with probable immunological etiology affecting millions of women worldwide, restricting their day to day normal life style activities, taking a heavy toll on their physical and mental health. The prevalence of endometriosis has been documented to be about 47% with or without being symptomatic.<sup>1</sup> Endometriosis usually presents with dysmenorrhea, dyspareunia or chronic pelvic pain, infertility, generalised fatigue, tenesmus, dyschezia, dysuria, haematuria and a compromised sense of well-being.<sup>2</sup> If both endometriosis and infertility are considered the frequency rises to as high as 35–50%.<sup>3</sup> This chronic disease requires a personalized management( including psychological counselling) plan with the goal of maximizing

medical treatment and trying to avoid repeated surgical procedures. The treatment for endometriosis is essentially chosen by each individual woman, depending on symptoms, age and whether she wants conception. But the present scenario demands a diagnosis of endometriosis at an early stage with preferably non-invasive tools and there after prompt initiation of the management.

There is a recent trend of diagnosing endometriosis by non-invasive procedures which has also been supported by the regulatory authorities worldwide. Prevalence of endometriosis has been observed from adolescence to adults and non-invasive procedures are always more welcome in younger patients. Imaging, essentially a 5-domain ultrasonography (USG) based approach has become one of the cornerstones to detect

endometriosis.<sup>4,5</sup> USG is widely available; easy to perform imaging technique and is well-accepted that intra-cavitary USG like trans-vaginal (TVS) or trans-rectal ultrasound (TRUS) are more informative than trans-abdominal route (pelvic ultrasonography). But in South-Asian countries like ours TRUS is not at all accepted by patients and trans-vaginal route can be applied only for sexually active women. For large number of young and adolescent patients who are not sexually active, one has to depend on abdominal ultrasonography findings. In this study, an attempt has been undertaken to frame a reasonable scoring system based on the clinical symptoms, signs and ultrasonography features to diagnose endometriosis. These findings were also corroborated with the laparoscopy findings done as a part of the infertility work-up in certain number of patients, to substantiate the findings with the non-invasive procedure.

**Materials and methods**

About 11856 new patients had visited our clinic from January 2014- December 2018 out of which, 3556 (around 30%) patients had come up with complaints of pain during menstruation, chronic pelvic pain, irregular menstrual cycles or history of early menarche – all being symptoms suggestive of endometriosis. All these patients were examined clinically and then subjected to ultrasonography (by abdominal or vaginal route) (USG). 3270 (90%) of them were suspected to have endometriosis.

The study has been undertaken to find out if correlation of clinical symptoms and USG finding scan be used as a screening tool to detect early endometriosis (stage I and II) in these young women. Few of them had undergone laparoscopy as investigation for infertility and the findings were corroborated (**Table 2**).

**Inclusion criteria:**

- Age group – 16-25years
- Patients with complaints of dysmenorrhea, dyspareunia, chronic pelvic pain
- Known patients of Polycystic ovarian disease/syndrome

**Exclusion criteria:**

- Patients >25 years as most of them had advanced endometriosis
- Patient with diagnosed ovarian chocolate cyst
- Patients with adenomyosis
- Patients with non- gynecological abdominal pain

Patients with the above-said complaints were subjected to ultrasonography and an attempt was made to screen the underlying pathology correlating the clinical findings and radiological features. These patients were assigned different scores depending on their symptoms (Score 1,2or 3); clinical findings (Score 1, 2 or 3 ) ; their respective ultrasonography features (Score 1,2 or3) and family history of diagnosed endometriosis (Score 1,2 or 3). The combined score was named as Clini score (Table 1).

**Result:**

**Table 1: CLINI SCORE**

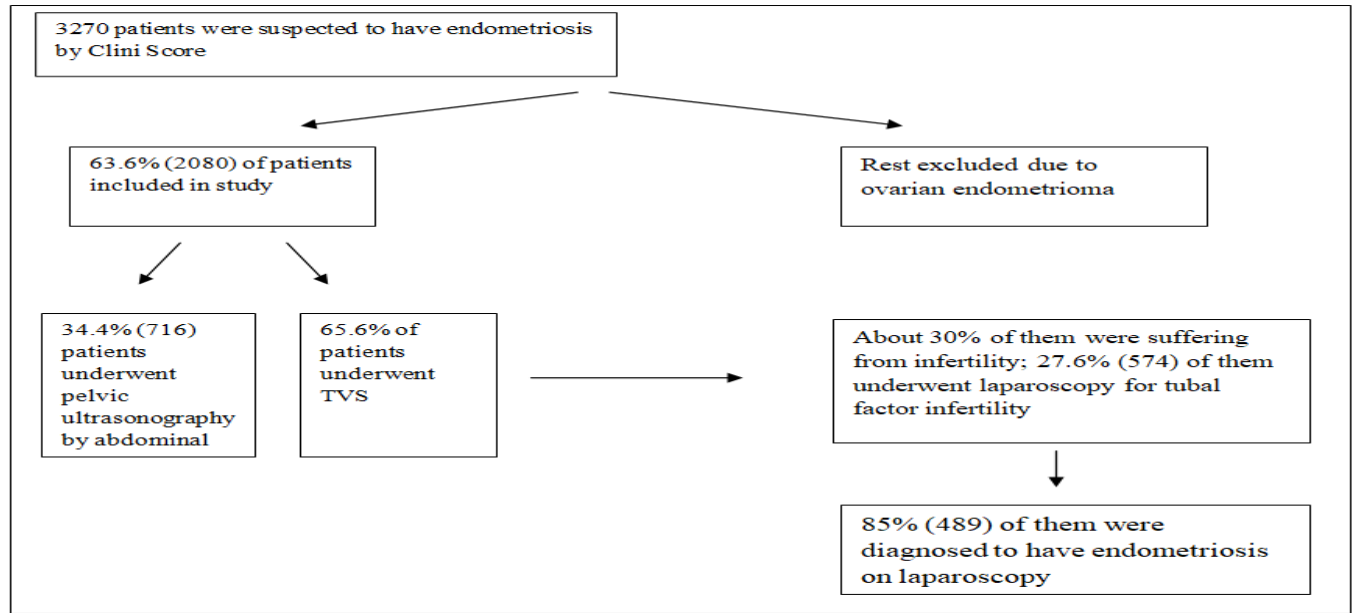
Score	Clinical symptoms	Family history	Clinical findings/signs	USG findings	Total Score
1	Dysmenorrhea (VAS pain score 3-4)	no family history	displaced uterus (uterus pulled to one side, retroverted/anteverted uterus)	distorted uterine anatomy (uterus pulled to one side, difficult to find the uterus)	
1	Dyspareunia (VAS pain score 3-4)	history of endometriosis in 2 <sup>nd</sup> degree relative	restricted mobility of uterus	ovarian adhesions / variegated ovaries	12
1	chronic pelvic pain (VAS pain score 2-3)	history of endometriosis in 1 <sup>st</sup> degree relative	tenderness, nodules in POD	thickened POD/ tenderness in POD	
Score	Clinical symptoms n(%)	Clinical history n(%)	Clinical signs n(%)	USG features n(%)	
1	487 (23.5)	894 (43)	710 (34.2)	610 (29.3)	
2	812 (39.03)	437(21)	800 (38.4)	764 (36.7)	
3	781 (37.5)	748(36)	570 (27.4)	706 (34)	

**Table 2: Laparoscopy findings- Score 2 – 8; each finding individually was assigned a score of 2**

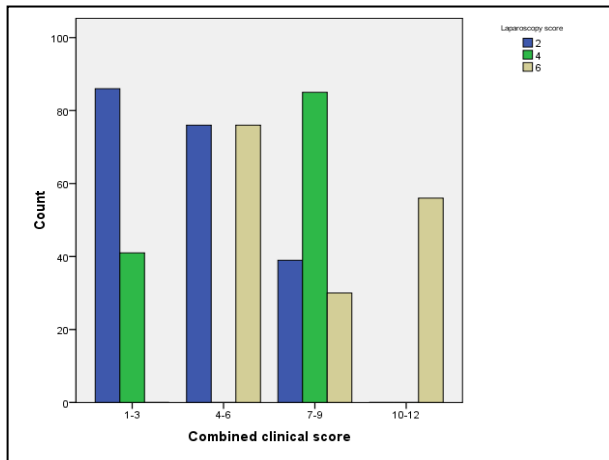
LAPAROSCOPY FINDINGS	SCORE
Anatomical changes of uterus (acute AV/RV, pulled to one side)	2
Surface and ligament involvement ( <b>thickened uterosacrals -USL</b> ); pulled up tubes and ovaries distorting the tubo-ovarian relationship due to involvement of the <b>infundibulopelvic</b> ligaments ; pulled aside cervix due to <b>thickened Mackenrodt's</b> ligament)	2
Ovarian involvement(adherent to uterus, in POD, variegated)	2
POD involvement(obliteration, pseudocavitation)	2

**Table 3: Plan of management**

CLINI SCORE	Nos. of patients (%)	MANAGEMENT PLAN
1-3	604(29.2)	Diagnostic laparoscopy may be individualised– most possible zone – trial treatment
4-6	730(35)	Diagnostic laparoscopy can be avoided- most probable zone – medical treatment
7-9	590(28.3)	Diagnostic laparoscopy not required – definitive zone – definitive treatment
10-12	156 (7.5)	Diagnostic laparoscopy not required – definitive zone – definitive treatment

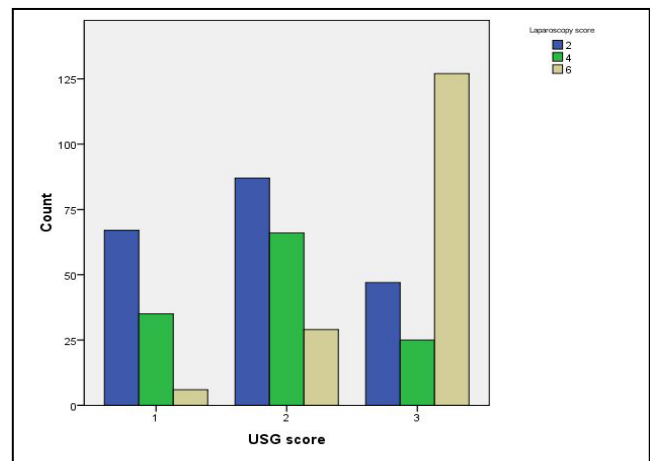


**Statistical Analysis:**



**Figure 1**

The bar graph (Figure 1) of combined clinical score clustered by laparoscopy score shows that maximum patients with laparoscopy score of 2 in combined clinical score of 1-3. Laparoscopy score of 4 is maximum in combined clinical score of 7-9 and only patients with laparoscopy score of 6 and 8 in combined clinical score of 10-12.



**Figure 2**

The bar graph (Figure 2) of USG score clustered by laparoscopy score shows that maximum patients with laparoscopy score of 2 in USG score of 1 and 2. Laparoscopy score of 6 and 8 are maximum in USG score of 3.

The Pearson’s Chi-square test for independence of Clini score and Laparoscopy score finds that both scores are significantly associated. The Pearson’s Chi-square test for

independence of USG score and Laparoscopy score also finds that both these scores are significantly associated.(Table 4)

**Table 4:** Contingency table of Clini Score, USG score and Laparoscopy Score

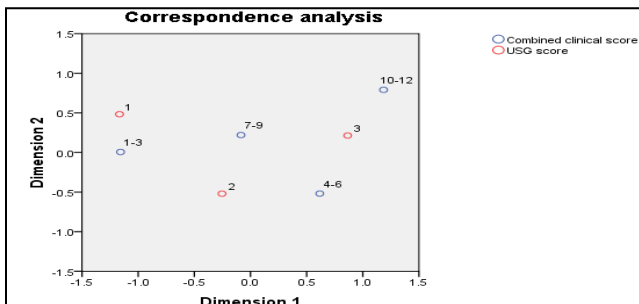
Laparoscopy Score	Clini Score				USG Score		
	1-3	4-6	7-9	10-12	1	2	3
2	66	01	41	00	67	35	06
4	61	63	52	06	87	66	25
6,8	00	88	61	50	47	29	127

Pearson Chi-Square = 207.801, DF = 6, P-Value = 0.000

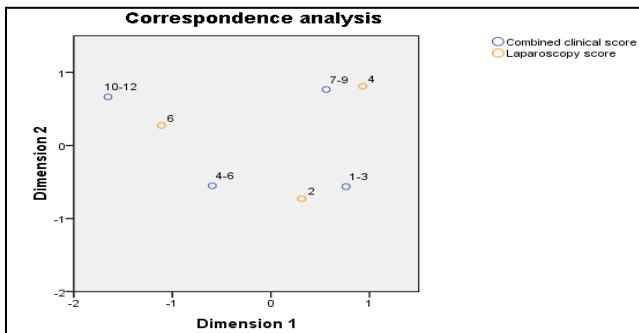
The chi-square test for independence of Clini score and Laparoscopy score finds that both scores are significantly associated.

Pearson Chi-Square = 149.005, DF = 4, P-Value = 0.000

The chi-square test for independence of USG score and Laparoscopy score finds that both scores are significantly associated.



**Figure 3A:**



**Figure 3B:**

The graph (3A) is a representation of correspondence analysis of combined clinical score and USG score. The visualisation shows that combined clinical score of 1-3 is associated with USG score 1. Combined clinical score 10-12 (at the top) is highly differentiated.

The graph (3B) is a representation of correspondence analysis of combined clinical score and Laparoscopy score. The visualisation shows that combined clinical score of 7-9

is associated with laparoscopy score 4 and combined clinical score of 1-3 is associated with laparoscopy score 2. Combined clinical score 10-12 (at the top) is highly differentiated.

**Table 5:** Multivariate Ordinal regression of Laparoscopy score:

Predictor	Coef	SE Coef	Z value	P value	Odd Ratio	95% CI	
						Lower	Upper
Const(1)	1.627	0.265	6.130	0.000			
Const(2)	3.747	0.315	11.870	0.000			
Clinical score	-0.711	0.112	-6.370	0.000	0.490	0.390	0.610
USG score	-0.880	0.123	-7.160	0.000	0.410	0.330	0.530

The ordinal regression of laparoscopy score shows that both clinical score and USG score are significantly associated with laparoscopy score.

**Discussion**

Diagnosing endometriosis still remains a dilemma due to the non-specific nature of the symptoms and the difficulty in distinguishing pelvic pain due to endometriosis from that caused by pelvic infection or other non-gynaecological conditions. This results in a considerable delay in diagnosis with deterioration in quality of life and psychological morbidity. In the last few decades, non-invasive screening for endometriosis has been made possible by advances in imaging techniques such as ultrasonography and magnetic resonance imaging (MRI).<sup>6,7</sup> The value of ultrasound for the diagnosis of ovarian endometriosis has already been established. Trans-rectal and trans-vaginal ultrasound have been found to be more useful in the diagnosis of non-ovarian features of endometriosis, such as intestinal, bladder and USL involvement.<sup>8-10</sup> One study suggests that a hyperechoic layer in the region of the USL (the ‘white line’) slides freely over the vaginal wall when transducer pressure is applied and released and in case of superficial endometriosis, the white line thickens and TVS was found to be highly specific though the sensitivity was not satisfactory.<sup>11</sup> TVS should be regarded as the first-line imaging modality in evaluating patients with suspected endometriosis as its accuracy has greatly improved over recent years as medical professionals have become aware of the various sonographic aspects of endometriosis. The only limitation of this being the detection by ultrasound is heavily operator-dependent.<sup>6</sup> Similar opinion has been given by many other researchers and they have even specified diagnostic accuracy of ovarian immobility for disease location in women with isolated superficial endometriosis showed a high specificity and negative predictive value, suggesting that it is less likely to be present in women with a mobile ovary.<sup>12</sup> These opinions are quite similar to the ultrasonography (both by abdominal and vaginal route) findings in our study in which

ovarian adhesion and changes in the uterine anatomy have been considered as important features in screening of endometriosis. Real-time dynamic TVS evaluation has established with a high degree of certainty whether the POD is obliterated and has also been seen to point out higher risk of bowel endometriosis in such patients.<sup>13, 14</sup>

The thickening of POD on pelvic scan by abdominal route or tenderness in the POD on trans-vaginal ultrasound has been shown as a very promising feature of endometriosis in our study too. Abdominal USG in young, sexually inactive women have proved to be very promising particularly in the hand of gynaecologists treating the patients. All the features mentioned in the study can be well-documented by USG performed by abdominal route as the recent day USG machines have more and more clarity to identify the pelvic organs and their pathology very clearly. When these findings are corroborated with clinical symptoms and signs, detection of endometriosis becomes more accurate. It is also observed in certain patients, though asymptomatic, still have early endometriosis. Clinical symptoms, signs along with USG findings have been seen to be quite helpful to screen endometriosis cases and thereby they should be followed up closely to detect its presence. In extremely doubtful cases laparoscopy should be performed for detection of the foresaid disease. It is very important to note that the clinical score and USG score corresponds to a large extent to laparoscopy score as mentioned in the results. In case it is difficult to perform laparoscopy or one wants to avoid invasive laparoscopy definitive treatment or trial of treatment can be started depending on reasonable evidence. The Clini Score has explained that the role of diagnostic laparoscopy is limited even in Score 1-3. Laparoscopy is indicated for treatment purpose as for promotion of fertility by recovering tubo-ovarian relation. Sometimes laparoscopy determines the nature of treatment and whether Assisted Reproductive Technique is necessary.

#### Conclusion:

Primarily, in infertile women finding a clinical score (Clini Score) in association with clinical history, symptoms, signs and USG features, for diagnosis and planning a treatment for endometriosis, can help us treat the hellion behind the blow.

**Declarations:** Ethics approval and consent to participate-The Ethical Committee of Calcutta Fertility Mission has given clearance for the retrospective study of a prospective database on 20/07/2019 (code: CFM/2019/026). Written informed consent has been obtained from all women who participated in the study.

Consent for publication -Written informed consent has been obtained from all women who participated in the study and they were explained about the publication and had consented for.

Availability of data and material – Institute’s prospective database

Competing interests– None

Funding – Intramural Grant

**Acknowledgements:** We, the authors acknowledge Mr. Arabinda Das for preparation of statistical analysis and Ms.Orphi Bhattacharya for formatting the manuscript.

#### References

1. Meuleman C, Vandenabeele B, Fieuws S et al. High prevalence of endometriosis in infertilewomen with normal ovulation and normospermicpartners. *FertilSteril*. 2009; 92:68-74.
2. Bulletti C, Coccia ME, Battistoni S, Borini A. Endometriosis and infertility. *J Assist ReprodGenet*. 2010;27(8):441–447.
3. Endometriosis. Giudice LC, Kao LC *Lancet*. 2004; 364(9447):1789-99.
4. Menakaya U, Reid S, Infante F et al. Systematic evaluation of women with suspected endometriosis using a 5-domain sonographically based approach. *J Ultrasound Med*. 2015; 34:937–947.
5. Holland TK, Cutner A, Saridogan E et al. Ultrasound mapping of pelvic endometriosis: doesthe location and number of lesions affect the diagnostic accuracy? A multicentre diagnosticaccuracy study. *BMC Womens Health* 2013; 13: 43.
6. Savelli L. Transvaginalsonography for the assessment of ovar-ian and pelvic endometriosis:how deep is our understanding? *Ultrasound Obstet Gynecol*2009;33: 497 – 501.
7. Abrao MS, Goncalves MO, Dias JA et al. Comparison between clinical examination, transvaginalsonography and magnetic resonance imaging for the diagnosis of deependometriosis. *Hum Reprod*2007;22:3092 – 3097
8. Bazot M, Detchev R, Cortez A et al. Transvaginalsonography and rectal endoscopic sonography for the assessment of pelvic endometriosis: a preliminary comparison. *Hum Reprod* 2003;18: 1686 – 1692.
9. Ohba T, Mizutani H, Maeda T et al.Evaluation of endometriosis in uterosacral ligaments bytran-srectal ultrasonography. *Hum Reprod* 1996;11: 2014 – 2017.
10. Chapron C, Dumontier I, Dousset B et al. Results and role of rectal endoscopic ultrasonography for patients withdeep pelvic endometriosis.*Hum Reprod*1998;13: 2266 – 227
11. Robinson, A. J., Rombauts, L., Ades, A. et al. Poor sensitivity of transvaginal ultrasound markers in diagnosis of superficial endometriosis of the uterosacral ligaments. *Journal of Endometriosis and Pelvic Pain Disorders*. 2018; 10(1):10–17.
12. Reid S, Leonardi M, Lu C, Condous G. The association between ultrasound-based 'soft markers' and endometriosis type/location: A prospective observational study. *Eur J Obstet GynecolReprod Biol*. 2019;234:171-178.
13. Reid S, Lu C, Casikar I et al. Prediction of pouch of Douglas obliteration in women with suspected endometriosis using a new real-time dynamic transvaginal ultrasound technique: the sliding sign. *Ultrasound Obstet Gynecol*. 2013 Jun;41(6):685-91.
14. Reid S, Lu C, Casikar I et al. The prediction of pouch of Douglas obliteration using offlineanalysis of the transvaginal ultrasound 'sliding sign' technique: inter- and intra-observerreproducibility. *Hum Reprod*. 2013;28(5):1237-46.