

EVALUATION OF CLINICAL AWARENESS OF LOOSENESS OF A NEWLY FABRICATED COMPLETE DENTURE AND ITS MANAGEMENT AMONG DENTAL STUDENTS IN A DENTAL COLLEGE OF IMPHAL (NORTH- EAST): A CROSS-SECTIONAL STUDY.

Arunoday Kumar¹, Rajesh. S. Nongthombam², Barun Kant³, Nishant Kumar Tewari⁴, Aditi Sinha⁵, Sushmita Tiwari⁶

¹Assistant Professor, Dept. of Prosthodontics and Crown & Bridge, Dental College RIMS, Imphal, Manipur, India

²Associate Professor, Dept. of Prosthodontics and Crown & Bridge, Dental College RIMS, Imphal, Manipur, India

³Senior Lecturer, Department of Prosthodontics and Crown & Bridge, Hazaribag College of Dental Sciences and Hospital, Hazaribag, Jharkhand, India

⁴Dental Surgeon, Dept. of Oral and Maxillofacial Surgery, Nalanda Medical College and Hospital, Patna, Bihar

⁵Dental Surgeon, Department of Prosthodontics and Crown & Bridge, Private Practice, Gaya, Bihar.

⁶Dental Surgeon, General Practitioner, Patna, Bihar.

Article Info: Received 14 February 2020; Accepted 16 March 2020

DOI: <https://doi.org/10.32553/ijmbs.v4i3.1045>

Corresponding author: Dr. Arunoday Kumar

Conflict of interest: No conflict of interest.

Abstract

Introduction: For the patient's dissatisfaction with the prosthesis, dentist must realize that a patient's judgment of the treatment outcome is what defines prosthodontic success. All patient's need is to have a denture which is firm and stable during function. An ill-fitting denture not only brings frustration to the patients but to the dentists as well. So all probable reasons for the looseness of complete denture should be evaluated by the dentist and hence every possible attempt should be made by the dentist to correct it.

Aims and Objectives: The aim of this study was to assess the knowledge of looseness of newly fabricated complete denture and its management among dental students of third year, final year and internship, studying in an undergraduate dental college, in the Imphal city of Manipur. The objective of this study was to assess the relationship between the complete knowledge of complete denture fabrication and their practical implementation in the complete denture fabricational procedure.

Materials and Methods: A descriptive, cross-sectional survey was conducted using a self-administered questionnaire involving the dental students of 3rd, 4th year and the students doing internship in the Department of Prosthodontics and Crown & Bridge at RIMS, Dental college. Total of 150 students participated in the study. Participants were distributed in three groups having 50 students each from 3rd year, 4th year, and students doing internship. All the participants signed an informed consent before filling the questionnaire. Descriptive statistics included computation of frequencies and percentages. Nonparametric test, namely, chi-square test, was used for further data analysis; p-value <0.05 was considered statistically significant and vice versa.

Results: Among all 150 participants who were subjected to self-administered questionnaire, seventy eight (78) subjects (52%) reported that looseness was because of improper secondary impression. Eight (08) subjects (05.33%) reported that looseness was because of under extension of the green stick compound for peripheral tracing. Three (03) subjects (02%) reported that looseness was because of the overextension of the flanges in peripheral tracing or border moulding. Fifty eight (58) subjects (38.66%) reported that looseness of the newly fabricated complete denture was because of improper posterior palatal seal area record. Three (03) subject (2%) reported that they were unaware of the reasons for the looseness of newly fabricated complete denture.

Conclusion: The majority of the students of dental college have limited knowledge of the exact reason for the looseness of newly fabricated complete denture on the day of denture delivery. Students faced problem in its management in dental clinics. The looseness of a newly fabricated complete denture was because of the overextensions of the denture flanges as evaluated by Prosthodontist. Students of dental college should be made aware for the all the probable reasons for looseness of a newly fabricated complete denture. In 90% of the cases it is seen that overextension of the flanges is the most probable reason for an ill fitting, newly fabricated complete denture.

Keywords: Complete Denture, Ill fitting denture, Peripheral tracing, Denture Flanges, Secondary Impression, Posterior Palatal Seal.

Introduction:

Rehabilitation of missing teeth with the conventional complete denture not only restores back the function of good chewing and incising efficiency but also good aesthetics and phonetics. Prognosis of a complete denture in terms of retention, stability, support and comfort of the patient are the very important criteria to be considered to deliver a successful denture. Retention of a complete denture is the ability of the prosthesis to withstand vertical displacement away from the tissue. Whereas stability and support of the denture is the ability of the prosthesis to withstand side to side movement and resist vertical displacement towards the tissue respectively. Good retention, stability and support of complete denture is attained when all the factors responsible for the fabrication of complete denture is taken into consideration in its fabricational procedure. Retention of a complete denture is governed by anatomical, physiological, physical, mechanical, muscular factors. Of all the factors responsible for the retention of complete denture, extent of denture flanges in the limiting or peripheral structures of denture bearing areas often go unnoticed. Extent of buccal, labial, palatal and lingual flanges is measured in two dimensions of height and width. Height and width of the flanges are evaluated based on the functional moulding and is adjusted based on the existing depth and width of the vestibules in the patient's mouth. Overextension to any extent would hamper with the retention of the complete denture. All patient's need is to have a denture which is firm and stable during function. An ill-fitting denture not only brings frustration to the patients but to the dentists as well. So all probable reasons for the looseness of complete denture should be evaluated by the dentist and hence every possible attempt should be made by to correct it especially the overextension of the flanges has to be evaluated and need fully corrected.

Materials and Methods:

A descriptive, cross-sectional survey was conducted using a self-administered questionnaire involving the dental students of 3rd and 4th year BDS and the students doing internship in the Department of Prosthodontics and Crown & Bridge at RIMS, Dental college. Total of 150 students participated in the study and they comprised of 50 students each from 3rd year, 4th year, and students doing internship, from Dental college RIMS, Imphal. All subjects signed an informed consent before filling the questionnaire. Descriptive statistics included computation of frequencies and percentages. Nonparametric test, namely, chi-square test, was used for further data analysis; p-value <0.05 was considered statistically significant and vice versa. The patient with well healed round residual alveolar ridges with well adherent alveolar mucosa, mixed salivary consistency, good neuromuscular coordination and patient of philosophic type were included in the study.

Patients with severely resorbed residual alveolar ridges, purely mucous or purely serous salivary consistency, poor neuromuscular coordination and the patients of hysterical or critical type were excluded from the study. The Participants were subjected to the following questionnaire. Questionnaires: Most probable reason for the looseness of newly fabricated complete denture on the day of denture delivery is:

- 1) Improper secondary impression. Yes No
- 2) Improper posterior palatal seal area record. Yes No
- 3) Overextended peripheral tracing. Yes No
- 4) Under extended peripheral tracing. Yes No
- 5) Unaware. Yes No

Data collection:

Data was collected based on the questionnaire distributed to the students of dental college who participated in the study (Fig. 1).

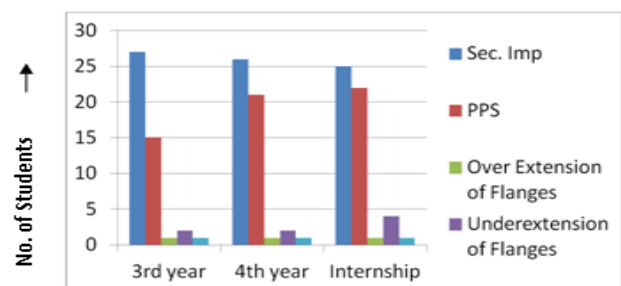


Fig.1: Graphical representation of data collected.

Results:

A total of 150 individuals were approached for participation in our survey. Among all the subjects interviewed: 78 (52%) reported that looseness was because of improper secondary impression. 08 subjects (05.33%) reported that looseness was because of under extension of the green stick compound for peripheral tracing. 03 subjects (02%) reported that looseness was because of the overextension of the green stick compound in peripheral tracing which has led to overextended flanges of denture. 58 subjects (38.66%) reported that looseness of the newly fabricated complete denture was because of improper posterior palatal seal area record. 03 subject (2%) reported that they were unaware of the reasons for the looseness of newly fabricated complete denture.

Statistical analysis: Data collected from questionnaire were subjected to chi-square statistical analysis.

Table 1: Data for Chi- Square test, statistical analysis.

Students	Improper Secondary. Impression.	Improper Posterior Palatal Seal Area.	Over Extension of Denture Flanges	Under Extension of Denture Flanges	Unaware	Row Totals
3 rd BDS.	27	15	1	2	1	46
4 th BDS.	26	21	1	2	1	51
Internship Students	25	22	1	4	1	53
Column Total	78	58	3	8	3	150 (Grand Total)

The chi-square statistic is $\chi^2 = 2.0579$. The p -value is 0.979 (>0.05 , insignificant)

There was an insignificant difference in the knowledge for the reasons of looseness of new denture on the day of denture delivery ($\chi^2 = 2.0579$, $p > 0.05$) among all the students who participated in the study. All the students of 3rd, 4th and internship reacted the same way giving the reason of improper secondary impression and improper PPS. area record as being the primary cause of ill-fitting of Denture. Though the reason was because of overextension of the flanges as evaluated by the MDS faculty of Prosthodontics department.

Discussion:

The majority of the students of dental college have limited knowledge of the correct reason for the looseness of new denture on the day of denture delivery and its management in dental clinics. Though the looseness of the new denture was because of overextension of the denture flanges which was inferred by a dental MDS faculty after thorough evaluation of the new denture. Dental students were getting confused and majority of them inferred of it being because of improper secondary impression followed by improper posterior palatal seal area Record. The overextended flanges were subsequently corrected by trimming and polishing of the overextensions in terms of height and width. So, it is to conclude that complete evaluation of the new denture on the day of denture insertion has to be done. The students should have complete knowledge of all the probable reasons for the looseness of complete denture so as to give a successful denture delivery. This would prevent frustration among dental students which is because of denture delivery failure.

Conclusion:

Students of dental college should be made aware for the all probable reasons for looseness of a newly fabricated complete denture. Most often it is seen that overextension of the flanges is the most probable reason for the denture looseness on the day of denture delivery. Students should evaluate the complete denture carefully and look for overextensions in the buccal and labial flanges so as to do the needful corrections. Overextension corrections can be done by trimming and polishing the overextended flanges under functional moulding of the oral tissues. Post insertion check up of the patient should be done for the evaluation of the denture in terms of retention, stability and support. Any abused tissues should be looked for which is caused because of overextension of flanges in the

peripheral anatomical structures. The correction of overextension should be done to deliver a successful complete denture.

References:

1. Atwood, D.A. Reduction of residual ridges; a major oral disease entity. *J Prosthet Dent* 1971; 26: 266-279
2. Turner M, Jahangiri L, Ship JA. Hyposalivation, xerostomia and the complete denture: a systematic review. *J Am Dent Assoc.* 2008 Feb; 139(2):146-50.
3. Hammond, J. and Thomson, J.C.. Diagnosis of complete denture difficulties. *Dental Update* 1982; 9:35-408.
4. Wright, SM, The polished surface contour: a new approach. *International Journal of Prosthodontics* 1991; 4:159-163
5. Gunnar E. Carlsson, Odont Dr and Dr Odont HC. Clinical morbidity and sequelae of treatment with complete dentures. *J Prosthet Dent* 1998; 79 (1): 17-23.
6. Oral mucosal lesions associated with the wearing of removable dentures. BudtzJørgensen E. *J Oral Pathol.* 1981 Apr; 10(2):65-80
7. Yoshizumi DT. An evaluation of factors pertinent to the success of complete denture service. *J Prosthet Dent* 1964; 14:866-78.
8. George A Zarb, Charles L Bolender, Gunnar E Carlson. Bouchers prosthodontic treatment for edentulous patients. 11th Edition, chapter 3, Page 30.
9. John J Sharry. Complete denture Prosthodontics, 2nd edition, chapter 24, page 358.
10. A.A. Grant, J.R. Heath, J.F. McCord- complete prosthodontics problems, diagnosis & management (1994)
11. Sheppard IM, Schwartz LR, Sheppard SM. Oral status of edentulous and complete denture-wearing patients. *J Am Dent Assoc* 1971; 83:614-20.
12. Tallgreen, R. The continuing reduction of the residual alveolar ridges in complete denture wearers: a mixed longitudinal study. *J Prosthet Dent* 1972; 27:120-132
13. Tuckfield WJ. The problem of mandibular denture. *Aust J Dent.* 1952; 56(1):36-49.19.
14. Kuebker WA. Denture problems: causes, diagnostic procedures, and clinical treatment. 1. Retention problems. *Quintessence Int* 1984; 15: 1031-44.
15. Carr, L, Wolfaardt, J.F. and Haitas, G.P. Speech defects in prosthetic dentistry. *Journal of the Dental Association of South Africa*, 1985; 40:387-390
16. Brisman, A.S. Aesthetics: a comparison of dentist's and patients concepts. *Journal of American dental association* 1980; 100; 345
17. Tourne, L.P., Luc, P.M. and friction, J.R. Burning mouth syndrome. *Oral Surgery, Oral Medicine, Oral Pathology* 1992; 74:158-1674.
18. Nater JP, Groenman NH, Wakkers-Garritsen BG, Timmer LH. Etiologic factors in denture sore mouth syndrome. *J Prosthet Dent* 1978; 40 (4) : 367-73.
19. Arendorf, T.M. and Walker, D.M. Denture stomatitis review. *Journal of Oral Rehabilitation*, 1987; 14:217-227. 4.
20. G. Van Huysen, Lieutenant Colonel William Fly and Major L. Leonard: Artificial Dentures and the Oral Mucosa. *J Prosthet Dent* 1954; 4 (4): 446-60.
21. Conny D J and Tedesco L A. The gagging problem in prosthodontic treatment identification and causes. *J Prosthet Dent* 1983; 49:601-06
22. G. S. Bassi, BDS, G. M. Humphris, J. The etiology and management of gagging: A review of the literature *J Prosthet Dent* 2004; 91:459-67.
23. Tahereh G, Fahimeh H R, Sepideh M K. Evaluation of the Effect of Upper Complete Denture on Gustatory and Olfactory Senses *J Dent Res Dent Clin Dent Prospects.* 2009 Autumn; 3(4): 132-135.