

INDIVIDUALIZED HOMOEOPATHIC TREATMENT OF CONTACT DERMATITIS: A CASE REPORT

Indrajeet Shah

Department of Medicine, MNR Homoeopathic Medical College and Hospital, Sangareddy

Article Info: Received 14 February 2020; Accepted 14 March 2020

DOI: <https://doi.org/10.32553/ijmbs.v4i3.1044>

Corresponding author: Indrajeet Shah

Conflict of interest: No conflict of interest.

Abstract

Contact dermatitis is a type of skin eruption. It is caused by chemical or physical substance comes in contact with skin that causes allergic reaction. Contact dermatitis can be caused by different compound in home or work. It is chronic or continuous, non-contagious in nature. Here, a 18 year's old girl presented with a popular eruption over flexor aspect of wrist joint and over both ear lobes over last 3 to 4 years. It was a diagnosed case of contact dermatitis. She was successfully treated by individualized Homoeopathic treatment with single medicine *Calcarea Carb* over 4 to 5 months. She initially did not show stable improvement on homoeopathic medicine selected on the basis of symptoms. On changing the medicine considering mental symptoms and physical general, she gradually showed good improvement and reached remission by 3 months. Remission maintained without any recurrence over the next 2 years. It shows positive role of Homoeopathic treatment in contact dermatitis in a young woman.

Keywords: Homoeopathy, Dermatitis, Contact, Treatment.

Introduction

The terms 'eczema' and 'dermatitis' are synonymous. Eczema can be acute or chronic and there are several causes. Acutely, epidermal oedema (spongiosis) and intra-epidermal vesiculation (producing multilocular blisters) predominate, whereas with chronicity there is more epidermal thickening (acanthosis). Vasodilatation and T-cell lymphocytic infiltration of the upper dermis also occur.¹

Contact dermatitis is a common inflammatory skin condition characterized by itchy, dry skin or eruption, reddened skin that occur when contact with foreign substance. there are two type of contact dermatitis: irritant and allergic.

Irritant contact dermatitis is caused by the non-immune-modulated irritation of the skin by a substance, leading to skin changes. Allergic contact dermatitis is a delayed hypersensitivity reaction in which a foreign substance comes into contact with the skin; skin changes occur after re-exposure to the substance. The most common substances that cause contact dermatitis include poison ivy, nickel, and fragrances. Contact dermatitis usually leads to erythema and scaling with visible borders. Itching and discomfort may also occur. Acute cases may involve a dramatic flare with erythema, vesicles, and bullae; chronic cases may involve lichen with cracks and fissures. When a possible causative substance is known, the first step in confirming the diagnosis is determining whether the problem resolves with avoidance of the substance. Localized acute allergic contact dermatitis lesions are

successfully treated with mid- or high-potency topical steroids, such as triamcinolone 0.1% or clobetasol 0.05%. If allergic contact dermatitis involves an extensive area of skin (greater than 20 percent), systemic steroid therapy is often required and offers relief within 12 to 24 hours. In patients with severe rhus dermatitis, oral prednisone should be tapered over two to three weeks because rapid discontinuation of steroids can cause rebound dermatitis. If treatment fails and the diagnosis or specific allergen remains unknown, patch testing should be performed.²

Dr. Wadia in his book quotes that – Dr. Gardinar in his book "Hand Book of Skin Disease" states, "a skin condition is a reflection of the individual as a whole & that in most causes internal treatment is, therefore necessary & in some causes, it is the only method of treatment".⁶

Patient Information

An 18 year old Hindu unmarried college girl from middle socioeconomic status family presented at MNR Homoeopathic Medical College and Hospital, Sangareddy, Telangana in December 2017 with a progressively increasing vesicopapular eruptions over Left flexor aspect of wrist joint and both ear lobes since 3 to 4 years. She had nil contributory ongoing medical present. Her menstrual cycle was regular (28–30 days), moderate flow, and lasting for 2–3 days. There was history of severe pain in the first 2 days of menstruation (dysmenorrhea), ameliorating on rest. Her childhood history was uneventful. She is pursuing B. Com studies. Her father has a grocery shop of middle socioeconomic status. In her family, mother having history of allergic rhinitis and was operated for the same complaint. Subsequently, she was maintained on

Homoeopathy for more than 5 years, and now she feeling better. She was having one younger brother keeping good health. She was also suffering from anxiety and irritability for last few months. Before coming to the MNR Homoeopathic Medical College and Hospital OPD, she was treated with local herbal medication and also taken conventional treatment form local doctor for 1 to 1 ½ years, at that time she got little relief for 10–15 days and after that, eczema became more vigorous than earlier and she decided to take homoeopathic treatment.

There was severe itching followed by eczematous eruptions predominantly on the flexor aspect of wrist joint [Figure 1] aggravates by touching of metal watch and some minor lesions on both pinna and both forearm for last 3-4 years aggravated by wearing imitation jewelries. She was unable to wear imitation jewelries or even silver ornaments. She was unable to attain any function due to contact dermatitis caused by wearing of ornaments.

After scratching, the affected parts got excoriated and ooze thin, sticky, glutinous, discharges. There was aggravation at night. During this same period, she used to worried about her future, and weep when alone. She used to feel tired and unable to concentrate in professional work and forgetful and hesitant to take any decision. Her sleep was disturbed with restlessness and thoughts. She had constipation with dry, hard stool.

There was a past history of similar skin eruptions with less itching during her early college days and taken some herbal medication got relived.

The patient had short stature, wheatish complexion, and rough skin. Her face was having anxiety and nervousness.

On examination of the skin, there were reddish brown patches with exudation, crusting, and intermittent papular over wide areas on the flexor and medial aspects of the wrist joint and minor rashes on lateral side of both the pinna which was aggravated by wearing imitation jewelries.

Other systemic examinations were normal.

Provisional diagnosis of contact dermatitis was made based on itching, characteristic morphology, and distribution of eruptions, past history of similar rashes; all the complaints are aggravated by wearing of imitation jewelries or wearing of metal watch.

Homoeopathic Generalities

Mental

The mental generalities were irritability, anxious and tensive, sad, weeping disposition, fear of alone and cannot concentrate on anything properly.

Physical

The physical generalities were thermal reaction chilly (cannot prefer winter), desire not significant and stool-constipated, difficult to pass stool (once daily but hard, dry, not clear). Urine: normal, perspiration: normal but offensive, no staining, sleep: disturbed, delayed initiation with different thoughts and restlessness.






Miasmatic Analysis

Miasmatic analysis of all the presenting symptoms were processed with the help of comparison of the chronic miasms, which shows the mixed miasmatic with predominance of psora.⁷

Rubrics for repertorization as follows:

- Sadness
- Confusion of mind
- Perspiration: Odor: Offensive
- Eruption: Eczema
- Eruption: Discharging, scratching after
- Eruption: Discharging- glutinous
- Constipation: Difficult stool.

Repertorization was done using Kent's repertory in Homopath classic M.D. software (Version 8.0) (Dr. Jawahar J Shah, Mind Technologies Pvt. Ltd, Mumbai, India, 2002).⁸

Remedy Name	Graph	Sulph	Lyc	Calc	Rhu
Totality	28	25	24	23	23
Symptoms Covered	7	7	6	7	6
Kingdom					
[Complete] [Mind]Sadness: (930)	4	4	4	4	4
[Complete] [Mind]Confusion of mind: (690)	4	4	4	4	4
[Complete] [Skin]Eruptions:Eczema: (409)	4	4	4	4	4
[Complete] [Skin]Eruptions:Discharging, moist:Glutinous: (13)	4	3		3	
[Complete] [Skin]Eruptions:Discharging, moist:Scratching, after: ...	4	2	4	1	4
[Complete] [Rectum]Constipation: (853)	4	4	4	4	4
[Complete] [Perspiration]Offensive: (215)	4	4	4	3	3

Treatment and Follow-up

After repertorial totality, considering the symptoms and with the consultation of Materia Medica, Graphites was selected as the first prescription. After prescribing Graphites with higher subsequent potencies (30, 200, 1M), the skin symptoms improved for a while, but did not stabilize with no improvement for 4 months. On further relapse of skin symptoms and there was a need for a fresh case taking to achieve a new similimum for the expectation of complete cure.

She was re-interrogated and re-analyzed for the characteristic symptoms, i.e., weeping disposition, fear of darkness, fear of alone, chilly patient, thirstless and

discharging from eczema after scratching, and constipation with difficult to pass stool, perspiration offensive were taken into consideration for repertorization. The case was repertorized using Complete repertory in Homopath classic M.D. version 8.0 and Calcaera Carb was selected.

Calcarea Carb was prescribed with increasing potencies (200, 1M) in subsequent follow-Up followed by placebo according to the response. On this treatment, the skin symptoms showed progressive improvement and complete remission was achieved after 4-5 months. The patient continued the follow-up for the next 1 year with no recurrence. Current update over telecommunication, showed completely recovered state [Figure 2].

Remedy Name	Lyc	Sulph	Calc	Ars	Sep
Totality	35	32	31	31	31
Symptoms Covered	9	9	10	9	9
Kingdom					
[Complete] [Mind]Sadness: (930)	4	4	4	4	4
[Complete] [Skin]Eruptions:Eczema: (409)	4	4	4	4	4
[Complete] [Skin]Eruptions:Discharging, moist:Glutinous: (13)		3	3		
[Complete] [Skin]Eruptions:Discharging, moist:Scratching, after: ...	4	2	1	1	3
[Complete] [Rectum]Constipation: (853)	4	4	4	4	4
[Complete] [Perspiration]Offensive: (215)	4	4	3	3	4
[Complete] [Mind]Weeping, tearful mood: (586)	4	4	4	4	4
[Complete] [Mind]Fear:Dark, of: (106)	3	3	3	3	1
[Complete] [Mind]Fear:Alone, being: (146)	4		3	4	3
[Complete] [Stomach]Thirstlessness: (356)	4	4	2	4	4

Table 1:

Date	Symptoms	Medicine
20 Dec 17	Baseline Presentation Figure 1.	Graphitis 30 2pills X OD X 3 days Placebo 30 2pills X BD X 7 days
27 Dec 17	No new symptoms, skin symptoms were same.	Graphitis 30 2pills X OD X 3 days Placebo 30 2pills X BD X 7 days
3 Jan 18	Itching and discharge decreased	Placebo 30 2pills X BD X 7 days
15 Jan 18	No further improvement, anxiety, stool hard, no any change	Placebo 30 2pills X BD X 7 days
29 Jan 18	Itching and discharge as earlier, no further improvement.	Graphitis 200 2pills X OD X 3 days Placebo 30 2pills X BD X 7 days
5 Feb 18	Itching and discharge as earlier, anxiety	Graphitis 1M 2pills X OD X 3 days Placebo 30 2pills X BD X 7 days
5 March 18	Mild improvement in itching and discharge	Placebo 30 2pills X BD X 7 days
20 March 18	Itching and discharge as earlier, no further improvement.	Placebo 30 2pills X BD X 7 days
3 April 18	Itching and discharge again worsened with more exudation and more crusting	Cal Carb 200 2pills X OD X 3 days Placebo 30 2pills X BD X 7 days
17 April 18	Eczema - discharge less, itching less, anxiety decreased	Placebo 30 2pills X BD X 7 days
1 May 18	Slight improvement, eczema showed drying more, sleep improved, stool regular and soft.	Placebo 30 2pills X BD X 7 days
28 May 18	No further improvement in skin lesion, anxiety, loss of appetite	Cal Carb 200 2pills X OD X 3 days Placebo 30 2pills X BD X 7 days
11 June 18	Improvement in skin lesion, appetite improved, stool normal.	Placebo 30 2pills X BD X 7 days
26 June 18	Improvement stand still, as last fallow up, anxiety,k loss of appetite	Placebo 30 2pills X BD X 7 days
9 July 18	No any change in skin lesion, stool hard and unsatisfactory	Cal Carb 200 2pills X OD X 3 days Placebo 30 2pills X BD X 7 days
30 July 18	Itching increased, discharged increased, stool unsatisfactory	Cal Carb 1M 2pills X OD X 3 days Placebo 30 2pills X BD X 7 days
13 Aug 18	No itching, no discharge, but blackish with hyper-pigmentation	Placebo 30 2pills X BD X 7 days
10 Sept 18	No any complaints, no anxiety, appetite normal, stool normal	Placebo 30 2pills X BD X 7 days
17 Dec 18	No any skin lesion	Placebo 30 2pills X BD X 7 days
11 Feb 19	-No skin lesion -Patient wears imitation jewelry -She attain function -No anxiety, appetite normal, stool normal	Placebo 30 2pills X BD X 7 days
19 Aug 19	No recurrence	Placebo 30 2pills X BD X 7 days

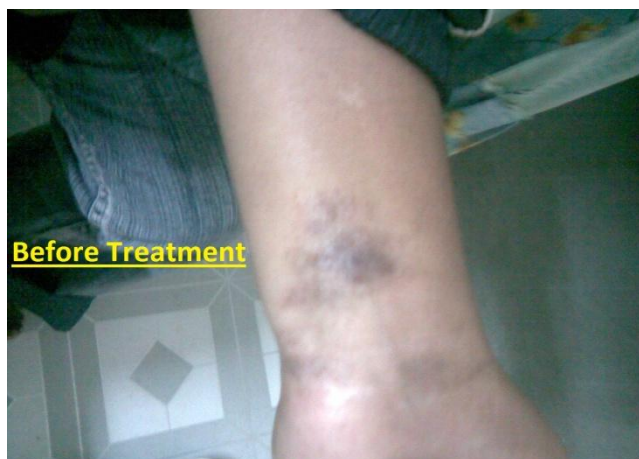

Figure 1:

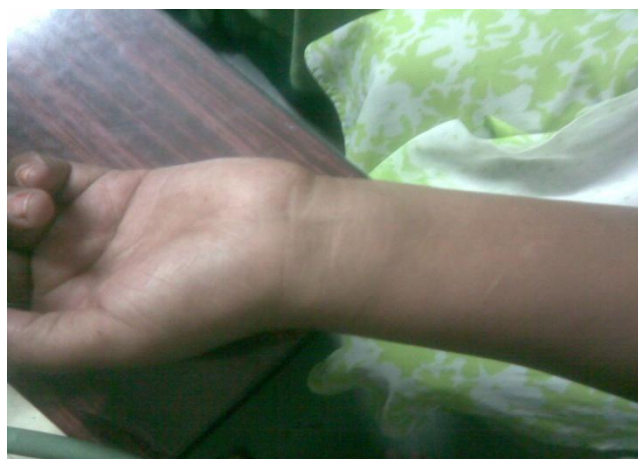

figure 2:

Discussion

Graphites was primarily selected as first prescription on the basis of totality of symptom (on considering particular and physical general) in 30 potency on 20 Dec 2017. Graphites with increasing potencies (30, 200, 1M,) were prescribed following homoeopathic philosophy for 3 months.

Discharges of eczema and itching were reduced and gradually eczema became dry, looking better for a time being in early 3 to 4 months and relapse the skin symptoms whenever she wears imitation jewelry and again eczema worsened, itching and discharges increased with more exudation and crusting.

For selection of a new individualized medicine, a fresh case taking was done to arrive the totality of symptoms. On re-case taking, more emphases was given on changed physical general and mental symptoms like “weeping disposition, fear of darkness, fear of alone being and thirstless” were left out in the earlier repertorization, although those symptoms were present in the patient since beginning. After evaluating the symptoms, giving the more priority to mental generals, physical general and lastly particular skin symptoms allows a new similimum Calcarea Carb.

Calcarea Carb 200 (Cal carb) was prescribed on 03/04/18 and follow-up was continuing for 1 ½ years which is given in detail in Table 1. Treatment with Calcarea Carb with increasing potencies (200, 1M) was continued from 03/04/18 for the next 4-5 months. Initial improvement on dermatological symptoms was found with treatment by Cal Carb 200 and then improvement was stopped and the condition became standstill. The repetition and increasing the potencies were done according to the response following the homoeopathic philosophy. For the expectation of further improvement, the higher potency of same remedy (Cal Carb 1M) was prescribed on 30/07/18.

After 5 months of this treatment, stable improvement was found in skin symptoms and complete remission was achieved. The patient continued the follow-up for next 1 year with no recurrence of skin symptoms with wearing of imitations jewelry. And on subsequently follow up her menstrual cycle was regular and patient was not complaining of dysmenorrhea.

Conclusion

Cal Carb was selected on bases of totality of symptoms. Lyco and Sulp scored high i.e. 32/9, but these medicines not covered all the rubrics. Cal Carb scored 31/10, it covered all the rubrics. So Cal carb was selected as constitutional remedy for this case. Medicine, selected on the basis of totality of characteristic symptoms and through individualization which covers the patient’s miasmatic background, has the capability to cure the patient at the deeper level which leads to permanent restoration of health.

References

1. S.H. Ibbotson, R.S. Dawe, Davidson’s Principles and practice of Medicine, churchillivingstone Elsevier, Twenty-second edition 2014, page no 1283.
2. RICHARD P. USATINE, MARCELA RIOJAS, Diagnosis and Management of Contact Dermatitis, Am Fam Physician. 2010 Aug 1;82(3):249-255. <https://www.aafp.org/afp/2010/0801/p249.html>.
3. Sainani G.S. –“API Text Book of medicine”, Published by – Association of Physicians of India, Bombay. 5th edition reprint 1994.
4. “Harrison’s Principles of Internal Medicine – Vol 1 16th Edition McGraw Hill, Medical Publishing Devison. Pg No. 288-289. <https://www.healthline.com/health/contact-dermatitis#causes>.
5. Wadia S.R. Homeoeopathy in Skin Diseases”, B.Jain Publishers Pvt. Ltd. 1921.
7. Speight P. A Comparison of the Chronic Miasms, Psora, Pseudopsora, Syphilis, Sycosis. Reprint Edition. New Delhi: B. Jain Publishers (P) Ltd.; 1998. p. 1-86.
8. Shah J. Homopath Classic M.D Repertory. Version 8.0. Mumbai, India: Mind Technologies Pvt. Ltd.; 2010-2011.